

# Case Report

## Hemophagocytic syndrome due to pulmonary sarcoidosis<sup>\*,\*\*</sup>

Síndrome hemofagocítica devido a sarcoidose pulmonar

Thiago Prudente Bártholo, José Gustavo Pugliese, Thiago Thomaz Mafort,  
Vinicius Lemos da Silva, Cláudia Henrique da Costa, Rogério Rufino

### Abstract

Although hemophagocytic syndrome is a rare clinical condition, it is associated with high mortality and the number of cases described in the literature has progressively increased. The diagnosis of hemophagocytic syndrome is made on the basis of a finding of hemophagocytosis. Sarcoidosis is a highly prevalent disease whose course and prognosis might correlate with the initial clinical presentation and the extent of the disease. We report the case of a patient with long-standing sarcoidosis who presented with intermittent fever and fatigue. The diagnosis of hemophagocytic syndrome was made by bone marrow aspiration, and specific treatment was ineffective. This is the third case of sarcoidosis-related hemophagocytic syndrome reported in the literature and the first reported in Latin America. All three cases had unfavorable outcomes.

**Keywords:** Lymphohistiocytosis, hemophagocytic; Ferritins; Sarcoidosis, pulmonary; Macrophage activation syndrome.

### Resumo

Embora seja uma condição clínica rara, a síndrome hemofagocítica é associada com alta mortalidade e o número de casos descritos na literatura vem aumentando progressivamente. O diagnóstico de síndrome hemofagocítica depende da presença de hemofagocitose. A sarcoidose é uma doença de alta prevalência cujo curso e prognóstico podem correlacionar-se com a apresentação clínica inicial e a extensão da doença. Relatamos o caso de um paciente com sarcoidose de longa duração que apresentava febre intermitente e fadiga. O diagnóstico de síndrome hemofagocítica foi realizado por aspirado de medula óssea, e o tratamento específico foi ineficaz. Trata-se do terceiro caso de síndrome hemofagocítica relacionada a sarcoidose na literatura mundial e o primeiro na literatura latino-americana. Os três casos tiveram desfecho desfavorável.

**Descritores:** Linfohistiocitose hemofagocítica; Ferritinas; Sarcoidose pulmonar; Síndrome de ativação macrofágica.

### Introduction

Sarcoidosis is a chronic granulomatous inflammatory disease of unknown etiology and heterogeneous outcomes. On the basis of the natural history of the disease or the course of clinical treatment, the outcomes of cases can be divided into spontaneous regression (self-limited disease), progression of extensive fibrotic lesions as postgranulomatous fibrosis, or association of sarcoidosis with other hematologic diseases, such as myelodysplastic syndrome, acute myeloid leukemia, IgG4-related disease, lymphoma, hypogammaglobulinemia, Castleman's disease,

and, less frequently, solid tumors. Spontaneous regression occurs in nearly two thirds of cases, the remaining one third being the most challenging to treat and follow.<sup>(1-4)</sup>

### Case report

A 56-year-old man who had been diagnosed with sarcoidosis in 1991 on the basis of skin biopsy findings presented with pulmonary and cutaneous lesions. Since the diagnosis of sarcoidosis, the patient had been receiving daily

\* Study carried out at the Pedro Ernesto University Hospital, State University of Rio de Janeiro, Rio de Janeiro, Brazil. Correspondence to: Rogério Rufino. Avenida 28 de Setembro, 77, 2º andar, Departamento de Pneumologia, CEP 20551-030, Rio de Janeiro, RJ, Brasil.

Tel/Fax: 55 21 2868-8248. E-mail: rrufino@uerj.br

Financial support: None.

Submitted: 19 February 2012. Accepted, after review: 3 April 2012.

\*\*A versão completa em português deste artigo está disponível em [www.jornaldepneumologia.com.br](http://www.jornaldepneumologia.com.br)

doses of prednisone (10 mg/day) in order to control the activity of the disease. The patient had been well until March of 2010, when he had episodes of fever. He received emergency room treatment, the amoxicillin-clavulanate combination having been prescribed. The fever did not subside. Ten days later, the patient sought emergency room treatment again (in the same emergency room) and received levofloxacin. The fever persisted, followed by mild dyspnea, and the patient lost 5 kg in one month. Two weeks after the end of the second course of antibiotics, the patient returned for an unscheduled visit. Physical examination revealed normal respiration and stable hemodynamic parameters. However, the patient remained febrile. The dose of prednisone was increased to 40 mg/day. One month later, the symptoms persisted, and the patient returned. A

blood workup revealed leukocytosis (neutrophils, 32%). Anemia and thrombocytopenia were found. Electrolytes, creatinine, and urea were normal, and blood and urine cultures were negative (Table 1). The patient was hospitalized for further investigation. He had a medical history of diabetes and dyslipidemia but reported no allergies, blood transfusions, smoking, or alcohol consumption.

At admission, the patient was febrile (39°C) and a little anxious. He had no jaundice, rash, or lymphadenopathy. His blood pressure was 130/70 mmHg, his RR was 21 breaths/min, his SaO<sub>2</sub> was 96%, and his HR was 88 bpm. Cardiovascular examination was normal. Pulmonary examination revealed normal breath sounds. Physical examination was otherwise unremarkable. Laboratory test results at admission were similar

**Table 1** - Laboratory test results.

Variable	At admission	10 days after admission
Glucose, mg/dL	108	65
Hematocrit, %	38.5	21
Hemoglobin, g/dL	13.7	7.2
Leukocytes, mm <sup>3</sup>	6,300	41,000
Platelets, mm <sup>3</sup>	201,000	25,000
Creatinine, mg/dL	0.6	3.8
Urea, mg/dL	25	128
ALT, U/L	28	298
AST, U/L	56	65
Total protein, g/dL	7.4	4.6
Albumin, g/dL	3.7	1.8
GGT, U/L	34	536
Alkaline phosphatase, U/L	ND	7,960
LDH, U/L	234	ND
Total bilirubin, mg/dL	0.53	12.9
Direct bilirubin, mg/dL	0.23	9
Indirect bilirubin, mg/dL	0.35	3.9
PTT, s	28	ND
INR	0.7	1.3
Total cholesterol, mg/dL	242	ND
HDL, mg/dL	31	ND
LDL, mg/dL	141	ND
Triglycerides, mg/dL	202	ND
ESR, mm/h	ND	52
Calcium, mg/dL	8.8	ND
Iron, mg/dL	ND	50
Ferritin, ng/dL	ND	690.6
Sodium, mEq/L	141	144
Potassium, mEq/L	4.1	4.7

ALT: alanine aminotransferase; AST: aspartate aminotransferase; GGT: gamma-glutamyl transpeptidase; ND: not determined; LDH: lactate dehydrogenase; PTT: partial thromboplastin time; and INR: international normalized ratio.

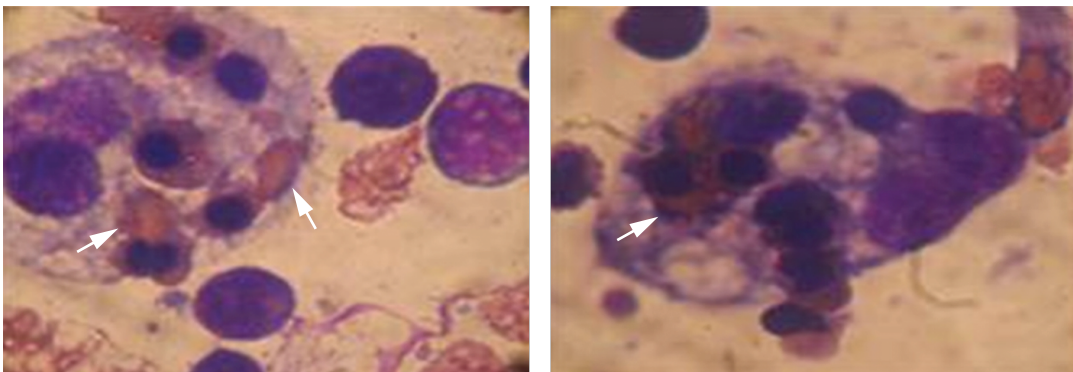
to those previously reported. Chest X-ray was normal.

At admission, ceftriaxone, amikacin, and vancomycin were prescribed. New cultures of blood and urine specimens were negative. On postadmission day 10, the patient presented with jaundice and flapping tremor. There were no remarkable changes in the level of consciousness or in the hemodynamic parameters. Laboratory test results were considerably worse (Table 1). A HRCT scan of the chest revealed no abnormalities, and a transthoracic echocardiogram was unremarkable. Abdominal ultrasound and CT scan were normal. Serology for HIV, Epstein-Barr virus, and hepatitis was negative, as were rheumatologic markers (antinuclear antibodies, rheumatoid factor, and antineutrophil cytoplasmic antibody). Blood smear microscopy revealed leukocytosis (41,100 cells/mm<sup>3</sup>), thrombocytopenia (25,000 platelets/mm<sup>3</sup>), and anemia (hemoglobin, 7.2 g/dL; hematocrit, 21%; ferritin, 690.6 ng/dL; and serum iron, 50 mg/dL). On postadmission day 20, the patient presented with decreased urine output and developed liver failure (with hepatomegaly and splenomegaly) and respiratory failure. He was started on mechanical ventilation, hemodialysis, and vasopressors. Four blood cultures were negative. Serology for ehrlichiosis, bartonellosis, and Q fever was negative. Ferritin determination was repeated (1,619 ng/dL). A myelogram was requested because of unexplained fever, thrombocytopenia, and elevated serum ferritin, revealing red cell phagocytosis by macrophages (Figure 1). A diagnosis of hemophagocytic syndrome (HPS) was established, and the patient was started on methylprednisolone pulse therapy in the

department of hematology, with no success. The patient died four days after the initiation of corticosteroid therapy.

## Discussion

Albeit rare, HPS is a potentially fatal condition. The diagnosis of HPS is based on a combination of clinical and biological signs, requiring histological/cytological examination for hemophagocytosis and an exhaustive etiologic investigation.<sup>(5)</sup> The disease is classified as primary or secondary HPS.<sup>(6)</sup> The two forms are clinically indistinguishable, being characterized by a sepsis-like presentation with splenomegaly, cytopenia, hyperferritinemia, bleeding disorder, and hemophagocytosis. Consequently, multiorgan failure often develops, leading to high mortality.<sup>(7)</sup> Primary HPS is hereditary, and most patients present with symptoms within two years after birth, being treated in the pediatric field.<sup>(6)</sup> The primary form of HPS has an autosomal recessive pattern of inheritance, with an incidence of approximately 1/50,000 live births.<sup>(7)</sup> Primary HPS can result from autosomal defects or be associated with immune deficiencies, such as Chediak-Higashi syndrome, X-linked lymphoproliferative syndrome, and Griscelli syndrome.<sup>(8)</sup> Five types of familial HPS have been described.<sup>(9)</sup> The prognosis is unfavorable. Secondary HPS develops during adulthood in most patients. The incidence of infection-associated HPS (particularly that of virus-associated HPS) is high, as is that of lymphoma-associated HPS.<sup>(6)</sup> Other conditions associated with secondary HPS include autoimmune diseases such as rheumatoid arthritis, Still's disease, dermatomyositis, sarcoidosis, systemic



**Figure 1** - Findings in bone marrow aspirate (H&E; magnification,  $\times 40$ ). Photomicrographs showing active macrophages with signs of hemophagocytosis, mainly engulfed erythrocytes (white arrows).

lupus erythematosus, and vasculitis. Drugs such as beta blockers and chemotherapeutic agents have also been described as causing secondary HPS.<sup>(6,7,10)</sup> Diffuse alveolar hemorrhage has been described as a manifestation of HPS.<sup>(11,12)</sup>

The syndrome is characterized by the proliferation of benign macrophages that are responsible for extensive phagocytosis of hematopoietic cells, which is due to a hyperinflammatory response that can affect the cytotoxic function of T lymphocytes and natural killer (NK) cells.<sup>(13)</sup> This inflammatory response is induced by a “cytokine storm” and is characterized by the proliferation and activation of macrophages in the reticuloendothelial system.<sup>(14,15)</sup> Normal histiocyte function includes phagocytosis, antigen presentation, and activation of the adaptive immune system through contact and cytokine signaling. Although abnormalities in the function of NK cells have been reported in patients with HPS, the number of NK cells is rarely increased. The syndrome is a reactive process resulting from prolonged and excessive activation of antigen-presenting cells (macrophages, histiocytes, and CD8<sup>+</sup> T cells). As stated by Filipovich,<sup>(16)</sup> “hemophagocytosis, which is mediated through the CD163 heme-scavenging receptor, is a hallmark of activated macrophages/histiocytes and is the characteristic finding for which the disorder was named. The majority of genetic causes identified to date affect the cytotoxic function of NK and T cells, crippling immunologic mechanisms that

mediate natural immune contraction. NK and NK T cells play a major role in maintaining a healthy threshold of immune responsiveness to noxious external stimuli and are critical to prevent and control autoimmune conditions and severe reactions to viral infections.”

Diagnostic criteria for HPS, developed by the Histiocyte Society, are described in Chart 1.<sup>(17)</sup> Hemophagocytosis can be established not only in bone marrow but also in lymphoid tissues such as the liver, spleen, and lymph nodes. Histological identification of hemophagocytosis is considered the gold standard for the diagnosis of HPS; however, in up to 20% of patients, histological examination of the first bone marrow biopsy specimen does not reveal hemophagocytosis. Because hemophagocytosis can occur at different sites during the course of the disease, repeated biopsies are sometimes required for the diagnosis of HPS.<sup>(7)</sup> Okamoto et al.<sup>(6)</sup> investigated 28 patients with secondary HPS and without a history of hyperlipidemia. Their results suggest that the triglyceride level is useful for diagnosing HPS and evaluating treatment response.<sup>(6)</sup> Ferritin levels constitute an important diagnostic parameter. However, slightly elevated ferritin levels can be found in various inflammatory diseases, being therefore nonspecific. Nevertheless, ferritin levels greater than 10,000 µg/L are found only in patients with HPS, Still’s disease, or malignant histiocytosis, as well as in those who have received multiple blood transfusions.<sup>(7)</sup> According to Knovich et al.,<sup>(18)</sup>

**Chart 1** - Diagnostic criteria for hemophagocytic syndrome.<sup>a</sup>

Clinical criteria
1. Fever
2. Splenomegaly
Biochemical criteria
3. Cytopenia (affecting at least 2 of 3 lineages in the peripheral blood)
3a. Hemoglobin < 90 g/L
3b. Platelets < 100 × 10 <sup>9</sup> cells/L
3c. Neutrophils < 1.0 × 10 <sup>9</sup> cells/L
4. Hypertriglyceridemia or hypofibrinogenemia
4a. Fasting triglycerides > 265 mg/dL
4b. Fibrinogen ≤ 1.5 g/L
5. Ferritin ≥ 500 µg/L
6. Low or absent natural killer cell activity (in accordance with the criteria of a local referral laboratory)
7. Soluble CD25 ≥ 2,400 U/ml
Histopathological criteria
8. Hemophagocytosis in bone marrow, spleen, or lymph nodes (no evidence of malignancy)

<sup>a</sup>The diagnosis is dependent on 5 of the 8 criteria being met. Adapted from Henter et al.<sup>(17)</sup>

“in a prospective study of adult HPS patients, the percentage of glycosylated ferritin was lower in patients with HPS, suggesting that low glycosylated ferritin could be a marker of severe HPS. The elevated ferritin is hypothesized to be due to passive release from cell damage in the liver and spleen, increased secretion by macrophages or hepatocytes, or decreased clearance due to lower glycosylation or down regulation of ferritin receptors.” Without intensive treatment, severe HPS is fatal. In adult patients, early intensive treatment can increase the chances of survival.<sup>(7)</sup>

Cases of HPS secondary to sarcoidosis are very rare. Dhote et al. studied 26 patients with secondary HPS, one of whom had pulmonary sarcoidosis.<sup>(19)</sup> The authors of another study reported a case of miliary tuberculosis complicated by HPS in a patient who had been diagnosed with sarcoidosis.<sup>(20)</sup> In those two cases (sarcoidosis and HPS), the patients died, having presented with fever, thrombocytopenia, and elevated triglyceride levels.

In the present case, the patient developed a sepsis-like syndrome after a period of two months with fever, mild dyspnea, and weight loss. After a thorough investigation, we found hemophagocytic cells in bone marrow aspirate. Bone marrow aspiration is a common and safe hematologic procedure that should be performed in patients with thrombocytopenia or leukopenia of unknown cause, as was the case in our patient. In accordance with the literature, our patient had to be transferred to an ICU. Nevertheless, he died from multiple organ dysfunction. The patient had been diagnosed with sarcoidosis nine years prior to the onset of HPS. However, he was dependent on corticosteroids for symptom control. It is impossible to determine whether this was a case of primary HPS in a patient with sarcoidosis or whether HPS appeared as a complication of a still active disease.

In summary, the association of HPS and sarcoidosis is very rare. A diagnosis of HPS should be considered in patients with unexplained fever and high levels of ferritin and triglycerides. In the present case, bone marrow aspiration was an essential tool for the diagnosis of HPS.

## References

1. Nagai S, Handa T, Ito Y, Ohta K, Tamaya M, Izumi T. Outcome of sarcoidosis. *Clin Chest Med*. 2008;29(3):565-74, x. PMID:18539245.

2. Statement on sarcoidosis. Joint Statement of the American Thoracic Society (ATS), the European Respiratory Society (ERS) and the World Association of Sarcoidosis and Other Granulomatous Disorders (WASOG) adopted by the ATS Board of Directors and by the ERS Executive Committee, February 1999. *Am J Respir Crit Care Med*. 1999;160(2):736-55.
3. Swigris JJ, Olson AL, Huie TJ, Fernandez-Perez ER, Solomon J, Sprunger D, et al. Sarcoidosis-related mortality in the United States from 1988 to 2007. *Am J Respir Crit Care Med*. 2011;183(11):1524-30. <http://dx.doi.org/10.1164/rccm.201010-1679OC>
4. Alexandrescu DT, Kauffman CL, Ichim TE, Riordan NH, Kabigting F, Dasanu CA. Cutaneous sarcoidosis and malignancy: An association between sarcoidosis with skin manifestations and systemic neoplasia. *Dermatol Online J*. 2011;17(1):2. PMID:21272493.
5. Ben Dhaou Hmaidi B, Derbali F, Boussema F, Ketari Jamoussi S, Baili L, Kochbati S, et al. Hemophagocytic syndrome: report of 4 cases [Article in French]. *Tunis Med*. 2011;89(1):70-5. PMID:21267834.
6. Okamoto M, Yamaguchi H, Isobe Y, Yokose N, Mizuki T, Tajika K, et al. Analysis of triglyceride value in the diagnosis and treatment response of secondary hemophagocytic syndrome. *Intern Med*. 2009;48(10):775-81. PMID:19443971. <http://dx.doi.org/10.2169/internalmedicine.48.1677>
7. Wijsman CA, Roeters van Lennep JE, von dem Borne PA, Fogteloo AJ. A diagnostic difficulty: two cases of haemophagocytic syndrome in adults. *Neth J Med*. 2009;67(1):29-31. PMID:19155545.
8. Congyang L, Xuexin H, Hao L, Chung L, Yingye M. Plasma cells increased markedly in lymph node in hemophagocytic syndrome: a case report. *Cases J*. 2009;2:9096. PMID:2803893. <http://dx.doi.org/10.1186/1757-1626-2-9096>
9. Cetica V, Pende D, Griffiths GM, Aricò M. Molecular basis of familial hemophagocytic lymphohistiocytosis. *Haematologica*. 2010;95(4):538-41. PMID:2857182. <http://dx.doi.org/10.3324/haematol.2009.019562>
10. Phillips J, Staszewski H, Garrison M. Successful treatment of secondary hemophagocytic lymphohistiocytosis in a patient with disseminated histoplasmosis. *Hematology*. 2008;13(5):282-5. <http://dx.doi.org/10.1179/102453308X316013>
11. Müller C, Mänhardt LB, Willaschek C, Schneider EM, Stuth EA, Buchhorn R. Beta-blocker therapy and hemophagocytic lymphohistiocytosis: a case report. *Cardiol Res Pract*. 2010;2010:912757. <http://dx.doi.org/10.4061/2010/912757>
12. Brandão-Neto RA, Santana AN, Danilovic DL, Bernardi Fdel C, Barbas CS, de Mendonça BB. A very rare cause of dyspnea with a unique presentation on a computed tomography scan of the chest: macrophage activation syndrome. *J Bras Pneumol*. 2008;34(2):118-20. PMID:18345456.
13. Santana AN, Kairalla RA, Carvalho CR. Remembering other causes of alveolar siderophages: macrophage activation syndrome. *Chest*. 2008;133(4):1055. PMID:18398137. <http://dx.doi.org/10.1378/chest.07-2668>
14. Melo RA, Fonseca A, Brochado M, Quinaz JM. Hemophagocytic Syndrome Associated with Hodgkin's Lymphoma First Presenting as Fever and Pancytopenia. *Case Report Med*. 2010;759651. <http://dx.doi.org/10.1155/2010/759651>

15. Szyper-Kravitz M. The hemophagocytic syndrome/macrophage activation syndrome: a final common pathway of a cytokine storm. *Isr Med Assoc J.* 2009;11(10):633-4. PMID:20077953.
16. Filipovich AH. Hemophagocytic lymphohistiocytosis (HLH) and related disorders. *Hematology Am Soc Hematol Educ Program.* 2009:127-31. PMID:20008190.
17. Henter JI, Horne A, Aricó M, Egeler RM, Filipovich AH, Imashuku S, et al. HLH-2004: Diagnostic and therapeutic guidelines for hemophagocytic lymphohistiocytosis. *Pediatr Blood Cancer.* 2007;48(2):124-31. PMID:16937360.
18. Knovich MA, Storey JA, Coffman LG, Torti SV, Torti FM. Ferritin for the clinician. *Blood Rev.* 2009;23(3):95-104. PMID:18835072.
19. Dhote R, Simon J, Papo T, Detournay B, Sailler L, Andre MH, et al. Reactive hemophagocytic syndrome in adult systemic disease: report of twenty-six cases and literature review. *Arthritis Rheum.* 2003;49(5):633-9. PMID:14558048.
20. Lam KY, Ng WF, Chan AC. Miliary tuberculosis with splenic rupture: a fatal case with hemophagocytic syndrome and possible association with long standing sarcoidosis. *Pathology.* 1994;26(4):493-6. PMID:7892057.

## ***About the authors***

---

### ***Thiago Prudente Bártholo***

Pulmonologist. Pedro Ernesto University Hospital, State University of Rio de Janeiro, Rio de Janeiro, Brazil.

### ***José Gustavo Pugliese***

Pulmonologist. Pedro Ernesto University Hospital, State University of Rio de Janeiro, Rio de Janeiro, Brazil.

### ***Thiago Thomaz Mafort***

Pulmonologist. Pedro Ernesto University Hospital, State University of Rio de Janeiro, Rio de Janeiro, Brazil.

### ***Vinicius Lemos da Silva***

Professor of Clinical Medicine. State University of Rio de Janeiro, Rio de Janeiro, Brazil.

### ***Cláudia Henrique da Costa***

Adjunct Professor. Department of Pulmonology and Tuberculosis, State University of Rio de Janeiro, Rio de Janeiro, Brazil.

### ***Rogério Rufino***

Adjunct Professor. Department of Pulmonology and Tuberculosis, State University of Rio de Janeiro, Rio de Janeiro, Brazil.