

Case Report

18F-fluorodeoxyglucose positron emission tomography as a noninvasive method for the diagnosis of primary pulmonary artery sarcoma*

Tomografia por emissão de pósitrons com 18F fluorodesoxiglicose como exame não invasivo para o diagnóstico de sarcomas primários de artéria pulmonar

Olívia Meira Dias, Elisa Maria Siqueira Lombardi, Mauro Canzian, José Soares Júnior, Lucas de Oliveira Vieira, Mário Terra Filho

Abstract

Pulmonary artery sarcomas are rare, difficult-to-diagnose tumors that frequently mimic chronic pulmonary thromboembolism. We report the cases of two female patients with clinical signs of dyspnea and lung masses associated with pulmonary artery filling defects on chest CT angiography. We performed 18F-fluorodeoxyglucose positron emission tomography, which revealed increased radiotracer uptake in those lesions. Pulmonary artery sarcoma was subsequently confirmed by anatomopathological examination. We emphasize the importance of this type of tomography as a noninvasive method for the diagnosis of these tumors.

Keywords: Positron-emission tomography; Pulmonary artery; Pulmonary embolism; Leiomyosarcoma; Histiocytoma, malignant fibrous.

Resumo

Os sarcomas de artéria pulmonar são tumores raros e de difícil diagnóstico, simulando frequentemente o tromboembolismo pulmonar crônico. Relatamos dois casos de pacientes do sexo feminino com quadro clínico de dispneia e massas pulmonares associadas a falhas de enchimento na artéria pulmonar em angiotomografia de tórax. A tomografia por emissão de pósitrons com 18F fluorodesoxiglicose mostrou hipercaptação das respectivas lesões. O sarcoma de artéria pulmonar foi confirmado posteriormente por exame anatomopatológico. Ressaltamos a importância do uso desse tipo de tomografia como exame não invasivo no auxílio diagnóstico desses tumores.

Descritores: Tomografia por emissão de pósitrons; Artéria pulmonar; Embolia pulmonar; Leiomiiossarcoma; Histiocitoma fibroso maligno.

Introduction

Pulmonary artery sarcomas are rare tumors that are often mistaken for pulmonary artery thrombi,^(1,2) leading to underdiagnosis or even to delayed diagnosis. A recent survey of the international literature shows fewer than 200 reported cases.⁽³⁾ In recent years, even in Brazil, 18F-fluorodeoxyglucose positron emission tomography (FDG-PET) has come to

play an important role in the assessment of pleuropulmonary neoplasms.⁽⁴⁾ The objective of the present case report is to emphasize the importance of FDG-PET as a noninvasive method for the diagnostic investigation of patients whose presentation of contrast filling defects in the pulmonary artery on CT angiography is atypical for thromboembolism.

* Study carried out in the Department of Pulmonology, *Instituto do Coração* – InCor, Heart Institute – University of São Paulo School of Medicine Hospital das Clínicas, São Paulo, Brazil.

Correspondence to: Olívia Meira Dias. Rua Doutor Enéas de Carvalho Aguiar, 44, CEP 05403-900, São Paulo, SP, Brasil.

Tel. 55 11 3442-0010 or 55 11 9333-0416. E-mail: meiradias@yahoo.com.br

Financial support: None.

Submitted: 10 June 2010. Accepted, after review: 2 September 2010.

Case reports

In order to facilitate the comparison of the images of Figures 1 and 2, images A and B refer, respectively, to Cases 1 and 2.

Case 1

A 61-year-old female patient was referred to our facility because of a ten-month history of dry cough and progressive dyspnea prior to admission. In the last six months, there had been worsening of symptoms, with the onset of symmetric edema in the lower limbs, weight loss (10 kg in the last eight months), and sporadic evening fever (which was not measured). The patient had a personal history of arterial hypertension, controlled with diltiazem, amlodipine, and atenolol, and was a smoker (smoking history, 10 pack-years). She reported no history of venous thromboembolism. The patient had sought emergency care in her hometown, being submitted to chest CT angiography, the findings of which were interpreted as pulmonary thromboembolism. At that point, the patient was started on anticoagulation with warfarin, which was discontinued one month after an episode of hemoptysis with no hemodynamic repercussions.

Physical examination revealed a (grade 3/6) tricuspid murmur with regurgitation. Pulmonary auscultation was normal, but the patient was hypoxemic on room air ($SpO_2 = 88\%$). A chest X-ray showed pulmonary hilar enlargement, prominence of the main pulmonary artery, and multiple pulmonary opacities with ill-defined

borders, predominantly in the lower lung fields, especially to the right. Chest CT angiography revealed dilatation of the pulmonary arteries and irregular filling defects, predominantly in the main pulmonary artery and in the right branch.

Laboratory tests revealed no significant changes, except for increased levels of B-type natriuretic peptide and C-reactive protein. Screening for thrombophilia was negative. A second chest CT angiography performed during hospitalization revealed the same vascular changes, but accompanied by peripheral pulmonary consolidations and mosaic perfusion (Figure 1a). An echocardiogram showed estimated pulmonary artery systolic pressure of 75 mmHg (reference value < 30 mmHg).

In view of the clinical and radiological findings associated with the presence of pulmonary hypertension, pulmonary artery neoplasms were hypothesized. A FDG-PET scan revealed increased FDG uptake—standardized uptake value (SUV) of 14.8—in the areas with pulmonary artery filling defects, as well as increased metabolic activity in the peripheral right pulmonary opacity (SUV = 6.5) and in the right adrenal gland (SUV = 14.3; Figure 2a).

A biopsy of the right anterior descending branch revealed a malignant neoplasm with a solid pattern and consisting of atypical, pleomorphic cells with intense mitotic activity and nuclear anaplasia, mostly spherical, tending to be aggregated in a peculiarly “honeycomb” pattern. The immunohistochemical profile consisted of vimentin and smooth muscle alpha actin positivity, whereas antibodies to CD31,

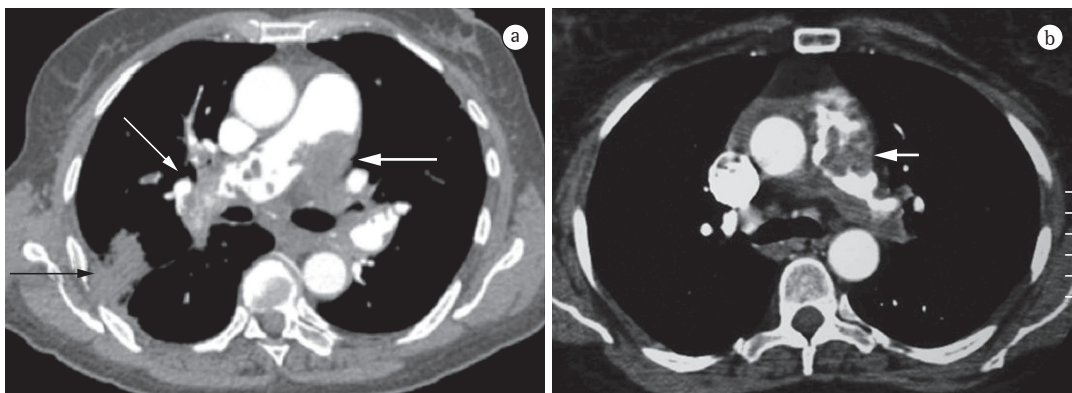


Figure 1 - In a, chest CT angiography of Case 1 revealing dilatation of the pulmonary artery and irregular filling defects, notably in the main pulmonary artery (thick white arrow) and in the right branch of the pulmonary artery (thin white arrow), as well as peripheral pulmonary consolidations (black arrow). In b, chest CT angiography of Case 2 showing irregular filling defects in the main pulmonary artery (white arrow).

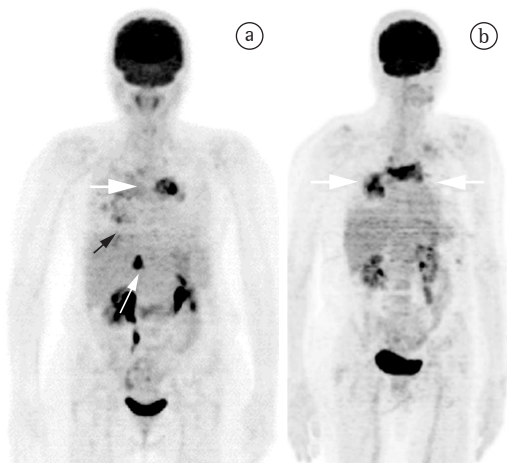


Figure 2 - In a, 18F-fluorodeoxyglucose positron emission tomography of Case 1 showing increased radiotracer uptake in the region corresponding to that of the pulmonary artery (thick white arrow). There was also increased metabolic activity in the peripheral right pulmonary opacity (black arrow) and in the right adrenal gland (thin white arrow). In b, 18F-fluorodeoxyglucose positron emission tomography of Case 2 showing increased radiotracer uptake in the regions corresponding to those of the main pulmonary artery and the descending branch of the right pulmonary artery (thick white arrows).

CD34, CD45, cytokeratin AE1/AE3, desmin, S-100 protein, and thyroid transcription factor-1 were negative, confirming the diagnosis of pleomorphic leiomyosarcoma of the pulmonary artery (Figure 3).

The patient was discharged in good clinical condition, being referred for radiation therapy and chemotherapy in her hometown.

Case 2

A 66-year-old female patient presented with a three-month history of dyspnea on exertion prior to admission, dry cough, and palpitations. The patient was a former smoker (smoking history, 10 pack-years) who had quit smoking 30 years prior, had a personal history of hypothyroidism (she was on levothyroxine) and diverticular bowel disease, and had undergone hysterectomy and appendectomy. Exercise stress testing and echocardiography, which had been performed previously, yielded normal results. The patient was referred to our facility because of a pulmonary nodule on chest X-ray.

Physical examination revealed good general health, normal respiration at rest, and an SaO₂ of 96% on room air. The cardiac auscultation revealed tricuspid systolic murmur. The patient had moderate lower limb edema, with no signs of jugular stasis.

All laboratory test findings were normal, except for increased levels of B-type natriuretic peptide. A second echocardiogram revealed mild right ventricular hypokinesia, paradoxical interventricular septal motion, mild tricuspid insufficiency, and a pulmonary artery systolic pressure of 93 mmHg.

Bronchoscopy revealed signs of mild tracheomalacia and prominence of the outer lateral wall of the basilar segment of the right lower lobe, obliterating 40% of the lumen and showing signs suggestive of mucosal infiltration. The bronchoalveolar lavage fluid was negative for microorganisms and neoplastic cells. Endobronchial biopsy of the region yielded inconclusive results.

Chest CT angiography revealed filling defects in the main pulmonary artery and its main branches, as well as in its segmental and subsegmental branches, bilaterally. It is of note that the right descending pulmonary artery had an increased diameter and contained major contrast filling defects. In addition, there were multiple, noncalcified pulmonary nodules in the caudal third of the lungs (Figure 1b).

A FDG-PET scan revealed an extensive and heterogeneous area of increased radiotracer uptake in the lower third of the right lung (SUV = 12.8), in a location corresponding to that of the solid lesion observed in the upper segment of the right lower lobe, as well as an extensive area of heterogeneous radiotracer uptake in the mediastinum, extending into the left peribronchial region, in a position corresponding to that of the pulmonary artery (SUV = 15.8; Figure 2b).

In view of the CT angiography findings and the FDG-PET findings of increased radiotracer uptake, pulmonary artery neoplasms were hypothesized.

The patient underwent open lung biopsy, and material was collected from the interior of the pulmonary arteries. The analysis of the samples revealed a malignant neoplasm consisting of atypical anaplastic pleomorphic cells and showing extensive areas of fusiform pattern and fascicular

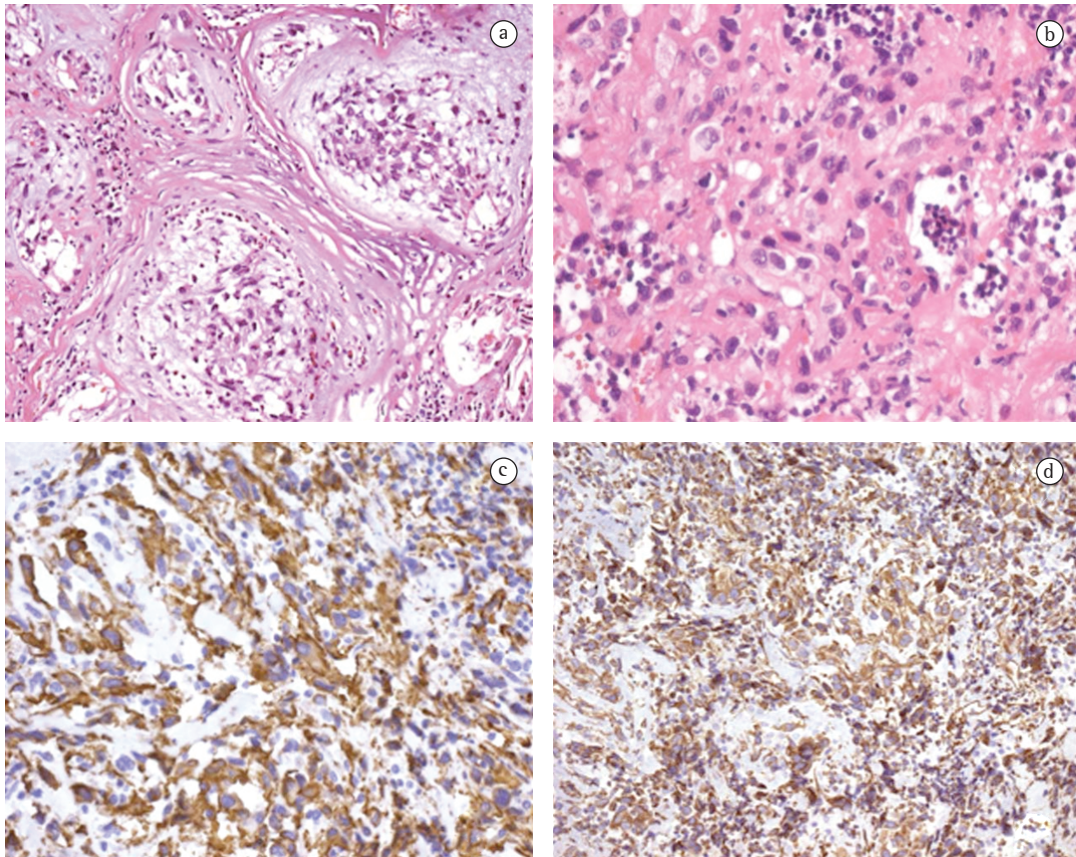


Figure 3 – Photomicrographs. In a, peculiar histopathological pattern, with pleomorphic neoplastic cells showing a honeycomb arrangement (H&E; magnification, $\times 200$). In b, neoplasm predominantly consisting of rounded cells, with moderate anaplasia (H&E; magnification, $\times 400$). In c, immunohistochemical positivity for smooth muscle alpha actin antibody (magnification, $\times 400$). In d, immunohistochemical positivity for vimentin (magnification, $\times 200$).

arrays. The immunophenotypic profile consisted of only vimentin and alpha-1 antitrypsin positivity, whereas antibodies to smooth muscle alpha actin, CD34, CD45, cytokeratin AE1/AE3, desmin, human melanoma black 45, myoglobin, and S-100 protein were negative. In view of the morphological findings, together with the immunophenotypic profile, the diagnosis was undifferentiated malignant fibrous histiocytoma or, more precisely, undifferentiated high-grade pleomorphic sarcoma, since alpha-1 antitrypsin positivity contributes little to the diagnosis in this type of case.⁽⁵⁾

On postoperative day 1, the patient had hemodynamic instability and worsening of the respiratory pattern, and she was admitted to the ICU. The patient died of cardiogenic and septic shock twenty days after admission.

Discussion

Pulmonary artery sarcomas are rare, difficult-to-diagnose tumors. These tumors can cause partial or total obstruction of the vessel, they can disseminate as hematogenous metastases, and they can also cause pulmonary hypertension, which can lead to cor pulmonale. The prognosis is poor, with survival ranging from six months to 2 years, and the combination of chemotherapy and radiation therapy is the treatment of choice.⁽³⁾

Typically, CT angiography reveals continuous filling of the vessel walls, in contrast to the irregular filling defects and vascular narrowing seen in cases of pulmonary thromboembolism. Distension of the vascular lumen, signs of invasion of adjacent structures, iodinated

contrast-enhanced images of a mass, a heterogeneous appearance because of areas of necrosis and hemorrhage, or the presence of distant metastases can also be evidence of sarcoma.⁽⁶⁾ However, those are late findings seen only in advanced phases of the disease, which negatively affects treatment and patient survival. Therefore, CT angiography alone does not suffice to rule out differential diagnoses in relation to pulmonary thromboembolism.

In the cases reported here, the clinical history, the absence of a history of venous thromboembolism or coagulation disorders that would explain hypercoagulability, the presence of systemic constitutional symptoms, such as fever and weight loss, the altered inflammatory activity, and the absence of clinical improvement after anticoagulation therapy support an alternative diagnosis.⁽⁴⁾

In a recent issue of this journal, Dornas et al.⁽²⁾ reported the case of 45-year-old male patient initially treated with a diagnosis of pulmonary hypertension secondary to chronic pulmonary thromboembolism, with no clinical response to oral anticoagulation therapy or sildenafil. In that particular case, the evidence for a diagnosis other than that of chronic pulmonary thromboembolism included identification of the mass located in the pulmonary artery (on iodinated contrast-enhanced CT) and the central location of the filling defect (on CT angiography).

Nuclear medicine examinations have been widely used in the last 30 years for the noninvasive diagnosis of pleuropulmonary diseases. Gallium-67 lung scintigraphy and determination of alveolar epithelial clearance of technetium-99m-labeled diethylene triamine penta-acetic acid were extensively used in the past in studies of inflammatory activity and infectious pulmonary processes.^(7,8) Ventilation/perfusion scintigraphy used for assessing the likelihood of pulmonary embolism and, especially, PET performed in order to assess lung neoplasms play a prominent role in current pulmonology practice.

Previous reports in the literature underscore the importance of FDG-PET, especially when

combined with CT, as a noninvasive method for the diagnosis and staging of many types of neoplasms. In the two cases reported here, there was positive radiotracer uptake in the same regions as those corresponding to the filling defects seen on CT angiography.⁽⁹⁻¹³⁾ Since PET is based on an assessment of tumor metabolic activity, it has high sensitivity and high negative predictive value for assessing lung neoplasms.^(14,15) Because of the difficulty in performing surgical biopsy in some cases, together with the risks of the procedure, especially in patients with pulmonary hypertension, we emphasize the importance of FDG-PET as a noninvasive tool for the diagnosis of suspected cases of vascular neoplasms of the lung.

References

1. Kaplinsky EJ, Favaloro RR, Pombo G, Perrone SV, Vigliano CA, Schmidt JL, et al. Primary pulmonary artery sarcoma resembling chronic thromboembolic pulmonary disease. *Eur Respir J*. 2000;16(6):1202-4.
2. Dornas AP, Campos FT, Rezende CJ, Ribeiro CA, Amaral NF, Corrêa Rde A. Intimal sarcoma of the pulmonary artery: a differential diagnosis of chronic pulmonary thromboembolism. *J Bras Pneumol*. 2009;35(8):814-8.
3. Blackmon SH, Rice DC, Correa AM, Mehran R, Putnam JB, Smythe WR, et al. Management of primary pulmonary artery sarcomas. *Ann Thorac Surg*. 2009;87(3):977-84.
4. Rocha MJ, Terra Filho M. The use of positron emission tomography in the evaluation of pleuropulmonary cancer. *J Pneumol*. 2003;29(3):161-8.
5. Fletcher CD, Unni KK, Mertens F. So-called fibrohistiocytic tumors. In: Fletcher CD, Unni KK, Mertens F, editors. *Pathology and Genetics of Tumours of Soft Tissue and Bone*. Lyon: IARC Press; 2002. p. 109-26.
6. Kim JH, Gutierrez FR, Lee EY, Semenkovich J, Bae KT, Ylagan LR. Primary leiomyosarcoma of the pulmonary artery: a diagnostic dilemma. *Clin Imaging*. 2003;27(3):206-11.
7. Terra-Filho M, Algranti E, Vargas FS, Stelmach R, Meneguetti JC. Cintilografia pulmonar com gálio⁶⁷ em trabalhadores de indústria de abrasivos. *J Pneumol*. 1997;23(1):5-10.
8. Terra-Filho M, Vargas FS, Meneguetti JC, Soares Júnior J, Cukier A, Teixeira LR, et al. Pulmonary clearance of technetium 99m diethylene triamine penta-acetic acid aerosol in patients with amiodarone pneumonitis. *Eur J Nucl Med*. 1990;17(6-8):334-7.
9. Allen S, Todd J, Copley S, Al-Nahhas A. F-18 FDG uptake in bilateral pulmonary artery leiomyosarcomata, one mimicking a pulmonary embolus. *Clin Nucl Med*. 2005;30(6):418-9.
10. Chong S, Kim TS, Kim BT, Cho EY, Kim J. Pulmonary artery sarcoma mimicking pulmonary thromboembolism: integrated FDG PET/CT. *AJR Am J Roentgenol*. 2007;188(6):1691-3.

11. Farsad M, Pernter P, Triani A, Osele L, Wiedermann CJ. Thromboembolism in pulmonary artery sarcoma. *Clin Nucl Med.* 2009;34(4):239-40.
12. Ishiguro T, Kasahara K, Matsumoto I, Waseda R, Minato H, Kimura H, et al. Primary pulmonary artery sarcoma detected with a pulmonary infarction. *Intern Med.* 2007;46(9):601-4.
13. Thurer RL, Thorsen A, Parker JA, Karp DD. FDG imaging of a pulmonary artery sarcoma. *Ann Thorac Surg.* 2000;70(4):1414-5.
14. Kostakoglu L, Agress H Jr, Goldsmith SJ. Clinical role of FDG PET in evaluation of cancer patients. *Radiographics.* 2003;23(2):315-40; quiz 533.
15. Silva CI, Marchiori E, Souza Júnior AS, Müller NL; Comissão de Imagem da Sociedade Brasileira de Pneumologia e Tisiologia. Illustrated Brazilian consensus of terms and fundamental patterns in chest CT scans. *J Bras Pneumol.* 2010;36(1):99-123.

About the authors

Olívia Meira Dias

Resident. Department of Pulmonology, *Instituto do Coração* – InCor, Heart Institute – University of São Paulo School of Medicine *Hospital das Clínicas*, São Paulo, Brazil.

Elisa Maria Siqueira Lombardi

Pulmonologist. Department of Pulmonology, *Instituto do Coração* – InCor, Heart Institute – University of São Paulo School of Medicine *Hospital das Clínicas*, São Paulo, Brazil.

Mauro Canzian

Attending Physician. Department of Anatomic Pathology, *Instituto do Coração* – InCor, Heart Institute – University of São Paulo School of Medicine *Hospital das Clínicas*, São Paulo, Brazil.

José Soares Júnior

Physician-in-Chief. Radioisotope Department, *Instituto do Coração* – InCor, Heart Institute – University of São Paulo School of Medicine *Hospital das Clínicas*, São Paulo, Brazil.

Lucas de Oliveira Vieira

Resident. Department of Nuclear Medicine, *Instituto de Radiologia* – InRad – Institute of Radiology – University of São Paulo School of Medicine, São Paulo, Brazil.

Mário Terra Filho

Associate Professor. Department of Pulmonology, *Instituto do Coração* – InCor, Heart Institute – University of São Paulo School of Medicine *Hospital das Clínicas*, São Paulo, Brazil.