

Brief Communication

Technical modification of unilateral lung transplantation in rats*

Pablo Gerardo Sánchez¹, Lucas Krieger Martins², Frederico Krieger Martins³, Ricardo Schimer⁴,
Paulo Francisco Guerreiro Cardoso⁵, Cristiano Feijó Andrade⁶

Abstract

The increasing demand in transplantation research requires efficient and less expensive animal models in order to obtain reliable results that are reproducible in larger animal models and, ultimately, applied clinically. The model of unilateral left lung transplantation in rats has proven to be a useful alternative for those purposes. We demonstrate a technical modification of this model, which consists of the isolation and ligation of the contralateral (right) pulmonary artery, allowing blood circulation exclusively in the transplanted lung. This model is feasible and reproducible. However, the short survival time restricts the assessment of the transplanted lung to a maximum period of three hours.

Keywords: Transplantation; Lung; Models, Biological; Rats.

* Study carried out at the *Santa Casa de Misericórdia de Porto Alegre, Fundação Faculdade Federal de Ciências Médicas de Porto Alegre* – FFFCMPA, Federal Foundation School of Medical Sciences of Porto Alegre; and *Universidade Federal do Rio Grande do Sul* – UFRGS, Federal University of Rio Grande do Sul – Porto Alegre (RS) Brazil.

1. PhD student in the Postgraduate Program of Respiratory Sciences at the *Universidade Federal do Rio Grande do Sul* – UFRGS, Federal University of Rio Grande do Sul – Porto Alegre (RS) Brazil.

2. Second-year Medical Resident in Heart Surgery at the *Instituto de Cardiologia da Fundação Universitária de Cardiologia* – IC-FUC, Cardiology Institute of the University Foundation for Cardiology – Porto Alegre (RS) Brazil.

3. First-year Medical Resident in General Surgery at the *Hospital Ernesto Dorneles* – HED, Ernesto Dorneles Hospital – Porto Alegre (RS) Brazil.

4. Medical Student at the *Fundação Faculdade Federal de Ciências Médicas de Porto Alegre* – FFFCMPA, Federal Foundation School of Medical Sciences of Porto Alegre – Porto Alegre (RS) Brazil.

5. PhD in Pulmonology at the *Universidade Federal do Rio Grande do Sul* – UFRGS, Federal University of Rio Grande do Sul; and at the *Fundação Faculdade Federal de Ciências Médicas de Porto Alegre* – FFFCMPA, Federal Foundation School of Medical Sciences of Porto Alegre – Porto Alegre (RS) Brazil.

6. Postdoctoral fellowship in Thoracic Surgery at the University of Toronto. *Santa Casa de Porto Alegre*, Santo Antônio Children's Hospital, Porto Alegre (RS) Brazil.

Correspondence to: Cristiano Feijó Andrade. Santa Casa de Porto Alegre, Hospital da Criança Santo Antônio, Avenida Independência, 155, 3º andar, Centro, CEP 90020-090, Porto Alegre, RS, Brasil.

Tel 55 51 3214-8674. E-mail: cristianofoa@gmail.com

Submitted: 7 September 2006. Accepted, after review: 1 December 2006.

See video related to this article at www.jornaldepneumologia.com.br

Currently, lung transplantation is the only therapeutic alternative for end-stage lung disease at a terminal phase.⁽¹⁾ The increasing number of recipients and the limited number of donors are still the principal obstacles to the development of transplantation programs.⁽¹⁾ However, transplantation is not risk-free and might present a number of complications in the early and late postoperative periods; ischemia/reperfusion, acute/chronic rejection and infections are the principal factors responsible for post-transplant mortality.^(2,3)

In order to reduce the incidence of complications and to clarify the mechanisms involved in the process of lung transplantation, it is necessary to reproduce this scenario in animal models. Various models of lung transplantation have been proposed and used in different animal species, such as rabbits, sheep, dogs, and pigs.⁽⁴⁻⁷⁾ However, due to the high costs and restrictions related to the capture and handling of medium-sized animals, their use has been limited at various research centers. Therefore, smaller animals are the natural choice. As early as 1971,⁽⁸⁾ the first results related to the use of the lung transplantation technique in rats were reported. However, the technical difficulties inherent to the procedure, especially concerning the construction of anastomoses, prevented their use on a large scale. More recently (in 1989), one group of authors introduced the technique of creating anastomoses that use cuffs.⁽⁹⁾ This significantly facilitated the execution of experiments and popularized the use of such cuffs. Since then, several modifications have been published emphasizing the excellent quality of this model for the study of the repercussions resulting from lung transplantation.⁽¹⁰⁻¹³⁾

In this article, we demonstrate the model of unilateral lung transplantation in rats, its reproducibility in our environment, and the introduction of a variation in the technique still not described in the literature, for the specific assessment of the transplanted lung.

Wistar rats weighing between 300-400 g were used. All animals were treated according to the Council for International Organizations of Medical Sciences/World Health Organization Ethical Code for Animal Experimentation.⁽¹⁴⁾ Each donor animal was anesthetized with halothane in a chamber, followed by intraperitoneal administration of ketamine (50 mg/kg) and xylazine (15 mg/kg). The animal was tracheostomized with a venous access

catheter (Abocath® #14; Abbott Laboratories, Abbott Park, IL, USA) and submitted to volume-controlled ventilation: vital capacity, 10 mL/kg; respiratory frequency, 65 rpm; and positive end-expiratory pressure, 2 cmH₂O. Subsequently, a longitudinal bilateral thoracotomy was performed along the midclavicular line, with transversal section at the level of the xiphoid process. After the intravenous administration of heparin (100 IU/100 g), the inferior vena cava and the thoracic aorta, together with the right and left auricles, were sectioned for perfusion with the preservation solution. We proceeded with the sectioning and cannulation of the pulmonary artery with a #16 venous access catheter (Figure 1a) and initiated the pulmonary perfusion with 20 mL of preservation solution (Perfadex®; Vitrolife, Göteborg, Sweden) with pressure of 30 cmH₂O, at 4 °C. Throughout the procedure, the lung was ventilated with 100% oxygen. After the perfusion was complete, the lungs were semi-inflated, the connection to the trachea was made, and the cardiopulmonary block was extracted. Subsequently, the elements of the left pulmonary hilum were isolated (Figures 1b and 1c) and the cuffs were inserted (made with 3-mm #14 or #16 venous access catheters, which present a 1.5-mm tab at their base) (Figure 1e). The #16 catheter cuff was sustained by its tab, and, with the help of two pairs of microsurgical forceps, the pulmonary artery passed through the cuff, its endothelium was inverted around the cuff circumference, and the artery was fixed with 7-0 or 8-0 monofilament (Figure 1d). The same procedure was carried out for the bronchus and the pulmonary veins using #14 cuffs. After being prepared for transplantation, the lung was stored at 4-8 °C for variable periods of time, depending on the objective of each experiment.

The recipient animal was sedated, anesthetized and orotracheally intubated. Subsequently, the ventilatory parameters previously described for the donor were selected, and the right or left carotid artery was cannulated with an Abocath® #24 catheter for hemodynamic monitoring. The animal, in right lateral decubitus, was submitted to left posterior lateral thoracotomy in the fifth intercostal space. After the pulmonary ligament had been freed, the left lung was exteriorized and maintained outside the thoracic cavity with a metal clip (Figure 2a). The hilar structures (artery, bronchus and vein) were isolated and clamped with a

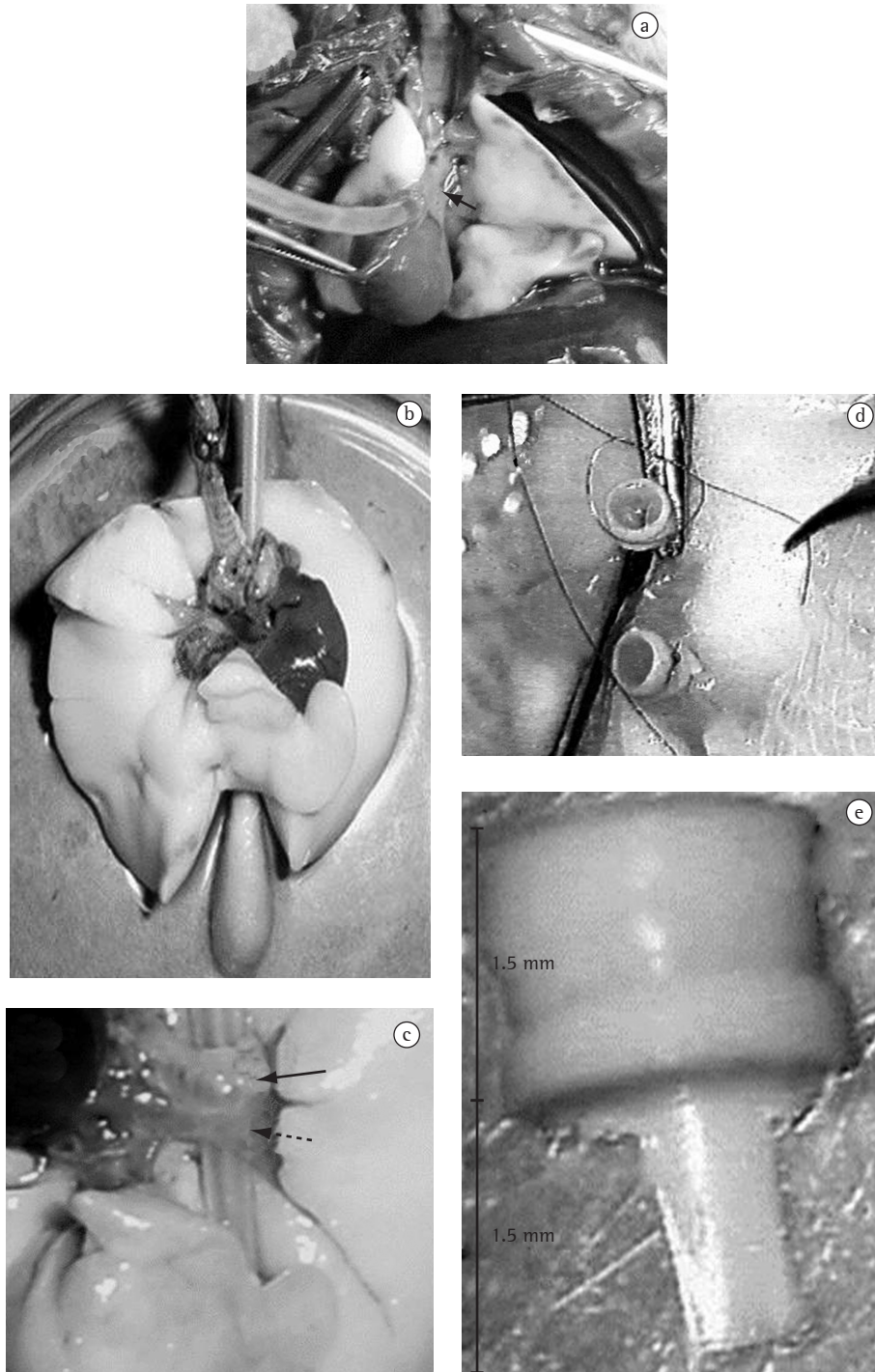


Figure 1 – Technique of experimental transplantation: a) Perfusion with catheter through the pulmonary artery trunk (arrow); b) Preparation for the dissection of the left pulmonary hilum supported by a cotton swab; c) Identified: bronchus (arrow) and pulmonary veins (dotted arrow); d) Placing of the cuffs in the respective hilar structures; and e) Cuff dimensions.

hemostatic clamp. These structures were wrapped in 7-0 or 8-0 suture to be tied off as soon as each structure was cannulated. The insertion started with the sectioning of the lateral wall of the artery in its ventral portion, slowly and carefully moving the cuff of the donor's artery into the recipient artery and using that suture previously placed around the artery to fix it (Figure 2b). The same procedure was carried out for the bronchus and the vein, respectively and in this order. Once the lung was inserted, we proceeded to the opening of the bronchial clamp, followed by the vein and the artery respectively (Figure 2c), with posterior removal of the left lung of the recipient. After the end of the transplantation, the contralateral lung was clamped. This

variant of the original model permits the exclusive evaluation of the transplanted lung (Figure 2d). This procedure is made through the same incision of the thoracotomy, retracting the transplanted lung anteriorly with a cotton swab, the posterior mediastinal face is dissected, permitting the identification of the right pulmonary hilum and facilitating its clamping. The occlusion of the right pulmonary hilum can be performed en bloc or only the ligation of the right pulmonary artery can be carried out. This variation depends exclusively on the objective of the study to be carried out. When the total occlusion of the pulmonary hilum is performed, the tidal volume of air should be reduced to 5 mL/kg to avoid hyperinflation of the transplanted lung and consequent




Figure 2 – Technique of experimental transplantation: a) Exposure of the left hilum, use of metal clip to hold the left lung in position; b) Arterial anastomosis: Opening in the back of the recipient pulmonary artery (arrow), which will allow the progression of the cuff placed on the donor artery; c) End of the anastomoses with opening of the clamps and initial phase of reperfusion; and d) Ligation of the contralateral (right) pulmonary hilum through the elevation of the left bronchus (arrow) which permits the visualization of the right bronchus through the dissection of the posterior mediastinum (dotted arrow).

lesion induced by the ventilator. In the event of the ligation of the contralateral pulmonary artery only, the tidal volume remains the same. The right pulmonary artery can also be clamped temporarily in order to obtain arterial blood gas analyses which represent the gas exchange of the transplanted lung only. After performing the transplantation and the contralateral hilar clamping, the lung is inflated and the thoracic wall is closed layer by layer. When the period of observation is over, the cardiopulmonary block is extracted, at which point it is fixed in 4% paraformaldehyde or stored at -70°C .

Between January of 2001 and December of 2004, 80 left unilateral lung transplantations were performed, with ligation of the right pulmonary artery only. The mean time of cold ischemia was 120 min. The total time for the extraction and insertion procedures rarely exceeded 60 min. The maximal survival after the closing of the thorax was 160 ± 23 min. These animals were used in different projects. Therefore, we will not present specific results related to the experiments, but only those related to the technical description.

The model of unilateral lung transplantation in rats has been used in various research centers for the assessment of the resulting repercussions of this procedure. This model permits the reproduction of the phenomenon of ischemia and reperfusion after the organ transplantation, which is analogous to what occurs in larger animals and even in clinical situations. This phenomenon is an early and severe complication of lung transplantation,⁽¹⁶⁾ which causes nonspecific alveolar damage, pulmonary edema and hypoxemia that appear within the first 72 h after transplantation,⁽¹⁷⁾ and still constitutes a major cause of early mortality in lung transplantation.⁽²⁾ This model is useful for the study of the complications related to acute or chronic rejection, especially since the animals can be kept alive for varying periods of time. The learning curve of the procedure is still steep, since it requires that the researcher be familiarized with the anatomy of the rat, with the use of the microsurgical instruments and with the surgical microscope. Notwithstanding such difficulties, the possibility of execution by a single researcher, in addition to its low cost and the simplification of the technique with the use of the cuffs, has allowed its application in various situations with excellent results.⁽¹⁸⁻²⁰⁾ The ligation of the contralateral pulmonary artery introduced in this model was

found to potentiate the effects of the reperfusion lesion, throughout the observation period, through mechanisms of supranormal flow of blood to the transplanted lung, serving the purpose of studies in which it is necessary to exclude the native lung for physiological evaluations. Nevertheless, its inclusion increases the level of difficulty of the technique and the global mortality of the experiment. This model differs from others in which the ligation of the contralateral pulmonary artery occurs in the last 5 min of the observation period by means of a sternotomy.⁽²⁰⁾

We conclude that lung transplantation in rats is feasible, produces reliable and reproducible results, and presents itself as a useful and less expensive alternative to the transplantation models in larger animals. Furthermore, it has proven to be capable of reproducing some of the phenomena that commonly occur in the clinical practice of the transplantations, becoming a practical and viable option for research in this area. Notwithstanding the relatively short period of survival, the variant technique presented in this article proves to be useful for short-term studies whose principal aim is to determine the isolated effects that the initial phase of transplantation has on the transplanted lung.

References

1. Trulock EP, Edwards LB, Taylor DO, Boucek MM, Keck BM, Hertz MI; International Society for Heart and Lung Transplantation. Registry of the International Society for Heart and Lung Transplantation: twenty-third official adult lung and heart-lung transplantation report--2006. *J Heart Lung Transplant.* 2006;25(8):880-92.
2. King RC, Binns OA, Rodriguez F, Kanithanon RC, Daniel TM, Spotnitz WD, et al. Reperfusion injury significantly impacts clinical outcome after pulmonary transplantation. *Ann Thorac Surg.* 2000;69(6):1681-85.
3. Fiser SM, Tribble CG, Long SM, Kaza AK, Kern JA, Jones DR, et al. Ischemia-reperfusion injury after lung transplantation increases risk of late bronchiolitis obliterans syndrome. *Ann Thorac Surg.* 2002;73(4):1041-47; discussion 1047-8.
4. Yoshida S, Sekine Y, Saitoh Y, Yasufuku K, Iwata T, Fujisawa T. Surgical technique of experimental lung transplantation in rabbits. *Ann Thorac Cardiovasc Surg.* 2005;11(1):7-11.
5. Lillehei CW, Everts E, Shamberger RC. Reduced-size lung transplantation from adult to neonatal sheep. *J Pediatr Surg.* 1992;27(8):1153-56.
6. Andrade CF, Martins LK, Tonietto TA, Koefender C, Anflor LC, da Silva NB, et al. Partial liquid ventilation with perfluorodecalin following unilateral canine lung allotransplantation in non-heart-beating donors. *J Heart Lung Transplant.* 2004;23(2):242-51
7. Wierup P, Liao Q, Bolys R, Sjoberg T, Rippe B, Steen S. Lung edema formation during cold perfusion: important

- differences between rat and porcine lung. *J Heart Lung Transplant*. 2005;24(4):379-85
8. Asimacopoulos PJ, Molokhia FA, Pegg CA, Norman JC. Lung transplantation in the rat. *Transplant Proc*. 1971;3(1):583-5.
 9. Mizuta T, Kawaguchi A, Nakahara K, Kawashima Y. Simplified rat lung transplantation using a cuff technique. *J Thorac Cardiovasc Surg*. 1989;97(4):587-81.
 10. Reis A, Giaid A, Serrick C, Shennib H. Improved outcome of rat lung transplantation with modification of the nonsuture external cuff technique. *J Heart Lung Transplant*. 1995;14(2):274-79.
 11. de Perrot M, Keshavjee S, Tabata T, Liu M, Downey GP, Waddell TK. A simplified model for en bloc double lung xenotransplantation from hamster to rat. *J Heart Lung Transplant*. 2002;21(2):286-9.
 12. Santana Rodriguez N, Martin Barrasa JL, Lopez Garcia A, Rodriguez Suarez P, Ponce Gonzalez M, Freixinet Gilart J. Lung transplantation in rats: a viable experimental model. *Arch Bronconeumol*. 2004;40(10): 438-42.
 13. Mizobuchi T, Sekine Y, Yasufuku K, Fujisawa T, Wilkes DS. Comparison of surgical procedures for vascular and airway anastomoses that utilize a modified non-suture external cuff technique for experimental lung transplantation in rats. *J Heart Lung Transplant*. 2004;23(7): 889-93.
 14. Howard-Jones N. A CIOMS ethical code for animal experimentation. *WHO Chron* 1985;39(2):51-6.
 15. Torres RL. Impacto do estresse oxidativo em diferentes eventos envolvidos no transplante pulmonar em ratos [Tese]. Porto Alegre: Universidade Federal do Rio Grande do Sul; 2005.
 16. Zweers N, Petersen AH, van der Hoeven JA, de Haan A, Ploeg RJ, de Leij LF, et al. Donor brain death aggravates chronic rejection after lung transplantation in rats. *Transplantation*. 2004;78(9):1251-8.
 17. de Perrot M, Liu M, Waddell TK, Keshavjee S. Ischemia-reperfusion-induced lung injury. *Am J Respir Crit Care Med*. 2003;167(4): 490-511.
 18. Parker JC, Townsley MI. Evaluation of lung injury in rats and mice. *Am J Physiol Lung Cell Mol Physiol*. 2004;286(2): L231-L46.
 19. Van Putte BP, Kesecioglu J, Hendriks JM, Persy VP, van Marck E, Van Schil PE, et al. Cellular infiltrates and injury evaluation in a rat model of warm pulmonary ischemia-reperfusion. *Crit Care*. 2005;9(1):R1-R8.
 20. Tagawa T, Kozower BD, Kanaan SA, Daddi N, Suda T, Oka T, Patterson GA. Tumor necrosis factor inhibitor gene transfer ameliorates lung graft ischemia-reperfusion injury. *J Thorac Cardiovasc Surg*. 2003;126(4):1147-54.