

# Case Reports

## Bronchial thermoplasty: report on the first endoscopic treatment for asthma in Latin America\*

Adalberto Sperb Rubin<sup>1</sup>, Paulo Francisco Guerreiro Cardoso<sup>2</sup>

### Abstract

Bronchial thermoplasty is a new bronchoscopic procedure that delivers radiofrequency energy to the airway and potentially reduces the smooth muscle-mediated bronchoconstriction. We report the case of a 48-year-old man with persistent moderate asthma submitted to bronchial thermoplasty. The treatment increased the forced expiratory volume in one second, increased the number of symptom-free days, reduced the use of relief medications, and improved the Juniper Asthma Quality of Life Scale score. In this patient, bronchial thermoplasty was well tolerated and safe. This was the first bronchial thermoplasty performed in Latin America. At 12 months after the procedure, the results were encouraging in terms of its potential benefits in patients with difficult-to-control asthma.

**Keywords:** Asthma/treatment; Respiratory function tests; Case reports [publication type].

### Introduction

Asthma patients presenting severe episodes of bronchospasm, even with appropriate treatment, are a therapeutic challenge. Many symptoms of acute asthma and cases of severe attacks are the result of excessive bronchial smooth muscle contraction, which is the principal target of inhaled bronchodilator therapy.<sup>(1)</sup> Studies have been carried out in order to investigate the possibility that a specific phenotypic alteration of the smooth musculature in asthma patients is relevant to the physiopathology of the disease.<sup>(2)</sup> Bronchial thermoplasty is a bronchoscopic procedure which, through the generation and transmission of radiofrequency waves, creating heat that reduces the muscular mass in the airways of asthma patients with the objective of reducing smooth muscle-mediated bronchoconstriction. The energy is released using a catheter (Alair System; Asthmatx: Mountain View, CA, USA) connected to a radiofrequency generator.<sup>(3)</sup>

Safety studies have demonstrated that this is a safe procedure,<sup>(3,4)</sup> without evidence of scarring or stenosis in the airway after the procedure. The histological evaluation demonstrated significant atrophy in the smooth muscle of

airways submitted to the treatment. The first prospective study in asthma patients resulted in a significant reduction of symptoms and improvement in the peak expiratory flow after 12 weeks.<sup>(5)</sup> In addition to confirming the safety of the procedure, a significant reduction of the bronchial hyper-responsiveness was observed in this study even 24 months after treatment.

Based on the results from the studies mentioned above, the first randomized study employing bronchial thermoplasty in asthma patients, the Asthma Intervention Research Trial, was proposed and subsequently carried out.<sup>(6)</sup> That was a multicenter study involving patients with moderate asthma who, despite receiving treatment appropriate to the severity of their disease (long-acting bronchodilator and inhaled corticosteroid), presented symptoms due to bronchospasm. The aim of the study was to examine the safety and efficacy of bronchial thermoplasty in asthma patients who have been submitted to the procedure by monitoring them for 12 months after the treatment.

\* Study carried out in the Pereira Filho Pavillion, Porto Alegre Santa Casa Hospital, Porto Alegre, Brazil.

1. Professor of the Postgraduate Course in Pulmonology at the *Universidade Federal do Rio Grande do Sul* – UFRGS, Federal University of Rio Grande do Sul – Porto Alegre, Brazil.

2. Associate Professor in the Department of Thoracic Surgery. *Fundação Faculdade Federal de Ciências Médicas de Porto Alegre* – FFFCMPA, Federal Foundation School of Medical Sciences of Porto Alegre – Porto Alegre, Brazil.

Correspondence to: Adalberto Sperb Rubin. Rua Anita Garibaldi, 1.226, ap. 1.403, Bairro Mont Serrat, CEP 90540-030, Porto Alegre, RS, Brasil.

Tel 55 51 3330-1813. E-mail: arubin@terra.com.br

Submitted: 10 October 2006. Accepted, after review: 14 March 2007.

The preliminary results were encouraging.<sup>(6)</sup> The authors of present study took part in the study mentioned above, in which they randomized 12 patients for treatment.

Here, we describe the case of the first asthma patient treated with bronchial thermoplasty at our facility, which was also the first case of endoscopic treatment for asthma in Latin America.

## Case report

A patient with moderate persistent asthma, under treatment with long-acting bronchodilator and inhaled corticosteroid in appropriate doses (formoterol 12 µg + budesonide 400 µg administered with powder inhaler every 12 h) was included in the study and submitted to bronchial thermoplasty.<sup>(7)</sup> The patient reported atopic asthma since childhood, with worsening of symptoms in recent years. Even under appropriate treatment for more than 36 months, the patient remained symptomatic, presenting frequent crises (3 to 4 per year) and therefore requiring courses of oral corticosteroid. This was a patient with uncontrolled asthma in the fourth step of treatment.<sup>(7)</sup>

In the first functional evaluation, the patient presented a forced expiratory volume in one second (FEV<sub>1</sub>) of 2.48 L (68%), and, on the methacholine bronchoprovocation test, the provocative concentration that induced a 20% decrease in FEV<sub>1</sub> (PC<sub>20</sub>) was 0.57 mg/mL.

The patient was submitted to bronchial thermoplasty (Figure 1) with the Alair system in three sessions (right lower lobe, left lower lobe, and upper lobes) with a three-week interval between sessions. Every treatment session was performed under general anesthesia without any complication. The procedure was well tolerated by the patient. In each of the three sessions, the patient was discharged from the recovery room with preserved pulmonary function.

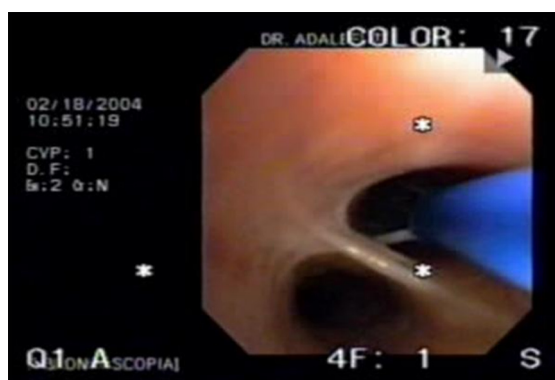
In evaluations performed 4, 6, and 12 months after the bronchial thermoplasty, the patient presented the following FEV<sub>1</sub> values: 2.67 L (73%), 2.90 L (79%), and 3.02 L (83%), respectively, demonstrating a significant improvement in the pulmonary function compared with basal values (Table 1). There was no significant change in the PC<sub>20</sub> after 12 months. In addition, comparing the final analysis (at 12 months after treatment) with the initial anal-

ysis (at four weeks before treatment), there was a 64% increase in the number of symptom-free days, a reduction in the use of relief medication (from 24.1 inhalations to 2.3 inhalations per week), and an improvement in the Juniper *Asthma Quality of Life Scale* (AQLS) score (from 2.4 to 3.7 points).<sup>(8,9)</sup> The comparison between pre-treatment and post-treatment values is shown in Table 1.

## Discussion

The aim of bronchial thermoplasty is to reduce smooth muscle thickness in the segmental and subsegmental bronchi through the application of radiofrequency energy to the airways.<sup>(3)</sup> The resulting anatomical alteration is intended to provide clinical benefits to asthma patient by reducing smooth muscle contractility in the airways,<sup>(3-5,9)</sup> potentially also reducing the number of episodes of bronchospasm and asthma exacerbation.

In most cases, asthma can be well controlled through educational and environmental measures, together with good treatment compliance. There is a portion of patients, however, who despite optimized treatment, remain symptomatic and present frequent exacerbations.<sup>(10)</sup> In such patients, even those without aggravating factors (gastroesophageal reflux, chronic sinus disease, aspergillosis, etc.), asthma can remain uncontrolled even with prolonged treatment and follow-up evaluations by a specialist.<sup>(11)</sup> This segment of patients, although representing a small proportion of the asthma patient population, is responsible for a significant portion of the medical and hospital activities involved in the treatment of



**Figure 1** – Bronchial thermoplasty in an asthma patient. Bronchoscopy image.

**Table 1** - Bronchial thermoplasty: comparative analysis of pre-operative and post-operative values.

	Baseline	At 12 months	Variation
FEV <sub>1</sub>	2.48 L (68%)	3.02 L (83%)	21%
PC <sub>20</sub>	0.120 µg	0.110 µg	-8%
AQLS score	2.4	3.7	65%
% of symptom-free days	0	64.5%	64.5%
<i>puffs/day</i>	24.1	2.3	-54%

FEV<sub>1</sub>: forced expiratory volume in one second; PC<sub>20</sub>: provocative concentration of methacholine inducing a 20% decrease in FEV<sub>1</sub>; and AQLS: (Juniper) Asthma Quality of Life Scale.<sup>(9)</sup>

the disease, accounting for more than 50% of the direct and indirect costs related to the treatment of asthma.<sup>(12-14)</sup> The high costs involved in these cases are more closely related to the loss of control of the disease, especially in terms of visits to the emergency room and hospitalizations, than to the medication administered and the regular visits to outpatient clinics.<sup>(15,16)</sup> Bronchial thermoplasty can help control asthma in patients for whom the usual measures are insufficient to stabilize the disease.

In the case presented here, this procedure was effective and well tolerated by the patient, a finding that is in agreement with those of previous studies.<sup>(5)</sup> One study carried out with patients submitted to bronchial thermoplasty showed that, at 12 months after the treatment, most of the patients said that they would repeat the procedure,<sup>(17)</sup> indicating satisfaction with the technique, as well as with its safety. Most adverse effects observed in asthma patients submitted to bronchial thermoplasty are usually seen after bronchoscopic procedures.<sup>(18-20)</sup> In this case, there were no significant complications. After each of the three sessions of treatment, the patient was monitored in the recovery room. In all three instances, no functional limitations were detected during the four-hour observation period, and the patient was discharged.

A significant functional improvement was observed in the FEV<sub>1</sub> of the patient. However, no reduction in bronchial hyperresponsiveness was observed at 12 months after the treatment, different from what has been observed in previous studies.<sup>(5)</sup> Significant clinical improvement was observed: there was a reduction in the quantity of relief medication used; the quality of life questionnaire score increased, although the increase (of 1.3 points) was less than that considered clinically significant (2 points); and of the patient reported more symptom-free days. In preliminary studies, increased peak expiratory flows

(morning and evening), as well as a reduction in the use of relief medication, have also been observed,<sup>(5)</sup> as have improvements in quality of life indexes.<sup>(6)</sup> Various consensus recommend the use of standardized quality of life questionnaires,<sup>(1,7)</sup> together with tools that measure overall clinical improvement of the asthma patient, in order to better establish the effectiveness of a new treatment. In any evaluation of the quality of a new treatment employed in asthma patients, this information is as important as the functional improvement. In this case, the clinical improvement was evinced by the greater number of symptom-free days, the decrease in the use of relief medications, and the improvement in the AQLS questionnaire score.

Bronchial thermoplasty was found to be a safe and well tolerated procedure, providing significant clinical and functional improvement during the first 12 months of follow-up after the treatment. This was the first patient treated with this technique in Latin America, and the results demonstrate that it is a promising therapeutic method, albeit still in the experimental phase, for the control and treatment of symptoms in patients with moderate or severe asthma. Further studies with larger patient samples are needed in order to confirm the long-term efficiency and utility of bronchial thermoplasty in the treatment of asthma patients.

## References

1. Global Initiative for Asthma (GINA) [Homepage on the Internet]. Bethesda: National Heart, Lung and Blood Institute. National Institutes of Health, US Department of Health and Human Services; c2000 [updated Sep 2006; cited 2006 Dec 12]. Available from: <http://www.ginasthma.org>.
2. Borger P, Tamm M, Black JL, Roth M. Asthma: is it due to an abnormal airway smooth muscle cell? *Am J Respir Crit Care Med*. 2006;174(4):367-72.
3. Danek CJ, Lombard CM, Dungworth DL, Cox PG, Miller JD, Biggs MJ, et al. Reduction in airway hyperresponsiveness to

- methacholine by the application of RF energy in dogs. *J Appl Physiol*. 2004;97(5):1946-53.
4. Miller JD, Cox G, Vincic L, Lombard CM, Loomas BE, Danek CJ. A prospective feasibility study of bronchial thermoplasty in the human airway. *Chest*. 2005;127(6):1999-2006.
  5. Cox G, Miller JD, McWilliams A, Fitzgerald JM, Lam S. Bronchial thermoplasty for asthma. *Am J Respir Crit Care Med*. 2006;173(9):965-9.
  6. Cox G, Miller J, Rubin A, Corris P, Thomson N, Niven R, et al. Asthma intervention research (AIR). Trial evaluating bronchial thermoplasty: early results [abstract]. Proceedings of the American Thoracic Society, 2006; Suppl 3: A711.
  7. Sociedade Brasileira de Pneumologia e Tisiologia. IV Diretrizes Brasileiras para o Manejo da Asma. *J Bras Pneumol*. 2006; 32 Supl 7: S447-S74.
  8. Cox PG, Miller J, Mitzner W, Leff AR. Radiofrequency ablation of airway smooth muscle for sustained treatment of asthma: preliminary investigations. *Eur Respir J*. 2004;24(4):659-63.
  9. Juniper EF, Guyatt GH, Ferrie PJ, Griffith LE. Measuring quality of life in asthma. *Am Rev Respir Dis*. 1993;147(4):832-8.
  10. Proceedings of the ATS workshop on refractory asthma: current understanding, recommendations, and unanswered questions. American Thoracic Society. *Am J Respir Crit Care Med*. 2000;162(6):2341-51.
  11. Wenzel S. Severe asthma in adults. *Am J Respir Crit Care Med*. 2005;172(2):149-60.
  12. Molfino NA, Slutsky AS. Near-fatal asthma. *Eur Respir J*. 1994;7(5):981-90.
  13. Barnes PJ, Jonsson B, Klim JB. The costs of asthma. *Eur Respir J*. 1996;9(4):636-42.
  14. Smith DH, Malone DC, Lawson KA, Okamoto LJ, Battista C, Saunders WB. A national estimate of the economic costs of asthma. *Am J Respir Crit Care Med*. 1997;156(3 Pt 1):787-93.
  15. Hoskins G, McCowan C, Neville RG, Thomas GE, Smith B, Silverman S. Risk factors and costs associated with an asthma attack. *Thorax*. 2000;55(1):19-24.
  16. ten Brinke A, Ouwerkerk ME, Zwinderman AH, Spinhoven P, Bel EH. Psychopathology in patients with severe asthma is associated with increased health care utilization. *Am J Respir Crit Care Med*. 2001;163(5):1093-6.
  17. Cox G, Thomson NG, Rubin AS, Niven RM, Corris PA, Siersted HC, et al. Asthma Control during the year after bronchial thermoplasty. *New Engl J Med*. 2007;356(13):1327-37.
  18. Busse WW, Wanner A, Adams K, Reynolds HY, Castro M, Chowdhury B, et al. Investigative bronchoprovocation and bronchoscopy in airway diseases. *Am J Respir Crit Care Med*. 2005;172(7):807-16.
  19. Tapanainen L, Lindqvist A, Halme M, Laitinen LA. Investigative bronchoscopy and endobronchial biopsy is well tolerated in hyperreactive asthma patients. *Respir Med*. 2002;96(6):466-8.
  20. Elston WJ, Whittaker AJ, Khan LN, Flood-Page P, Ramsay C, Jeffery PK, et al. Safety of research bronchoscopy, biopsy and bronchoalveolar lavage in asthma. *Eur Respir J*. 2004;24(3):375-7.