

## Anthropometric index for quantitative assessment of *pectus excavatum*\*

EDUARDO BALDASSARI REBEIS<sup>(TE SBCT)</sup>, MARCOS NAUYUKI SAMANO, CARLOS TADEU DOS SANTOS DIAS, ÂNGELO FERNANDEZ<sup>(TE SBCT)</sup>, JOSÉ RIBAS MILANEZ DE CAMPOS<sup>(TE SBCT)</sup>, FÁBIO BISCEGLI JATENE<sup>(TE SBCT)</sup>, SÉRGIO ALMEIDA DE OLIVEIRA<sup>(TE SBCT)</sup>

**Background:** *Pectus excavatum* is characterized by concave growth of costal cartilage and depression of the lower sternum. Clinical means of classifying these malformations are few and difficult to apply.

**Objective:** To devise clinical tools for quantifying the deformity and comparing preoperative and postoperative findings.

**Method:** A total of 10 *pectus excavatum* patients who underwent surgery in which the modified Robicsek technique was used by the Thoracic Surgery Group of the Hospital das Clínicas of the University of São Paulo School of Medicine, were clinically and radiologically evaluated in the preoperative and postoperative periods. Ten control individuals, presenting no thoracic or radiological abnormalities, were submitted to identical evaluations. Deformities at the sternum notch level and at the point of maximum deformity were assessed using the anthropometric index and the Haller index.

**Results:** Multivariate analysis of anthropometric index means revealed significant differences between preoperative and control values and between preoperative and postoperative values, as well as a non-significant difference between postoperative and control values. The same results were obtained when Haller index means were analyzed. A paired comparison of preoperative and postoperative means showed two distinct groups. An 86% canonical correlation was found between the anthropometric index and the Haller index.

**Conclusion:** Patients with *pectus excavatum* can be quantitatively assessed in the preoperative and postoperative periods through the use of the anthropometric index, which allows objective, comparative evaluation of the results and is easily performed.

*J Bras Pneumol* 2004; 30(6) 501-7.

Key words: Funnel Chest. Anthropometry/methods.

\*Study carried out in the Department of Cardiology and Pulmonology of the *Hospital das Clínicas da Faculdade de Medicina da Universidade de São Paulo* - Thoracic Surgery Sector.

Correspondence to: Eduardo Baldassari Rebeis. Rua Alfredo Guedes, 1949, Cj 505 - CEP 13416-016 Piracicaba, SP. Phone: 55-19-3422 4078

E-mail: eduardo.rebeis@merconet.com.br

Submitted: 29 January 2004. Accepted, after review: 13 May 2004.

## INTRODUCTION

Congenital chest malformations have been described and discussed in the literature since the 15th century<sup>(1)</sup>. *Pectus excavatum* (PEX) is the most prevalent congenital malformation of the anterior chest wall, affecting 1 out of 400 newborn children, who present aesthetic alterations with possible psychological and social consequences that interfere with the quality of life of these individuals<sup>(2)</sup>. Few studies have clinically and objectively classified the extent of these anatomical distortions in order to quantify the depression, make comparisons among groups and evaluate postoperative results<sup>(3)</sup>.

The etiology of PEX has not been well established yet. Some authors have reported that there is an abnormal growth of chondrocostal cartilage, which dislocates the sternum toward the spine<sup>(4)</sup>. In 1939, Ochsner et al. wrote the first monograph on the subject, hypothesizing that the depression of the sternum was due to the abnormal growth of cartilage<sup>(5)</sup>.

The PEX condition can be classified as symmetric or asymmetric. When it is asymmetric, the major depression is almost always to the right. The sternal notch is frequently normal or a little distorted, as are the first and second costal arches. In more severe cases, there is considerable dislocation of the heart upwards and to the left, with significant reduction in chest volume. Despite the deformity, most heart and pulmonary function tests are normal, or there is only a discrete reduction in the total lung capacity and inspiratory vital capacity<sup>(6)</sup>. In view of this, various studies have dealt with functional results in preoperative and postoperative PEX, and there is consensus that there are no significant measurable changes in cardiorespiratory function, although there is subjective improvement, especially an increase in exercise tolerance<sup>(7)</sup>.

Most authors have considered surgery the treatment of choice for severe PEX<sup>(8-10)</sup>. The ideal age for surgical correction is still debatable, and recommendations range from 4 to 12 years<sup>(11-14)</sup>. Surgical criteria for candidacy are based on aesthetic and psychological aspects of patients. Therefore, cosmetic results should be not only valued but also considered the best indication of therapeutic success.

The evaluation of patients, both during

preoperative and postoperative periods, has been either subjective<sup>(15)</sup> (clinical inspection) or objective<sup>(3,16-20)</sup> (clinical or radiological evaluation), depending on surgeon experience. There are very few studies in the literature on clinical measurements used to classify or quantify PEX.

Radiological measurements have also been adopted in order to quantify PEX. Derveaux et al.<sup>(20)</sup>, using lateral chest X-rays and evaluating the relationship between anteroposterior indices at the level of the angle of Louis and those seen at the xiphoid process level, classified patients with chest abnormalities in comparison to normal individuals. In addition, computed tomography (CT) scans were used to quantify PEX. In 1987, Haller et al.<sup>(16)</sup> created the Haller index, which is the ratio between the transverse diameter and the anteroposterior diameter, obtained from the axial tomography slice at a mediastinal window setting at the level of maximum depression. When this ratio is greater than 3.25, PEX is considered moderate or severe, and surgery is indicated in order to correct the deformity. Nakahara et al.<sup>(21)</sup> also conducted a study based on CT scans, numerically quantifying the depression, asymmetry, and flattening of the deformity.

The main objective of our study was to devise simple, easily performed clinical anthropometric tools for the appropriate quantification of PEX in outpatients. In view of this, we want not only to compare various groups of patients during preoperative and postoperative periods but also to evaluate these findings more concretely and objectively so that multicenter studies can be carried out.

## METHODS

Between December of 2001 and December of 2002, we studied 10 patients with PEX and 10 patients with no morphological thoracic alterations (controls). The patients with PEX ranged in age from 10 to 31 years (mean, 17.4 years), 5 were male, 9 were White, and 1 was Asian. Patients unfit for surgery or with diseases that would increase morbidity of the surgical procedure were excluded. The age of the patients in the control group ranged from 16 to 35 years (mean, 25.8 years), 6 were male, and all were White. Patients with diseases that might interfere with the morphology of the thoracic cage were also excluded.

The entire sample was clinically assessed at the sternal notch level at the point of maximum deformity or, in the case of control group patients, at the level of the distal third of the sternum. Patients with PEX underwent surgery and were reassessed between the 60th and the 80th postoperative day. All determinations were performed with patients in recumbent position on a flat table parallel to the floor while patients deeply inhaled.

The materials used for clinical assessment were a T-square, a ruler with a built-in level, a bolt with a limiting nut, and a standard ruler (Figure 1).

Measure A was the distance between the coronal plane tangential to the thoracic spine and the coronal plane tangential to the highest point of the costal margin, at the level of maximum deformity or at the lower third of the sternum. Measure A' was similar, but was assessed at the sternal notch level (Figures 2 and 4). Measure B was the distance between the plane tangential to the highest point of the costal margin and the plane encompassing the lowest point of the sternum (both planes were parallel to each other) at the level of maximum deformity or at the lower third of the sternum. Measure B' was similar, but was assessed at the sternal notch level (Figures 3 and 4). We defined the anthropometric index for PEX as measure B divided by measure A (Figure 4).

All patients underwent surgery in accordance with the Robicsek<sup>(22)</sup> technique, modified by the Thoracic Surgery Group of the *Hospital das Clínicas* of the *Faculdade de Medicina da Universidade de São Paulo* (University of São Paulo School of Medicine), through a longitudinal presternal incision in males and a submammary incision in females. According to the technique, resection of costal cartilage is subsequently carried out without involving the perichondrium, followed by transverse wedge osteotomy through the anterior table of the sternum at the sternal notch level and its distal third, fixing the corrected sternum at the level of the wedge with steel wire, and suture of the intercostal muscles and perichondrium under the sternum with the interposition of a polypropylene (Marlex) mesh tape, and, when there is too much tension to join the pectoral and the straight abdominal muscles, interposition of the same mesh tape. To complete the technique, the space under




Figure 1 – Material used for clinical measurements

the muscular plane is drained with continuous suction. In order to control pain, 8 patients (80%) received analgesics through a peridural catheter upon request. The other 2 patients (20%) received nonsteroidal anti-inflammatory drugs and opioid analgesics.

In addition, all patients were evaluated tomographically in the slices at mediastinal window settings at the level of the sternal notch and at the point of maximum deformity or at the distal third of the sternum, in accordance with the technique described by Haller<sup>(16)</sup>. The Haller index is defined as the internal latero-lateral distance divided by the internal anteroposterior distance at the point of maximum deformity (A/C). This index was also calculated at the sternal notch level (A'/C') in keeping with the protocol of the present study. In the interest of clarity, the clinical measurement scheme was coordinated with the design of the tomographic measurements (Figure 4).

The statistical study adopted was the following: Univariate analysis – Duncan's test; multivariate analysis and canonical correlation test; paired analysis of preoperative and postoperative means of the groups since we were dealing with the same individuals in different situations (Student's *t*-test for univariate analysis and Hotelling test for multivariate analysis). Statistical significance was set at  $p < 0.05$ . We used the statistical software program SAS 8.02. The Research Ethics Committee of the University of São Paulo School of Medicine approved the study protocol (Protocol 658/01).

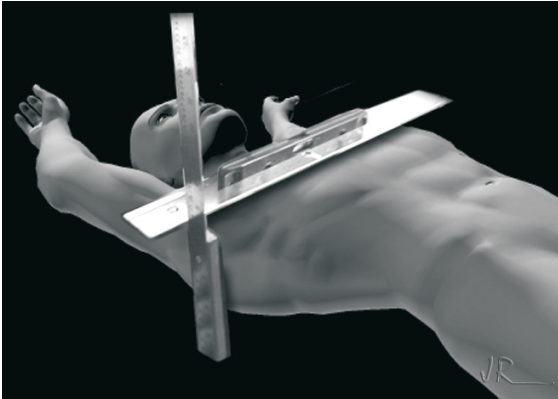


Figure 2 – Measurement A

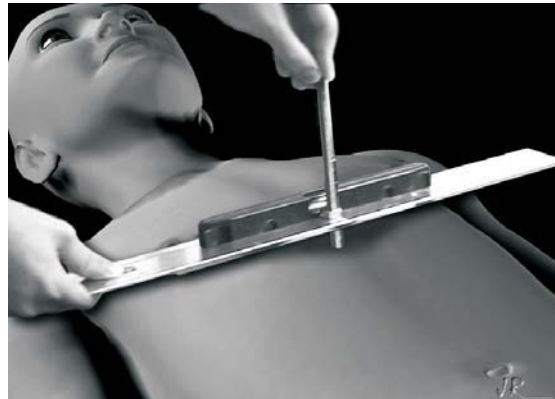

Figure 3 – Measurement B

## RESULTS

In our sample, the mortality rate was zero among the patients who underwent surgery. As for morbidity, we identified 1 case of infection with rotavirus, 1 case of small pneumothorax (less than 10%), 1 case of partial skin dehiscence and subcutaneous cellular tissue, 2 cases of minor skin dehiscence, 2 cases of occipital seroma, and 1 case of partial pulmonary atelectasis. Suction drains and peridural catheters were removed between the 4th and 7th postoperative days (mean, 5.62 days) and between the 1st postoperative day and the 7th postoperative day (mean, 3.57 days), respectively. All patients who underwent surgery were discharged between the 5th and the 8th postoperative days (mean, 6.25 days).

Charts 1 and 2 show the univariate analysis used to compare means and standard deviations of the baseline anthropometric index data for PEX at the sternal notch level and at the point of maximum deformity or of the lower third of the sternum. At both levels, statistically significant differences were found between the preoperative and postoperative means and between the preoperative and control means, whereas the difference between postoperative and control means was less than significant. A paired comparison between preoperative and postoperative means showed two distinct groups when measurements taken at both levels (sternal notch and maximum deformity) were taken into consideration.

Since the statistical correlation between  $B'/A'$

and  $B/A$  variables was high, the multivariate analysis of the anthropometric index means (at the sternal notch and maximum deformity levels or at the level of the distal third of the sternum) was justified. This analysis revealed that the differences between preoperative and postoperative means and between postoperative and control means were significant. However, the difference between postoperative and control means was not significant. The paired comparison of preoperative and postoperative means revealed that, although they were the same individuals, they belonged to distinct groups.

In summation, based on the statistical findings for this sample, we can say that, considering the index adopted (anthropometric index), preoperative

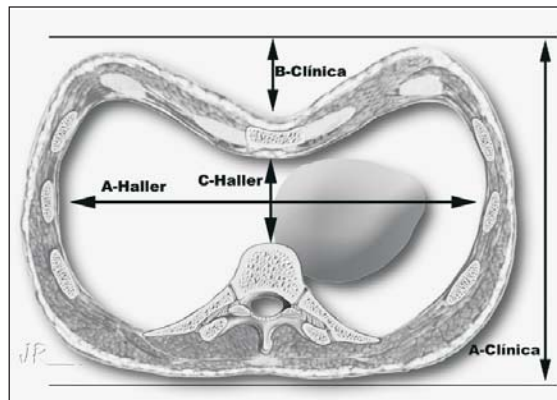
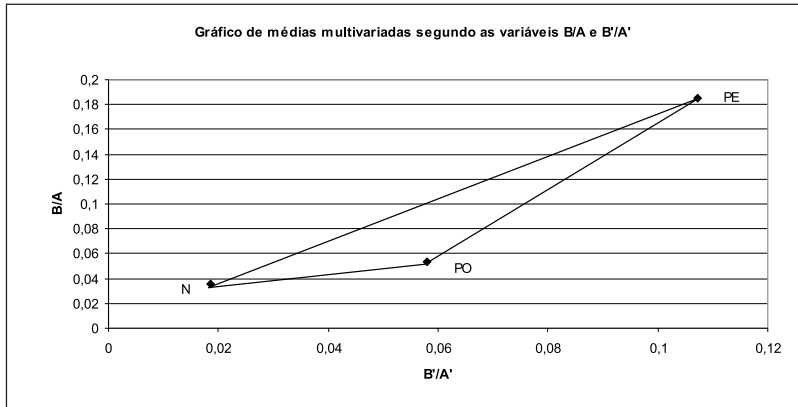
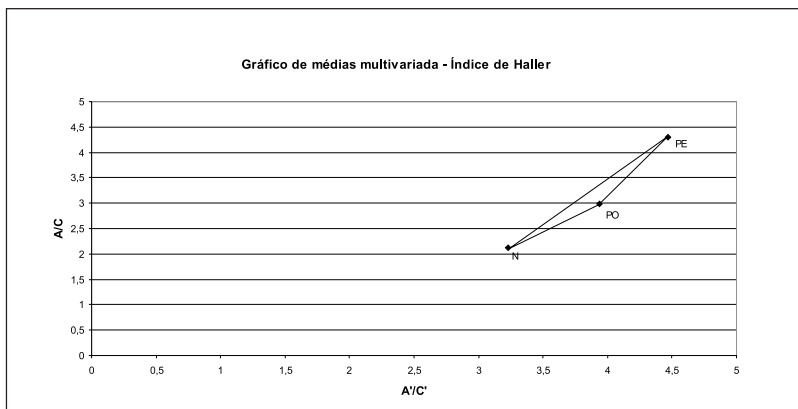


Figure 4 – AI = clinical B/clinical A and HI = Haller A/Haller C



**Figure 5** – Multivariate means at the level of the SN (A'/B') and of the MD or at the level of the lower third of the sternum (B/A) - AI  
 Tests used: WILKS' lambda; PILLA trace; HOTELLING-LAWLEY trace; Roy's maximum root



**Figure 6** – Multivariate means at the level of the ME (A'/C') and of the MD or at the level of the lower third of the sternum (A/C) - HI  
 Tests used: WILKS' lambda; PILLA trace; HOTELLING-LAWLEY trace; Roy's maximum root

and control groups were distinct. After surgical correction, the postoperative group became similar to the control group (Figure 5).

The univariate analysis for comparison of the means and standard deviations in the Haller index at the sternal notch level (Chart 3) revealed that the difference between preoperative and control means and between postoperative and control means were significant, whereas the difference between preoperative and postoperative means was not significant. These findings were confirmed in the paired comparison between preoperative and postoperative means that showed them to be statistically equal at the sternal notch level. The

univariate analysis at the level of maximum deformity or the distal third of the sternum, the multivariate analysis at both levels and the multivariate paired analysis, all related to the Haller index, are in concordance with the statistical findings of the anthropometric index (Chart 4 and Figure 6).

In other words, the statistical results obtained from anthropometric index means are congruent with those from Haller index means in the univariate analysis at the level of maximum deformity or at the lower third of the sternum, as well as in the multivariate analysis at both levels. In contrast, univariate analysis of these means at the sternal notch level is controversial since, when we used the anthropometric index, we detected a statistical difference between preoperative and postoperative means but not between postoperative and control means, which was the opposite of what occurred in relation to the Haller index results. An 86% correlation was found between clinical and tomographic measurements ( $p < 0.0001$ ).

## DISCUSSION

In the Thoracic Surgery Group of the Hospital das Clínicas of the University of São Paulo School of Medicine, we adopted the Robicsek<sup>(22)</sup> technique in 1993 and have since continued to use it because we believe that the etiology of PEX is the abnormal growth of costal cartilage, and that a rigid support in the retrosternal position is fundamental for long-term positive results. We also believe, in agreement with Humphreys and Jaretski<sup>(8)</sup>, that the best results can be seen by the 5th postoperative year and that, after that period, recurrence may be seen more frequently if the surgical technique was not appropriate.

In this study, we are proposing a simple, objective, clinical and anthropometrical method for assessing PEX that is easily performed at outpatient clinics, independently of any other types of additional tests. Other forms of clinical evaluation, previously reported<sup>(3,17-19)</sup>, demand equipment or complex, difficult-to-obtain measurements, contributing to the fact that they have been rarely performed to date. We believe that clinical procedures are extremely important tools for the diagnosis and follow-up of these patients, especially because they are based on the external chest contour, which corresponds to the real



CHART 1

Means and standard deviations of the groups (at the SN level)

PE	PO	C
0,107 ± 0,065 *	0,057 ± 0,035	0,018 ± 0,016
0,184 ± 0,073 *	0,053 ± 0,035	0,035 ± 0,027
4,478 ± 1,107 *	3,970 ± 0,657	3,237 ± 0,424
4,306 ± 1,610 *	2,987 ± 0,947	2,122 ± 0,193

\* p < 0,05 PE diferente dos demais grupos

aesthetic deformity (the main complaint of those diagnosed with PEX). We also emphasize the fact that that is the principal indicator of the need for surgical treatment of this deformity.

The tomographic measurements, which are well known, and those most frequently used, such as the Haller index<sup>(16)</sup>, reveal alterations in the osseous portion of the thoracic cage (internal alterations) that do not always correspond to the visible deformity or to the severity of the malformation detected in the clinical examination. In addition, it is notable that we also used the Haller index at the sternal notch level (A'/C'), although Haller had only described its use at the level of maximum deformity or at the level of the distal third of the sternum. This was intentional since we believe that the ideal technique for the correction of the deformity should involve the upper part of the anterior chest wall so that the final result is more complete.

Based on the results of measurements taken at the sternal notch level, the anthropometric index detected measurable changes in the patients after surgical correction, unlike what was seen with the use of Haller index. This can be explained by the fact that we did not surgically alter the rib cage at the sternal notch level and the measurements of the internal perimeter of the chest at this level must therefore be the same in the preoperative and postoperative periods. The anthropometric index, however, is based on external measurements, and the results may be attributed to the interposition of the major pectoral muscle on the sternum, causing a better filling of the anterior area of the chest and, therefore, improving the aesthetic correction of this region. The other statistical evaluations (the univariate analysis at the

level of maximum deformity or at the distal third of the sternum and the multivariate analysis) were in agreement with both the anthropometric and the Haller indices. The canonical correlation test confirmed the affinity between the two indices, reinforcing the hypothesis that the anthropometric index could substitute for Haller index in the assessment of PEX. The patients evaluated in this study are still in follow-up treatment and new results may therefore be obtained with a greater number of observations.

We conclude that calculation of the anthropometric index for PEX is feasible at outpatient clinics. Using simple, inexpensive instruments, any professional can evaluate, assess, and objectively quantify patients with this deformity. By doing so, the subjective characteristic of the clinical examination will not be the only indicator of the need for surgical treatment. In addition, when the anthropometric index is used in the preoperative and postoperative periods, it allows rapid and objective quantification of the deformity and, even more importantly, of the postoperative results. Another proposal, a bit bolder and requiring further studies with the anthropometric index, is the comparison between two or more groups of patients who have undergone surgery in various hospitals, using various techniques and performed by different surgeons, providing the opportunity to study PEX with multicenter protocols.

#### ACKNOWLEDGMENTS

We would like to thank Doctor Clarice Demétrio (Tenured Professor in the *Departamento de Ciências Exatas da Escola Superior de Agricultura Luiz de Queiroz - USP*); Dr. Lauro Kawabe (Professor responsible for scheduling surgeries at the *Instituto*

do Coração – INCOR-FMUSP); the resident medical students of the Thoracic Surgery Group of the *Hospital das Clínicas – FMUSP-SP*); Ivete Regina Vieira Torres and Marcelo da Conceição Barroso (at the Thoracic Surgery Group Outpatient Clinic of the *Hospital das Clínicas – FMUSP-SP*); Argemiro Falcetti Jr. (Medical Illustration Department of the *Instituto do Coração – INCOR-FMUSP-SP*); Dr. João Amaurício Pauli (Secretary of Health of the city of Piracicaba); and the patients that made this study possible.

## REFERENCES

- Haller JA. Operative management of chest wall deformities in children: unique contributions of southern thoracic surgeon. *Ann Thorac Surg* 1988;46:4-12.
- Lawson ML, Cash TF, Akers R, Vasser E, Burke B, Tabangin M et al. A pilot study of the impact of surgical repair on disease-specific quality of life among patients with pectus excavatum. *J Pediatr Surg* 2003;38(6):916-8.
- Haller JA, Shermeta DW, Tepas JJ, Bittner HR, Golladay ES. Correction of pectus excavatum without prostheses or splints: objective measurement of severity and management of asymmetrical deformities. *Ann Thorac Surg* 1978;26:73-9.
- Coelho MS, Batlen LC, Guzzi A, Tozzo A. Pectus excavatum / carinatum resultados do tratamento cirúrgico. *Rev Bras Ortop* 1988;23:120-4.
- Ochsner A, DeBakey M. Chone-chondrosternon: report of a case and review of the literature. *J Thorac Surg* 1939;8:469.
- Morshuis W, Folgering H, Barentsz L, Lacquet L. Pulmonary function before surgery for pectus excavatum and at long term follow-up. *Chest* 1994;105:1646-52.
- Quigley M, Haller JA Jr, Jelus KL, Loughlin GM, Marcus CL. Cardiorespiratory function before and after corrective surgery in pectus excavatum. *J. Pediatric* 1996;128:638-43.
- Humphreys GH II, Jaretzki A III. Pectus excavatum: late results with and without operation. *J. Thoracic Cardiovasc Surg* 1980;80:686-95.
- Meyer L. Zur chirurgischen behandlung der angeborenen trichterbrust. *Berliner Klinische Wochenschrift* 1911;34:1563-6.
- Ravitch MM. The operative treatment of pectus excavatum. *Ann Surg* 1949;129:429.
- Coman C. Corrective surgery of congenital chest malformations of the type pectus excavatum and pectus carinatum. *Poumon Couer* 1979;35(1):37-42
- Haller JA, Scherer LR, Turner CS. Evolving management of pectus excavatum based on a single institutional experience of 664 patients. *Ann Surg* 1989;209(5):578-82.
- Morshuis WJ, Mulder H, Wapperom G, Folgering HT, Assman M, Lacquet LK. Pectus excavatum. A clinical study with long-term postoperative follow-up. *Eur J of Cardio-thorac Surg* 1992;6:318-28.
- Haller JA Jr, Colombani PM, Humphries CT, Azizkhan RG, Loughlin GM. Chest wall constriction after too extensive and too early operations for Pectus Excavatum. *Ann Thorac Surg* 1996;61:1618-25.
- Haller A, Peters GN, Mazur D, WhiteJJ. Pectus excavatum: a 20 year surgical experience. *J Thorac Cardiovasc Surg* 1970;60:376-83
- Haller JA, Kramer SS, Lietman A. Use of CT scans in selection of patients for pectus excavatum surgery: a preliminary report. *J Pediatr Surg* 1987;22:904-6
- Albrecht A, Horst M. Long term results of operative funnel chest correction. Valuation by subjective and objective criteria including moire-topography. *Z.Orthop.*1985;123:365-73.
- Horst M, Albrecht D, Drerup B. Objective shape measurement of anterior chest wall with moire topography. Methods and deduction of non dimensional index numbers for the estimation of funnel chest. *Z Orthop.*1885;123:357-64.
- Hummer HP, Willital GH. Morphologic findings of chest deformities in children corresponding to the Willital-Hummer classification. *J Pediatr Surg* 1984;19:562-6.
- Derveux L, Clarysse I, Ivanoff I, Demedts M. Preoperative and postoperative abnormalities in chest X-ray indices and in lung function in pectus deformities. *Chest* 1989;95:850-6.
- Nakahara K, Ohno K, Miyoshi S, Maeda H, Monden Y, Kawashima Y. An Evaluation of Operative outcome in Patients with Funnel Chest Diagnosed by Means of the Computed Tomogram. *J Thorac Cardiovasc Surg* 1987;93:577-82.
- Robicsek F. Marlex mesh support for the correction of very severe and recurrent pectus excavatum. *The Annals of Thoracic Surgery* 1978;26:80-3