



A rare combination: thrombotic and non-thrombotic pulmonary embolism

Felipe Marques da Costa¹, Milena Tenorio Cerezoli¹, Augusto Kreling Medeiros¹

A 40-year-old man undergoing systemic treatment for metastatic distal rectal cancer presented with a two-week history of mild chest pain and shortness of breath. He underwent PET/CT as part of routine tumor assessment.

CT revealed multiple lesions consistent with metastasis and filling defects in bilateral pulmonary arteries. Fused PET/CT images revealed segments of filling defects with absolutely no FDG uptake, in contrast to others with high FDG avidity (Figure 1). This is in line with current knowledge in the literature that suggests that venous thromboemboli do not show FDG hypermetabolism. Conversely, tumor thrombi usually exhibit high FDG uptake.^(1,2) Based on that, FDG-PET/CT can be a useful diagnostic imaging tool.

A diagnosis of combined thrombotic and non-thrombotic pulmonary embolism was made. The patient received anticoagulation therapy and a new line of systemic oncologic treatment.

Venous thromboembolism (VTE) is the third most frequent acute cardiovascular syndrome⁽³⁾ and occurs in up to 10% of cancer patients.⁽⁴⁾ Pulmonary intravascular tumor emboli are seen in about 25% of autopsies of patients with solid malignancies, although the diagnosis is rarely made before death. Because tumor embolism and VTE are difficult to distinguish, the treatment should target the underlying malignant disease and VTE at the same time.⁽⁵⁾

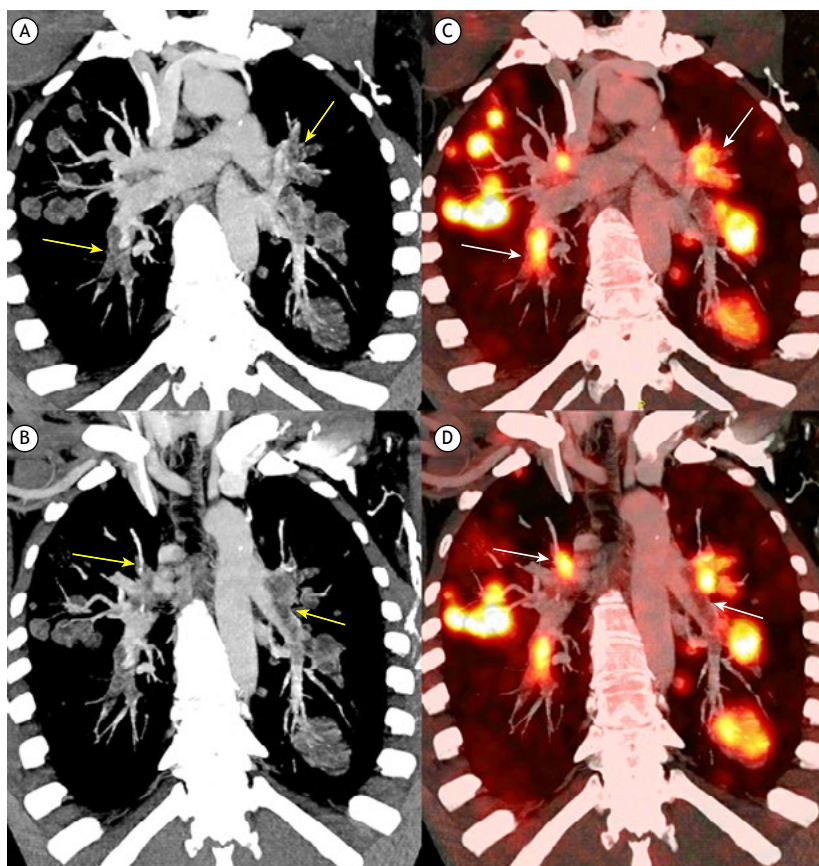


Figure 1. In A and B, coronal oblique maximum intensity projection CT reformations show the extent of the intravascular filling defects (yellow arrows). While the more expansive and nodular defects are easily seen as tumor lesions, those confined to the intravascular space are more difficult to differentiate from non-tumor thromboembolism. In C and D, coronal oblique fused PET/CT images demonstrate the extent of FDG hypermetabolism (white arrows). The fused images can separate the filling defects that have no FDG avidity and are therefore non-tumor lesions from those that show significant hypermetabolism indicating intravascular tumor embolism.

1. Real e Benemérita Associação Portuguesa de Beneficência, São Paulo (SP) Brasil.

AUTHOR CONTRIBUTIONS

All of the authors equally contributed to the writing and reviewing of the manuscript.

CONFLICTS OF INTEREST

None declared.

REFERENCES

1. Zhu AH, Hou XY, Tian S, Zhang WF. Diagnostic value of ¹⁸F-FDG PET/CT versus contrast-enhanced MRI for venous tumour thrombus and venous bland thrombus in renal cell carcinoma. *Sci Rep.* 2022;12(1):587. <https://doi.org/10.1038/s41598-021-04541-9>
2. Davidson T, Goitein O, Avigdor A, Zwas ST, Goshen E. 18F-FDG-PET/CT for the diagnosis of tumor thrombosis. *Isr Med Assoc J.* 2009;11(2):69-73.
3. Konstantinides SV, Meyer G, Becattini C, Bueno H, Geersing GJ, Harjola VP, et al. 2019 ESC Guidelines for the diagnosis and management of acute pulmonary embolism developed in collaboration with the European Respiratory Society (ERS). *Eur Heart J.* 2020;41(4):543-603. <https://doi.org/10.1093/eurheartj/ehz405>
4. Timp JF, Braekkan SK, Versteeg HH, Cannegieter SC. Epidemiology of cancer-associated venous thrombosis. *Blood.* 2013;122(10):1712-1723. <https://doi.org/10.1182/blood-2013-04-460121>
5. Roberts KE, Hamele-Bena D, Saqi A, Stein CA, Cole RP. Pulmonary tumor embolism: a review of the literature. *Am J Med.* 2003;115(3):228-232. [https://doi.org/10.1016/S0002-9343\(03\)00305-X](https://doi.org/10.1016/S0002-9343(03)00305-X)