

# Case Report

## Video-assisted thoracoscopic removal of foreign bodies from the pleural cavity\*

Videotoroscopia para remoção de corpo estranho da cavidade pleural

Giovanni Antonio Marsico<sup>1</sup>, André Luiz de Almeida<sup>2</sup>, Dirceo Edson de Azevedo<sup>3</sup>, Gustavo Carvalho Venturini<sup>4</sup>, Alexandre Edson de Azevedo<sup>1</sup>, Paula dos Santos Marsico<sup>5</sup>

### Abstract

Video-assisted thoracoscopy is a minimally invasive surgical technique. It is the procedure of choice for the treatment of certain lung and pleural diseases. It has been increasingly used in the acute phase of thoracic trauma. Another indication for its use, which is rarely described in the literature, is the removal of retained intrathoracic foreign bodies. We report the cases of two hemodynamically stable gunshot victims in whom the bullet was removed from the pleural cavity through video-assisted thoracoscopy, thereby avoiding the need for thoracotomy.

**Keywords:** Thoracic injuries; Wounds, penetrating; Thoracic surgery, video-assisted; Foreign bodies.

### Resumo

A videotoroscopia é considerada um procedimento cirúrgico minimamente invasivo. É o procedimento de escolha para o tratamento de algumas doenças pulmonares e pleurais. Cada vez mais vem sendo empregada na fase aguda do trauma torácico. Outra indicação de seu uso, pouco descrita na literatura, é para a remoção de corpos estranhos intratorácicos retidos. Relatamos o uso da videotoroscopia para a remoção de projéteis intrapleurais em dois pacientes hemodinamicamente estáveis nos quais a toracotomia foi evitada.

**Descritores:** Traumatismos torácicos; Ferimentos penetrantes; Cirurgia torácica video-assistida, Corpos estranhos.

### Introduction

Metallic foreign bodies, such as bullets, retained in the chest typically do not need to be removed unless they are greater than 2 cm in length. In cases of asymptomatic patients, most authors do not recommend the removal of these objects. Such foreign bodies are usually surrounded by fibrous tissue and are therefore innocuous. Whether or not surgery is indicated is defined by the precise location of the bullet, the symptoms that it causes, and the risks involved. The routine sequence consists of treating the lesions that are life-threatening, locating the bullet, and deciding whether or not to remove it. The decision of whether or not to remove the bullet is based on comparing the risk involved in allowing the bullet to remain in the body with that involved in trying to remove it. However, some patients can develop significant psychological problems.<sup>(1-3)</sup>

Video-assisted thoracoscopy is a less invasive method, replacing, in some cases, extensive thoracotomy.<sup>(1)</sup>

The authors report two cases in which a bullet free in the pleural cavity was removed through video-assisted thoracoscopy.

### Case report

#### Case 1

A 19-year-old male patient with a penetrating injury caused by a bullet sought treatment in the emergency room. The entry wound was located in the fourth right intercostal space, lateral to the nipple line. The patient was lucid, presented normal respiration and was hemodynamically stable. The mucosa was salmon-colored. The pulse

\* Study carried out in the Department of Thoracic Surgery of the Andaraí General Hospital/Ministry of Health, Rio de Janeiro, Brazil.

1. Thoracic Surgeon. Andaraí General Hospital/Ministry of Health, Rio de Janeiro, Brazil.

2. Second-year Medical Resident in Thoracic Surgery. Andaraí General Hospital/Ministry of Health, Rio de Janeiro, Brazil.

3. Head of the Department of Thoracic Surgery. Andaraí General Hospital/Ministry of Health, Rio de Janeiro, Brazil.

4. Third-year Medical Resident in Thoracic Surgery. Andaraí General Hospital/Ministry of Health, Rio de Janeiro, Brazil.

5. Intern in the Department of Thoracic Surgery. Andaraí General Hospital/Ministry of Health, Rio de Janeiro, Brazil.

Correspondence to: Giovanni Antonio Marsico. Hospital Geral do Andaraí, Serviço de Cirurgia Torácica, Rua Leopoldo, 280, 7º andar, Andaraí, CEP 20541-170, Rio de Janeiro, RJ, Brasil.

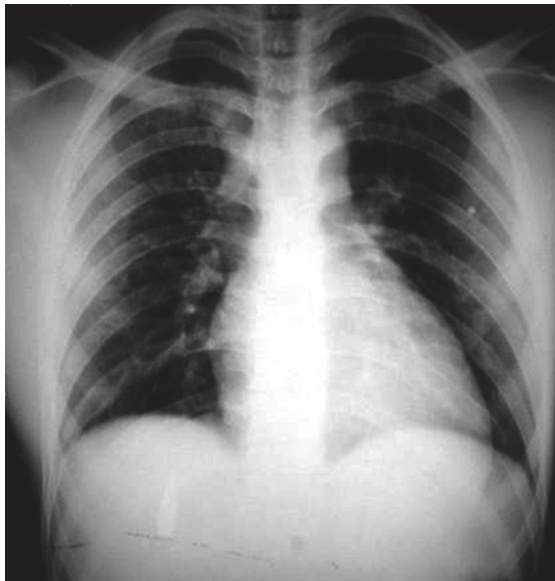
Tel 55 21 2575-7034. E-mail: marsicog@gbl.com.br

Submitted: 13 May 2007. Accepted, after review: 21 June 2007.

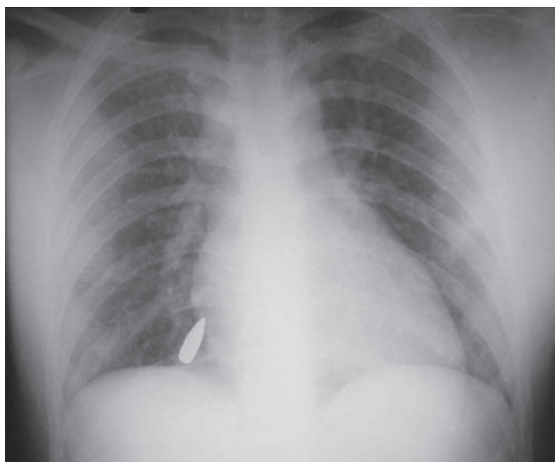
was regular and strong. The physical examination revealed no abnormalities. An anteroposterior chest X-ray revealed a high-velocity (rifle) bullet located near the liver (Figure 1). With the patient being placed in different positions, a second anteroposterior chest X-ray and a computed tomography scan showed a change in the position of the bullet, which was now located at the right cardiophrenic angle (Figure 2). With a diagnosis of a bullet free in the pleural cavity, removal via video-assisted thoracoscopy was indicated. Under general anesthesia, the patient was intubated with a double-lumen endotracheal tube and placed in the left lateral decubitus position. The procedure started with the introduction of one 10-mm trocar and two 5-mm trocars. In the initial inspection using a 30° endoscope, we found only a small ecchymosis in the middle lobe and a bullet, located in the anterior cardiophrenic recess, free in the pleural cavity. The bullet was easily removed with the aid of forceps. The chest tube was left in place for 24 h, and was discharged from the hospital on postoperative day 2.

### Case 2

A 25-year-old male patient with a gunshot wound was transferred from another hospital. The entry wound was located in the fifth intercostal space, in the midaxillary line. Upon admission to the emergency room, the patient was lucid, with good color, and well hydrated, presenting a strong, regular pulse and an arterial pressure of 120/80 mmHg. Subsequent routine X-rays of the chest and abdomen revealed a small left hemothorax and a bullet located in the paravertebral region (left costovertebral diaphragm recess) at the level of the twelfth rib (Figure 3). The patient underwent left water-sealed intercostal drainage, with an outflow of 300 mL of blood, and supraumbilical midline laparotomy. The diaphragm was intact, and no abdominal lesions were found. The chest drain was removed 48 h later. At that time, a surgical consult was requested. Retrospectively, we discovered that, on the initial chest X-ray, which had been taken at the hospital of origin, the bullet was located in the left costophrenic sulcus. Based on these findings as well as on the laparotomy findings, we concluded that the bullet was free in the pleural cavity. Under general anesthesia, the patient was submitted to orotracheal intubation with a

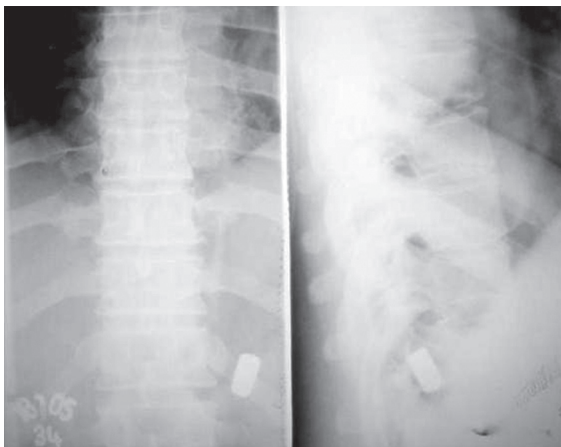


**Figure 1** - Bullet located near the liver.



**Figure 2** - After the patient had been placed in different positions, the bullet migrated to the cardiophrenic angle.

double-lumen tube and was placed in the right lateral decubitus position in order to undergo left video-assisted thoracoscopy. After the introduction of one 10-mm and one 5-mm trocar, we found, using a 30° endoscope, some blood clots located in the costovertebral diaphragm recess. These clots were aspirated. The bullet was also found at this site and was removed with the aid of forceps. The chest tube was removed 48 h later, and the patient was discharged from the hospital on postoperative day 8.



**Figure 3** – Bullet located in the left paravertebral region at the level of the twelfth rib.

## Discussion

For use in cases of trauma, video-assisted thoracoscopy is considered a safe procedure. Video-assisted thoracoscopy is often used in cases of retained pneumothorax, in cases of persistent pneumothorax, and in the evaluation of the diaphragm after a penetrating trauma. The use of video-assisted thoracoscopy for the diagnosis of cardiac tamponade and the creation of a pericardial window has been described, as has its use in cases of persistent hemothorax in stable patients. In cases of trauma, according to the findings, video-assisted thoracoscopy precludes or indicates thoracotomy or laparotomy in a significant number of patients. Currently, its use is contemplated when there is a need to remove an intrathoracic foreign body.<sup>(3)</sup>

In cases of gunshot victims in which there is no exit wound and the bullet is not found in the expected place, the possibility of the bullet having migrated should be considered. As any other foreign body, bullets free in the pleural space are subject to the force of gravity and move according to the patient position until they lodge in a given place. Such injuries can be accompanied by pneumothorax or hemothorax. On X-rays taken with the patient standing, the bullet typically appears at the lowest possible position within the pleural cavity and is occasionally misinterpreted as being located in the abdomen. In the acute phase of the lesion, an X-ray taken in the lateral decubitus position reveals the change in the position of the metallic foreign body

free in the pleural cavity. In the late phase, usually, the irritation process causes fibrous adherences that have the end result of lodging the foreign body in the point of greatest declination.<sup>(4,5)</sup>

In our two patients, the X-rays were taken in the acute phase, when the bullets were still free in the pleural cavity. In Case 2, the bullet was thought to be located in the abdomen.

Only a few studies have addressed the use of video-assisted thoracoscopy for the removal of intrathoracic foreign bodies. This is a safe and less invasive method that, in the acute phase of the trauma in hemodynamically stable patients, allows the removal of the foreign body from the pleural cavity under direct viewing. In addition, it reduces the number of complications, the degree of post-operative pain, and the length of hospitalization. It can be safely used for the removal of various types of foreign bodies, such as catheters, wires, needles, nails, glass, and bullets. When it is necessary to convert to a thoracotomy, it is possible to determine the correct location, size, and extent of the incision according to the position and the type of foreign body.<sup>(3)</sup>

Retained intrathoracic metallic bullets rarely cause complications or symptoms. The removal of bullets located in the pleural cavity is indicated when they cause infection or symptoms, as occurs only in rare cases. Occasionally, the principal reason for the removal of intrathoracic foreign bodies is the existence of significant psychological problems. However, the removal is necessary in cases of non-metallic foreign bodies, as well as in cases of large metallic objects or objects with sharp edges.<sup>(2,3,5)</sup>

In asymptomatic and symptomatic patients alike, if the steel wires or pins used for osteosynthesis have migrated to the interior of the chest, surgical removal is mandatory. Since these are sharp objects, there is a risk that they will erode or perforate the organs and adjacent structures. Computed tomography is important in the preoperative evaluation. One group of authors used video-assisted thoracoscopy to remove four intrathoracic foreign bodies.<sup>(4)</sup> Of those, three were located in the pleural cavity: a bullet; a grenade fragment; and a Kirschner wire that had migrated to the pleural cavity. The fourth body was a bullet free in the pericardial sac.

Another group of authors<sup>(1)</sup> also used video-assisted thoracoscopy to remove two fragments of glass, the larger one being 3.5 cm in length, from

the pleural cavity. The fragments were identified on the computed tomography scan.

In our two patients, we opted for removal of the bullets from the pleural cavity before they could become lodged and surrounded by fibrosis.

Some researchers<sup>(3,5)</sup> believe that the ease and practicality of video-assisted thoracoscopy, as compared with thoracotomy, should not be used as the principal argument in favor of the removal of intrathoracic bullets.

The finding of a bullet free in the pleural cavity is rare, and the question of whether removal is indicated or not is controversial. Currently, we consider that, with the use of video-assisted thoracoscopy, the early removal in stable patients, before the bullets are engulfed by the surrounding tissues, is easy, simple, and practically risk-free.

## References

1. Bartek JP, Grasc A, Hazelrigg SR. Thoracoscopic retrieval of foreign bodies after penetrating chest trauma. *Ann Thorac Surg.* 1997;63(6):1783-5.
2. Edil BH, Trachte AL, Knott-Craig C, Albrecht RM. Video-assisted thoracoscopic retrieval of an intrapleural foreign body after penetrating chest trauma. *J Trauma* 2006;61(13):1-2.
3. Williams CG, Haut ER, Ouyang H, Riall TS, Makary M, Efron DT, et al. Video-assisted thoracic surgery removal of foreign bodies after penetrating chest trauma. *J Am Coll Surg.* 2006;202(5):848-52.
4. Lang-Lazdunski L, Mouroux J, Pons F, Grosdidier G, Martinod E, Elkaïm D, et al. Role of videothoracoscopy in chest trauma. *Ann Thorac Surg.* 1997;63(2):327-33.
5. Potaris K, Mihos P, Gakidis I. Role of video-assisted thoracic surgery in the evaluation and management of thoracic injuries. *Interact Cardiovasc Thorac Surg.* 2005;4(4):292-4.