



Empyema caused by infection with *Clostridium septicum* in a patient with lung cancer

Gabriel Afonso Dutra Kreling^{1,a}, Marília Ambiel Dagostin^{1,b}, Marcelo Park^{2,c}

TO THE EDITOR:

A 58-year-old man presented to our outpatient clinic with a 5-month history of weight loss (total weight lost, 18 kg). In the last two months, he also had a progressive cough and dyspnea, accompanied by right-sided chest pain on taking a breath. Computed tomography (CT) of the chest, performed for diagnostic investigation, showed a mass at the right lung base. The patient underwent CT-guided biopsy to obtain a tissue sample from the mass. On the day of the procedure, the patient was experiencing worsening symptoms of chest pain, cough, and dyspnea, which was associated with the onset of fever 2 days later.

The CT scan (Figure 1) showed right hydropneumothorax. The patient underwent diagnostic thoracentesis to obtain pleural fluid for analysis (Table 1), after which he underwent chest drainage.

The patient was hospitalized, receiving ceftriaxone and clarithromycin. On the second day of hospitalization, there was clinical worsening, with tachycardia and a decreased level of consciousness. Accordingly, the antibiotic treatment was changed to piperacillin-tazobactam. The patient then developed multiple organ dysfunction syndrome and was transferred to the ICU. At admission to the ICU, the Sequential Organ Failure Assessment score was 6 (indicative of pulmonary, renal, and hepatic dysfunction), and the Simplified Acute Physiology Score III score was 83. Considering the advanced stage of the disease and the clinical worsening of the patient, palliative care was preferred. The patient died comfortably on the sixth day of hospitalization. The examination of the lung mass biopsy confirmed the diagnosis of non-small cell lung cancer with a low degree of differentiation and extensive areas of necrosis. Culture of the pleural fluid showed growth of *Clostridium septicum*.

Clostridium septicum is a gram-positive anaerobic microorganism that is highly pathogenic because of the action of alpha-toxin and other enzymes such as hyaluronidase, fibrinolysin, deoxyribonuclease, and hemolysins.^(1,2) Reports indicate that this microorganism can cause tissue necrosis, hemolysis, intravascular thrombosis, and disseminated intravascular coagulation.⁽³⁾ *Clostridium septicum* is believed to be present in the normal intestinal flora,⁽⁴⁾ although it has not been identified in studies of human fecal cultures.⁽⁵⁾

Clostridium septicum infection is known to be associated with gastrointestinal, laryngeal, breast, and prostate cancer, as well as with hematological malignancies. To our knowledge, this is the first description of a case

of empyema caused by *C. septicum* in a patient with non-small cell lung cancer.

Clostridium septicum displays tropism for necrotic tissues, perhaps because anaerobic glycolysis may produce an acidic environment favoring germination of *Clostridium* spores. This acidic environment is found in malignant tumors and is probably the gateway to *C. septicum* infection,^(1,4) which is known to be associated with neoplasms, as well as with some forms of immunosuppression.⁽²⁾ Two reviews of the literature on *C. septicum* infection showed that cancer is found in 80%⁽¹⁾ and 85%⁽⁴⁾ of cases, respectively, the main neoplasms being colorectal cancer and hematological malignancies. Other previously reported, although less common, neoplasms were cancer of the larynx, breast, and prostate.^(4,6) There have been no reports of lung cancer associated with *C. septicum* infection.

Colorectal neoplasms usually have a necrotic aspect, and leukemia appears to predispose an individual to pseudomembranous colitis, agranulocytic lesions (ulcers or abscesses), and ischemic colitis, which can result in areas of the intestine becoming necrotic or inflamed,⁽⁷⁾ providing gateways for *C. septicum* infection.

Among patients with *C. septicum* infection, the mortality rate for those who do not receive antibiotic therapy is virtually 100%, whereas the reported overall mortality rate ranges from 48% to 65%.^(1,4) *Clostridium septicum* has the capacity to aggressively invade tissues, even in the absence of trauma.⁽⁸⁾ *Clostridium septicum* has been found to cause metastatic infections in regions such as the meninges, thyroid, bone, joints, spleen, and anterior chamber of the eye.⁽¹⁾ The main forms of presentation of *C. septicum* infections are bacteremia; acute abdomen, caused by sepsis; and myonecrosis in the extremities and in the trunk.⁽¹⁾ The only reported case of empyema caused by *C. septicum* was in an immunocompetent woman with acute abdomen and an internal hernia, together with an incarcerated ileum and ischemia, which created the portal of entry for the microorganism.⁽⁹⁾

Nontraumatic cases of pleuropulmonary infection by anaerobic microorganisms alone are uncommon and are usually associated with some chronic disease or immune system impairment.⁽¹⁰⁾ The main isolated species of *Clostridium* that are associated with pleuropulmonary infection are *C. perfringens* (the most common species), *C. sordellii*, *C. sporogenes*, *C. paraputrificum*, and *C. bifermentans*.⁽¹⁰⁾ Most primary clostridial pleuropulmonary infections occur as a result of iatrogenic contamination of the pleural space. In a case report and review of the

1. Programa de Residência em Clínica Médica, Hospital das Clínicas, Faculdade de Medicina, Universidade de São Paulo, São Paulo (SP) Brasil.

2. Unidade de Terapia Intensiva, Hospital das Clínicas, Faculdade de Medicina, Universidade de São Paulo, São Paulo (SP) Brasil.

a. <http://orcid.org/0000-0003-1212-3166>; b. <http://orcid.org/0000-0002-3203-768X>; c. <http://orcid.org/0000-0002-4201-2718>

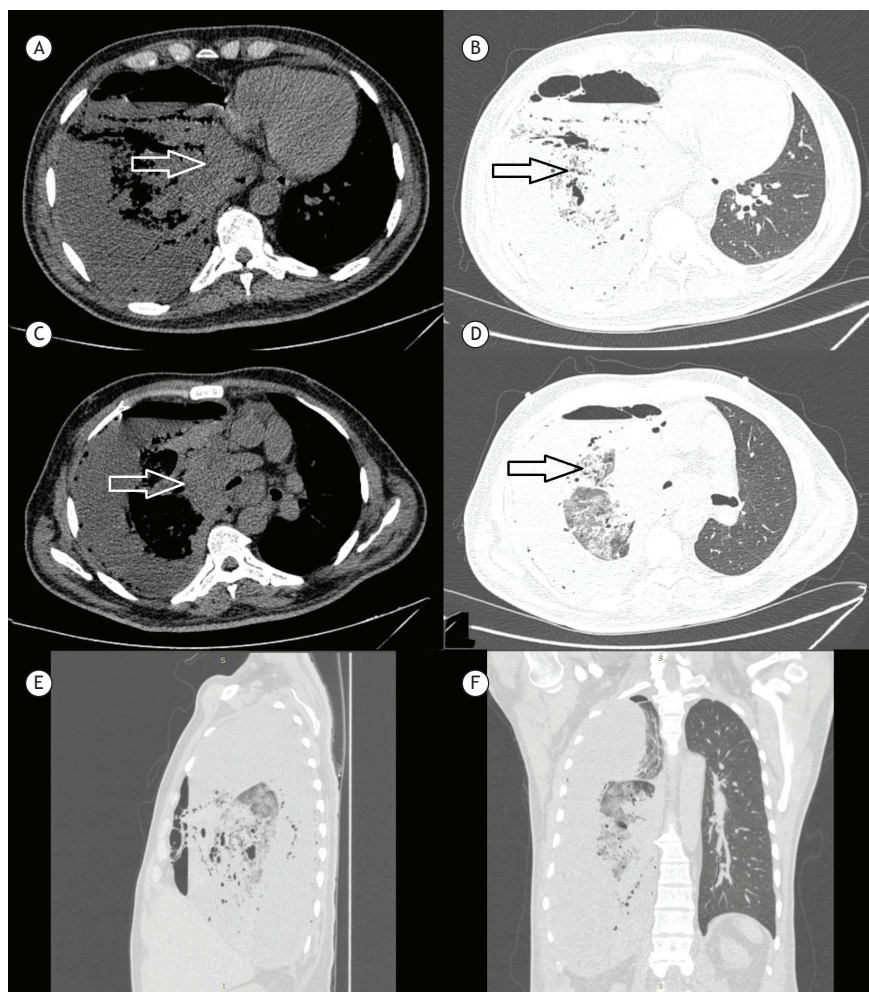


Figure 1. CT scans of the chest, showing massive hydropneumothorax in the right lung, with almost total restrictive atelectasis (A through F). Note the perihilar mass affecting the middle and lower lobes of the right lung (white arrow in A and C). In the remaining parenchyma of the right lung, there are consolidations with air bronchograms and bronchiectasis, accompanied by ground-glass opacities, suggestive of an inflammatory/infectious process (black arrow in B and D).

Table 1. Characteristics of the pleural fluid.

Aspect	Hemorrhagic
pH	6.2
LDH	> 10,000 U/L
Cytology	44,800 cells/mm ³
Glucose	132 mg/dL

LDH: lactate dehydrogenase.

literature, 17 cases of pleuropulmonary infection due to *Clostridium* spp. in the absence of a history of trauma were evaluated, and 30% of those cases were found to have occurred after thoracentesis or biopsy, both performed with sterile techniques.⁽¹⁰⁾ In the case reported here, that was the likely port of entry of *C. septicum* infection. The mortality rate of

pleuropulmonary infection due to *Clostridium* spp. is approximately 30%, and the prognosis improves after appropriate antibiotic therapy and adequate drainage of the infected pleural fluid.⁽¹⁰⁾

One limitation of our report is that, because of the performance status of the patient, we did not attempt to identify concomitant neoplasms in other organs or tissues. Nevertheless, given the strong association between *C. septicum* infection and cancer, patients infected with *C. septicum* should be screened for neoplasia (if there is no other diagnosis), mainly colorectal cancer and hematological malignancies, although other types of cancer should not be overlooked.

REFERENCES

1. Kornbluth AA, Danzig JB, Bernstein LH. *Clostridium septicum* infection and associated malignancy. Report of 2 cases and review of the literature. *Medicine (Baltimore)*. 1989;68(1):30-7. <https://doi.org/10.1097/00005792-198901000-00002>
2. Johnson S, Driks MR, Tweten RK, Ballard J, Stevens DL, Anderson DJ, et al. Clinical courses of seven survivors of *Clostridium septicum*

- infection and their immunologic responses to alpha toxin. *Clin Infect Dis*. 1994;19(4):761-4. <https://doi.org/10.1093/clinids/19.4.761>
3. Panikkath R, Konala V, Panikkath D, Umyarova E, Hardwicke F. Fatal *Clostridium septicum* infection in a patient with a hematological malignancy. *Proc (Bayl Univ Med Cent)*. 2014;27(2):111-2. <https://doi.org/10.1080/08998280.2014.11929074>
 4. Alpern RJ, Dowell VR Jr. *Clostridium septicum* infections and malignancy. *JAMA*. 1969;209(3):385-8. <https://doi.org/10.1001/jama.1969.03160160021004>
 5. Kopliku FA, Schubert AM, Mogle J, Schloss PD, Young VB, Aronoff DM. Low prevalence of *Clostridium septicum* fecal carriage in an adult population. *Anaerobe*. 2015; 32:34-6. <https://doi.org/10.1016/j.anaerobe.2014.12.001>
 6. Chew SS, Lubowski DZ. *Clostridium septicum* and malignancy. *ANZ J Surg*. 2001;71(11):647-9. <https://doi.org/10.1046/j.1445-1433.2001.02231.x>
 7. PROLLA JC, KIRSNER JB. THE GASTROINTESTINAL LESIONS AND COMPLICATIONS OF THE LEUKEMIAS. *Ann Intern Med*. 1964;61:1084-103. <https://doi.org/10.7326/0003-4819-61-6-1084>
 8. Srivastava I, Aldape MJ, Bryant AE, Stevens DL. Spontaneous *C. septicum* gas gangrene: a literature review. *Anaerobe*. 2017; 48:165-171. <https://doi.org/10.1016/j.anaerobe.2017.07.008>
 9. Granok AB, Mahon PA, Biesek GW. *Clostridium septicum* Empyema in an Immunocompetent Woman. *Case Rep Med*. 2010;2010:231738. <https://doi.org/10.1155/2010/231738>
 10. Patel SB, Mahler R. Clostridial pleuropulmonary infections: case report and review of the literature. *J Infect*. 1990;21(1):81-5. [https://doi.org/10.1016/0163-4453\(90\)90738-T](https://doi.org/10.1016/0163-4453(90)90738-T)