

Technical validation of pulmonary drainage for the treatment of severe pulmonary emphysema: a cadaver-based study*

Validação técnica da drenagem pulmonar como tratamento do enfisema pulmonar avançado: estudo anatômico em cadáveres

Júlio Mott Ancona Lopez, Roberto Saad Jr, Vicente Dorgan Neto, Marcio Botter, Roberto Gonçalves, Jorge Henrique Rivaben

Abstract

Objective: A cadaver-based study was carried out in order to describe the pulmonary drainage surgical technique, to determine whether the site for the insertion of the chest tube is appropriate and safe, and to determine the anatomical relationship of the chest tube with the chest wall, lungs, large blood vessels, and mediastinum. **Methods:** Between May and November of 2011, 30 cadavers of both genders were dissected. The cadavers were provided by the *Santa Casa de São Paulo* Central Hospital Mortuary, located in the city of São Paulo, Brazil. A 7.5-cm, 24 F steel chest tube was inserted into the second intercostal space along the midclavicular line bilaterally, and we measured the distances from the tube to the main bronchi, upper lobe bronchi, subclavian vessels, pulmonary arteries, pulmonary arteries in the upper lobe, superior pulmonary vein, azygos vein, and aorta. Weight, height, and chest wall thickness, as well as laterolateral and posteroanterior diameters of the chest, were measured for each cadaver. **Results:** Of the 30 cadavers dissected, 20 and 10 were male and female, respectively. The mean distance between the distal end of the tube and the main bronchi (right and left) was 7.2 cm (for both). **Conclusions:** The placement of a fixed-size chest tube in the specified position is feasible and safe, regardless of the anthropometric characteristics of the patients.

Keywords: Emphysema; Surgical procedures, operative; Thoracic surgery; Cadaver.

Resumo

Objetivo: Descrever a técnica operatória da drenagem pulmonar através do estudo anatômico em cadáveres, determinar se o local definido para a drenagem pulmonar é adequado e seguro, e determinar a relação anatômica do tubo de drenagem com a parede torácica, pulmões, grandes vasos e mediastino. **Métodos:** Foram dissecados 30 cadáveres de ambos os sexos, fornecidos pelo Necrotério do Hospital Central da Santa Casa de São Paulo, em São Paulo (SP) no período entre maio e novembro de 2011. Foi inserido um dreno de aço de 7,5 cm com 24 F de diâmetro no segundo espaço intercostal, na linha médio-clavicular, bilateralmente, e foi medida a distância do dreno com as seguintes estruturas: brônquios principais, brônquios dos lobos superiores, vasos subclávios, artérias pulmonares, artérias pulmonares do lobo superior, veia pulmonar superior, veia ázigos e aorta. Foram realizadas medições de peso, altura, diâmetro laterolateral do tórax, diâmetro posteroanterior do tórax e espessura da parede torácica de cada cadáver. **Resultados:** Dos 30 cadáveres dissecados, 20 e 10 eram do sexo masculino e feminino, respectivamente. A média da extremidade distal do dreno com os brônquios principais direito e esquerdo foi de 7,2 cm. **Conclusões:** A utilização de um dreno torácico de tamanho fixo na posição preconizada é factível e segura, independentemente das características antropométricas do paciente.

Descritores: Enfisema; Procedimentos cirúrgicos operatórios; Cirurgia torácica; Cadáver.

* Study carried out at the *Santa Casa de São Paulo* School of Medical Sciences, São Paulo, Brazil.

Correspondence to: Júlio Mott Ancona Lopez. Rua Vanderlei, 527, apto. 51, Perdizes, CEP 05011-001, São Paulo, SP, Brasil.

Tel. 55 11 3064-4011 or 55 11 98346-4604. Fax: 55 11 3064-4011. E-mail: mottlopez@uol.com.br

Financial support: None.

Submitted: 18 July 2012. Accepted, after review: 11 November 2012.

Introduction

The disease COPD is a nosological entity characterized by chronic airflow obstruction, associated with chronic bronchitis and emphysema.⁽¹⁾ In the latter, there is an abnormal enlargement of the air spaces distal to the terminal bronchiole, accompanied by destructive changes of the alveolar walls.

In pulmonary emphysema, the destruction of the alveolar walls adversely affects the essential functions of the ventilatory mechanism. Without the alveolar tissue elastic recoil and radial support properties, alveolar pressures will cause airway collapse during exhalation. Airflow communication among adjoining alveoli (collateral ventilation) is much more prevalent in the emphysematous lung than in the normal lung.

Bullous emphysema occurs as a result of bronchospastic obstructive disorders of the bronchioles, with rupture of the interalveolar septa, forming extremely thin-walled, air-filled vesicles that are functionally inert and take up considerable space in the chest cavity.⁽²⁾

Lung volume reduction surgery (LVRS) or “pneumoplasty” is indicated only in cases of heterogeneous emphysema in which most of the diseased area of the lung is resected, allowing the remaining tissue to work more efficiently. Lung transplantation (LTx) is the only option for patients with advanced diffuse (homogeneous) emphysema.⁽³⁾

Two important limitations of LTx are the chronic shortage of organs and the limited number of specialized centers, which result in increased waiting time for an organ of such a magnitude that 25% of candidates for LTx die while on the waiting list.⁽⁴⁾

Both methods require general anesthesia, ICU admission, and prolonged hospital stays, as well as having high morbidity and mortality. In addition, the costs are high. In the USA, LVRS has an approximate cost of US\$20,000, whereas unilateral LTx costs approximately US\$400,000.⁽⁵⁾

In the Department of Surgery of the *Faculdade de Ciências Médicas da Santa Casa de São Paulo* (FCMSCSP, *Santa Casa de São Paulo* School of Medical Sciences), located in the city of São Paulo, Brazil, surgery for pulmonary emphysema has been performed since 1956,⁽⁶⁾ such as in cases of thoracotomy for resection of emphysematous pulmonary bullae.

Since the 1990s, video-assisted thoracic surgery has been used to treat patients with bullous emphysema. However, regardless of the route of access, patients undergo general anesthesia, resection of diseased lung parenchyma, and (manual or staple) suturing of lung parenchyma. Mortality ranges from 1.5% to 26%.^(2,7)

To simplify surgical treatment and reduce the number of resulting complications, Goldstraw et al.,⁽⁷⁾ in 1988, described the technique for drainage of emphysematous bullae in 20 patients, with resection of costal segment and general anesthesia. There was symptomatic improvement in 94% of patients, as well as objective improvement in pulmonary reserve, as measured by spirometry.⁽⁷⁾

In 1996, a treatment alternative for patients with giant emphysematous bullae was introduced by the FCMSCSP surgical team: simple drainage under local anesthesia.⁽²⁾ This technique was developed at our facility and is based on a modification of the procedure described by Monaldi⁽⁸⁾ for the treatment of tuberculous lung cavities. It is performed through a small thoracostomy in association with pleurodesis with talc, which is introduced through the chest tube.⁽²⁾

In an article published in 2007, Botter et al.⁽²⁾ described 31 procedures of thoracostomy drainage of bullae under local anesthesia in 27 patients. From a functional standpoint, spirometric parameters were improved one month after surgery when compared with preoperative values.

To provide one more treatment alternative for the relief of the debilitating effects of advanced emphysema, surgeons at our institution presented, in 2008, a new protocol⁽⁹⁾ for the treatment of patients with either homogeneous or heterogeneous pulmonary emphysema who, even after having undergone the gold standard treatment, continue to have disabling dyspnea.

The proposed method is designed to create alternative exhalation passageways by draining the lung parenchyma, thereby establishing communication between the alveoli and the external environment. A small thoracotomy is performed in the second intercostal space at the midclavicular line to access the affected lung. A fixed-size chest tube is placed in the opening and is attached to the lung. The tube is located within the lung parenchyma and is inserted after blunt dissection of the lung parenchyma. Another

chest tube is placed into the pleural space to aid lung reexpansion, whereas the first one remains in the lung indefinitely.

This procedure is a surgical alternative to LVRS and LTx and has the following advantages:

- It is performed under local anesthesia, without the need for ventilatory support during surgery
- No resection or suturing of diseased lung parenchyma is performed
- Immunosuppressants are not used, and, consequently, their inconvenient adverse effects are avoided
- It is technically simple
- It requires short hospitalization, and ICU admission might not be necessary
- It is inexpensive (approximately US\$1,000)

In our original study,⁽⁹⁾ the inclusion criteria were as follows: having emphysema; being 75 years or younger; being disabled despite having undergone the gold standard treatment (pulmonary rehabilitation); having chest X-ray findings of lung hyperinflation and HRCT findings of homogeneous or heterogeneous emphysema; having a post-bronchodilator FEV₁ less than 35–30% of predicted, a TLC greater than 250% of predicted, and a DLCO less than 50% of predicted; having stopped smoking at least three months before the procedure; and being on a waiting list for LTx or LVRS.

After approval by the FCMSCSP Human Research Ethics Committee, the first surgical procedures were performed, with encouraging results. To date, 9 patients have been operated on with this technique. The results for 3 of those 9 cases have been reported recently.⁽¹⁰⁾

Despite the significant clinical improvement observed in the operated patients, there have been no experimental studies describing the technical and anatomical aspects of pulmonary drainage in terms of the safety of the technique in accessing the lung satisfactorily without injuring the patient's vital structures. Nor have there been studies designed to determine whether the use of a fixed-size chest tube, regardless of the anthropometric characteristics of the patients, affects the results.

We therefore designed this cadaver-based study to describe the surgical technique for pulmonary drainage, to determine whether the site for the insertion of the chest tube is appropriate and safe, and to determine the anatomical relationship of

the chest tube with the following structures: chest wall; lungs; large blood vessels; and mediastinum.

Methods

Initially, the research project was presented to the Scientific Committee of the Department of Surgery and to the Heads of the Department of Anatomic Pathology of the FCMSCSP with the aim of obtaining authorization for its performance. After authorization was granted, the research project was submitted to the FCMSCSP Human Research Ethics Committee for approval. Between May and November of 2011, 30 cadavers of both genders were dissected at the *Santa Casa de São Paulo* Central Hospital Mortuary, located in the city of São Paulo, Brazil.

For inclusion of cadavers in the study, family members (or legal guardians) gave written informed consent. The consent form was presented to the family members (or legal guardians) by one of the researchers, who answered any questions about the procedure that would be performed. All surgical procedures were performed by the same researcher. We included cadavers of patients at the *Santa Casa de São Paulo* who died of natural (non-violent) causes and in whom the chest wall, mediastinum, pleural space, and lungs were intact.

We excluded cadavers with extensive lung destruction, such as significant adhesions (cases of severe tuberculosis or pneumonia, for instance).

The following anthropometric variables were measured on each cadaver: weight; height; posteroanterior diameter of the chest; laterolateral diameter of the chest; and chest wall thickness. The same pair of 7.5-cm, 24 F steel chest tubes was always used.

Initially, the chest tube was inserted into the second intercostal space at the midclavicular line, bilaterally, perpendicularly to the chest wall. The sternum was opened transversely, and the entire anterior chest wall was removed (sternal plastron), approximately at the level of the fourth intercostal space (Figure 1). Subsequently, chest wall thickness was measured bilaterally, near the opening for the insertion of the chest tube. Since the pleural cavity was exposed, the lung was atelectatic, and the distal end of the chest tube was found to be inserted into the pleural cavity (Figure 2). With the lung in its normal anatomical position and having the intrathoracic, distal end of the chest tube as a reference, we

measured, with a ruler, the distances from the tube to the following structures: right and left main bronchi; right and left upper lobe bronchi; right and left upper lobe pulmonary arteries; right and left pulmonary arteries; and right and left subclavian veins and arteries (Figure 3). The lung was then pushed aside, and we measured, on the left, the distance from the tube to the aortic arch and, on the right, the distance from the tube to the azygos vein.

The variables chosen for the statistical analysis included the following: gender; weight (kg); height (cm); posteroanterior diameter of the chest (cm); laterolateral diameter of the chest

(cm); distance from the tube to the main bronchi (cm); distance from the tube to the right and left upper lobe bronchi (cm); distance from the tube to the right and left subclavian vessels (cm); distance from the tube to the right and left pulmonary arteries (cm); distance from the tube to the right and left upper pulmonary arteries (cm); distance from the tube to the right and left superior pulmonary veins (cm); distance from the tube to the azygos vein (cm); wall thickness (cm); and distance from the tube to the aorta (cm).

For these variables, we performed an exploratory analysis to obtain information relevant to the study. For qualitative variables, we calculated frequencies and percentages, whereas, for quantitative variables, we calculated means, medians, standard deviations, and ranges (minimum and maximum).^(11,12) The relationship between the measured distances from the chest tube to the anatomical structures and the anthropometric variables measured on the cadavers was investigated by calculation of Spearman's correlation coefficient.^(10,11)

Results

Of the 30 cadavers dissected, 20 and 10 were male and female, respectively.

Table 1 shows that the mean weight of the operated cadavers was 68.6 ± 2.1 kg, and the median weight was 66.5 kg. The mean height was 1.70 ± 0.02 m, and the median height was 1.70 m. The mean posteroanterior diameter of the chest was 29.4 ± 2.8 cm, and the median

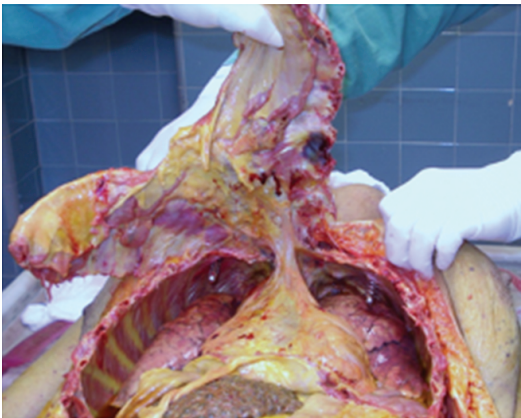

Figure 1 - Resection of the anterior ribs.

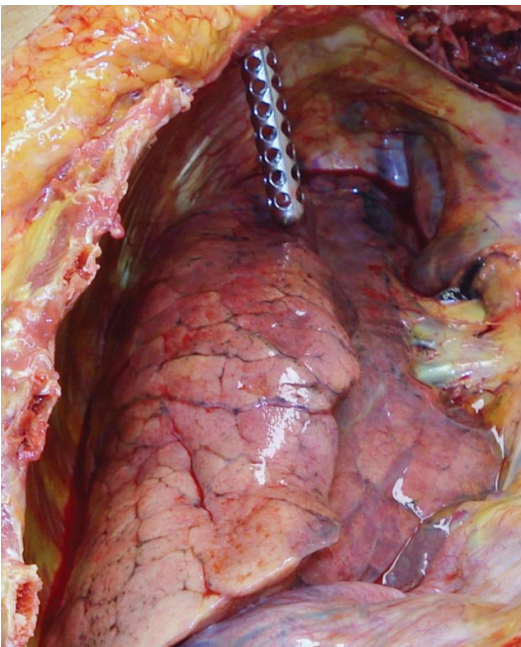


Figure 2 - Chest tube inserted into the pleural cavity.

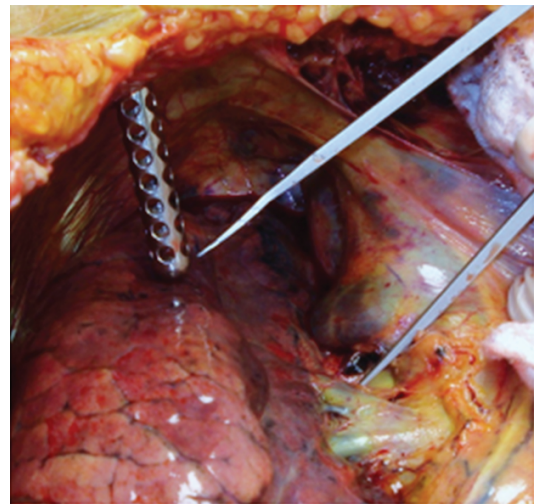


Figure 3 - Distance from the distal end of the chest tube to the right upper lobe artery.

posteroanterior diameter was 22.5 cm. The mean laterolateral diameter of the chest was 34.5 ± 1.1 cm, and the median laterolateral diameter was 34.0 cm.

We measured the distances (in cm) from the intrathoracic, distal end of the chest tube to each of all anatomical structures in question, except wall thickness (Table 2). No anatomical structure was perforated by the chest tube, i.e., none of the distances measured were equal to zero. The mean wall thickness was 2.9 ± 0.2 cm. The greatest mean distance to the chest tube was 7.2 ± 0.2 cm, for the left main bronchus, and the smallest mean distance was 5.2 ± 0.2 cm, for the left upper lobe pulmonary artery.

In all cases, the intrathoracic, distal end of the chest tube touched or partially perforated the anterior segment of the upper lobes bilaterally. The intensity of contact between the chest tube

and the lung depended on whether the lung was partially expanded or collapsed.

Discussion

To our knowledge, there have been no studies describing pulmonary drainage in the treatment of severe pulmonary emphysema, except for the previously mentioned studies carried out by the FCMSCSP team of thoracic surgeons.^(9,10) However, in his study of collateral ventilation, Macklem, in 1978,⁽¹³⁾ hypothetically mentions creation of communication between the emphysematous parenchyma and the environment as a way of decompressing trapped air.

On the basis of previously demonstrated success and experience in accessing the lung parenchyma, either by bronchostomy, as described by Saad Jr.,⁽¹⁴⁾ or by drainage of giant emphysematous

Table 1 - Summary of measurements of anthropometric variables.

Variable	n	Minimum	Maximum	Mean	Median	Standard error
Weight, kg	30	50.0	88.0	68.6	66.5	2.1
Height, m	30	1.4	1.9	1.7	1.7	0.02
Age, years	30	24.0	82.0	61.8	68.0	2.8
Anteroposterior diameter of the chest, cm	30	15.0	60.0	29.4	22.5	2.5
Laterolateral diameter of the chest, cm	30	22.0	53.0	34.5	34.0	1.1

Table 2 - Summary of measurements of anatomical variables.^a

Variable	n	Minimal	Maximal	Mean	Median	Standard error
Right side						
Main bronchus	30	4.5	9.0	7.2	7.0	0.2
Upper lobe bronchus	30	4.0	10.0	6.0	6.0	0.2
Subclavian vessels	30	4.0	9.0	6.4	6.5	0.2
Phrenic nerve	30	4.0	8.0	5.9	6.0	0.2
Pulmonary artery	30	5.0	10.0	7.1	6.8	0.2
Upper lobe pulmonary artery	30	4.0	8.5	5.8	5.8	0.2
Superior pulmonary vein	30	4.0	10.0	6.4	6.0	0.2
Azygos vein	30	4.0	11.0	7.0	7.0	0.3
Wall thickness	30	1.5	5.0	2.9	3.0	0.2
Left side						
Main bronchus	30	6.0	10.0	7.2	7.0	0.2
Upper lobe bronchus	30	4.5	11.0	5.8	6.0	0.2
Subclavian vessels	30	4.0	9.0	56.0	6.0	0.2
Phrenic nerve	30	4.0	9.0	6.1	6.0	0.2
Pulmonary artery	30	4.5	9.0	6.4	6.2	0.2
Upper lobe pulmonary artery	30	3.5	9.0	5.2	5.0	0.2
Superior pulmonary vein	30	4.0	9.0	6.0	6.0	0.2
Wall thickness	30	1.5	5.0	2.9	3.0	0.1
Aorta	30	3.0	9.0	6.2	6.2	0.4

^aAll distances are expressed in cm.

bullae, as described by Botter,⁽²⁾ a clinical protocol was developed for the purpose of identifying candidates for pulmonary drainage.⁽⁸⁾

The analysis of the data gathered in this study led to some important considerations:

- The increased posteroanterior diameter of the chest in patients with COPD makes the technique for pulmonary drainage recommended in the protocol even safer, given that the mediastinal structures are more detached from the chest wall because of the hyperinflated lung
- The distal end of the chest tube was related to the anterior segments of the upper lobes bilaterally; therefore, insertion of the chest tube into the second intercostal space at the midclavicular line provides satisfactory access to the lung region to be drained (target area)
- Of the nine operated patients, eight underwent pulmonary drainage unilaterally and one (the last one) underwent the procedure bilaterally, which was found to be perfectly feasible and clinically safe
- There is no difference between chest wall thickness on the right and left sides, the mean chest wall thickness being 2.9 cm; since the chest tube measures 7.5 cm, there were therefore 4.6 cm of intrathoracic chest tube available to penetrate the cadaver lung. During the surgical procedure, approximately 5 cm of chest tube is inserted into the parenchyma. From a clinical standpoint, this value seems to be safe, given that there was no significant bleeding during the surgical procedure, as well as efficient, allowing satisfactory drainage of the trapped air. Of the nine operated patients, only one had bleeding through the chest tube insertion site in the late postoperative period. At the time, a chest X-ray showed that the distal end of the chest tube was in close contact with the peripheral vessels of the lung parenchyma but not with those of the hilum. The late onset of bleeding suggests neovascularization related to local foreign-body-type inflammation. Once the chest tube was removed, bleeding stopped, and the chest tube insertion site healed spontaneously.
- In the comparison of the expanded lung of a live patient with the partially expanded

lung of a cadaver, the distances from the distal end of the chest tube to the measured structures should be different in the two cases; however, the distances from the distal end of the chest tube to the fixed structures of the mediastinum (subclavian vessels, aorta, and azygos vein) should be similar in the live patient and in the cadaver

- The extent to which the chest tube penetrates into the lung was not measured (although, in all cases, the distal end of the chest tube partially penetrated into or touched the anterior segments of the upper lobes); nor was the severity of structural damage in the drained parenchyma assessed, because, in order to do so, it would be necessary to use another study model: explantation of a lung, which would be connected to a respirator in order to remain expanded, followed by microscopic analysis of the lesion in the drained lung
- For analysis of data correlation, all of the variables were cross-referenced in order to detect a pattern. In general, it was found that a greater distance from the chest tube to the main bronchi translated to a greater distance from the chest tube to the other mediastinal structures. An interesting finding is that there was a positive relationship between weight and the left phrenic nerve, i.e., higher weight translated to a more medial position of the chest tube, i.e., on the left, drainage occurs closer to the heart in obese patients.
- The correlation analysis also showed that chest wall thickness does not correlate with weight or height. Therefore, a fixed-sized chest tube can be used regardless of the anthropometric characteristics of the patients, given that chest wall thickness does not correlate with these variables.

The placement of a fixed-size chest tube in the position specified in the clinical protocol makes pulmonary drainage feasible and safe, regardless of the anthropometric characteristics of the patients, given that the chest tube in this position caused no injury to the structures studied.

References

1. Coimbra I, Guimarães M. Doença pulmonar obstrutiva crônica. In: Pessoa FP, editor. *Pneumologia clínica e cirúrgica*. São Paulo: Atheneu; 2001. p. 309-19.

2. Botter M, Saad Jr R, Botter DA, Rivabem JH, Gonçalves R, Dorgan Neto V. Surgical treatment of giant emphysematous lung bullae [Article in Portuguese]. *Rev Assoc Med Bras.* 2007;53(3):217-21. PMID:17702120. <http://dx.doi.org/10.1590/S0104-42302007000300018>
3. Bueno MA, Romaldini H. Cirurgia redutora de enfisema. *J Pneumol.* 1997;23(5):252-60.
4. Botter M, Saad Jr R. Transplante pulmonar: o estado da arte. In: Saad Jr R, Carvalho WR, Ximenes Netto M, Forte V, editors. *Cirurgia torácica geral.* São Paulo: Atheneu; 2005. p. 499-530.
5. Mora JI, Hadjiliadis D. Lung volume reduction surgery and lung transplantation in chronic obstructive pulmonary disease. *Int J Chron Obstruct Pulmon Dis.* 2008;3(4):629-35. PMID:19281079 PMCid:2650594.
6. Trench NF, Telles FC. Fisiopatologia da distensão das grandes bolhas de enfisema. *Arq Hosp Santa Casa S Paulo.* 1956;2(1):87-108.
7. Venn GE, Williams PR, Goldstraw P. Intracavity drainage for bullous, emphysematous lung disease: experience with the Brompton technique. *Thorax.* 1988;43(12):998-1002. PMID:3238643 PMCid:461614. <http://dx.doi.org/10.1136/thx.43.12.998>
8. Monaldi V. Tentativi di aspirazione endocavitaria nelle caverne tubercolari del pulmone. *Lotta Tuberc.* 1938;9:910-1.
9. Saad R Jr, Dorgan Neto V, Botter M, Stirbulov R, Rivaben J, Gonçalves R. Therapeutic application of collateral ventilation in diffuse pulmonary emphysema: study protocol presentation. *J Bras Pneumol.* 2008;34(6):430-4. <http://dx.doi.org/10.1590/S1806-37132008000600015>
10. Saad Junior R, Dorgan Neto V, Botter M, Stirbulov R, Rivaben JH, Gonçalves R. Therapeutic application of collateral ventilation with pulmonary drainage in the treatment of diffuse emphysema: report of the first three cases. *J Bras Pneumol.* 2009;35(1):14-9. PMID:19219326.
11. De Bussab W, Morettin PA. *Estatística básica.* São Paulo: Saraiva; 2008.
12. Massad E, Menezes RX, Silveira PS, Ortega NR. *Métodos quantitativos em medicina.* Barueri: Manole; 2004.
13. Macklem PT. Collateral ventilation. *N Engl J Med.* 1978;298(1):49-50. PMID:618452. <http://dx.doi.org/10.1056/NEJM197801052980112>
14. Saad Jr R. Broncostomia: uma opção operatória. In: Saad Jr R, Carvalho WR, Ximenes Netto M, Forte V, editors. *Cirurgia torácica geral.* São Paulo: Editora Atheneu; 2011. p. 603-7

About the authors

Júlio Mott Ancona Lopez

Attending Physician. *Irmandade da Santa Casa de Misericórdia de São Paulo*, São Paulo, Brazil.

Roberto Saad Jr

Full Professor. *Santa Casa de São Paulo School of Medical Sciences*, São Paulo, Brazil.

Vicente Dorgan Neto

Adjunct Professor. *Santa Casa de São Paulo School of Medical Sciences*, São Paulo, Brazil.

Marcio Botter

Assistant Professor. *Santa Casa de São Paulo School of Medical Sciences*, São Paulo, Brazil.

Roberto Gonçalves

Attending Physician. *Irmandade da Santa Casa de Misericórdia de São Paulo*, São Paulo, Brazil.

Jorge Henrique Rivaben

Attending Physician. *Irmandade da Santa Casa de Misericórdia de São Paulo*, São Paulo, Brazil.