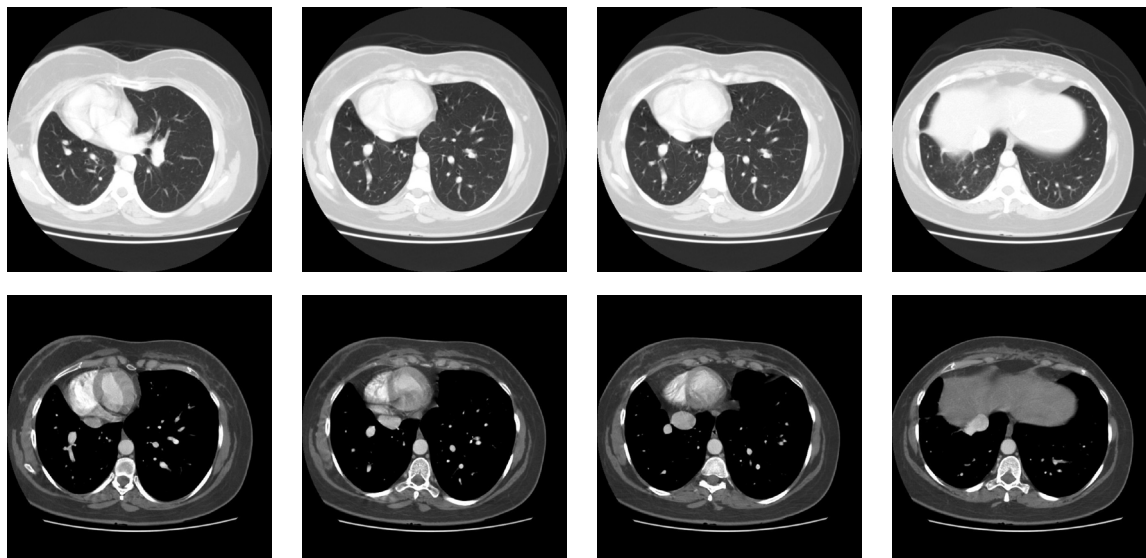
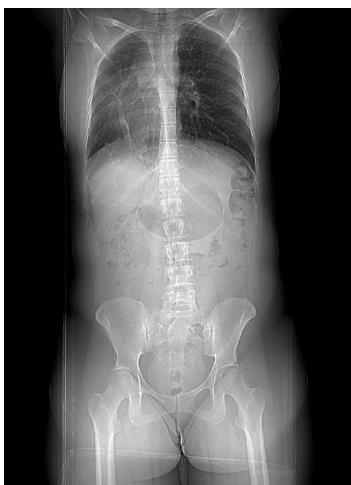

Radiological Diagnosis

Diagnosis of the case presented in the previous edition

J Bras Pneumol. 2007;33(4):492

Scimitar Syndrome



Comments

Scimitar syndrome, also known as pulmonary venolobar syndrome or hypogenetic lung syndrome, is a malformation classically characterized by the association of hypoplasia of the right lung

with anomalous pulmonary venous return (usually partial) of this lung. This anomalous vein has vertical orientation, usually draining towards the inferior cava vein (supra- or infra-diaphragmatic), and its shape resembles a scimitar. There may also be collateral aortopulmonary arteries in this syndrome,

which may cause pulmonary hypertension. Up to one-third of all cases also present congenital cardiac anomalies, such as ventricular or atrial septum defect, patent arterial duct, coarctation of the aorta and tetralogy of Fallot. In the case shown herein, the patient was asymptomatic, and this diagnosis was a test finding.

**Dany Jasinowodolinski,
Gustavo de Souza Portes Meirelles,
Nestor L Müller**

Fleury Center for Diagnostic Medicine, São Paulo, Brazil;
Universidade Federal de São Paulo – UNIFESP, Federal University of
São Paulo – São Paulo, Brazil;
University of British Columbia – Vancouver, British Columbia, Canada.

References

1. Ferguson EC, Krishnamurthy R, Oldham SA. Classic Imaging Signs of Congenital Cardiovascular Abnormalities. *Radiographics*. 2007;27(5):1323-34.
2. Zylak CJ, Eyster WR, Spizarny DL, Stone CH. Developmental lung anomalies in the adult: radiologic-pathologic correlation. *Radiographics*. 2002;22 Spec No:S25-43.
3. Woodring JH, Howard TA, Kanga JF. Congenital pulmonary venolobar syndrome revisited. *Radiographics*. 1994;14(2):349-69.
4. Kim EA, Lee KS, Johkoh T, Kim TS, Suh GY, Kwon OJ, et al. Interstitial lung diseases associated with collagen vascular diseases: radiologic and histopathologic findings. *Radiographics*. 2002;22 Spec No:S151-65.
5. Akira M, Hara H, Sakatani M. Interstitial lung disease in association with polymyositis-dermatomyositis: long-term follow-up CT evaluation in seven patients. *Radiology*. 1999;210(2):333-8.

Readers correctly diagnosing the case presented in the July/August 2007 issue:

Alfredo Nicodemos da Cruz Santana – Faculdade de Medicina da Universidade de São Paulo – São Paulo – SP
Bruno Hochhegger – Santa Casa de Porto Alegre – Porto Alegre – RS
Celso Murilo Nácio Matias de Faria – Faculdade de Medicina de São José do Rio Preto – São José do Rio Preto – SP
Cesar Augusto de Araújo Neto – Image Memorial – Salvador – BA
Christiano Perin – Hospital de Clínicas de Porto Alegre – Porto Alegre – RS
Daniel de Melo Mendes – Faculdade de Medicina da Universidade de São Paulo – São Paulo – SP
Felipe Pfuetzenreiter – Hospital Municipal São José – Joinville – SC
Humberto de Souza Pereira Barcelos – Cebrom e Clínica São Camilo – Goiânia – GO
Manuela de Abreu Viana – Vita Medicina Diagnóstica – Tubarão – SC
Paulo Márcio da Silveira Brunato Filho – Vita Medicina Diagnóstica – Tubarão – SC
Rinaldo Antunes Imolesi – Hospital de Ipanema – Rio de Janeiro – RJ
Rosane R. Martins – Hospital das Forças Armadas de Brasília – Brasília – DF
Sergio Lopes Viana – Clínica Vila Rica – Brasília – DF
Thiago Krieger Bento da Silva – Pontifícia Universidade Católica – Porto Alegre – RS
Winston Hidekazu Akashi Iwauchi – Universidade Estadual de Campinas – Campinas – SP