

Case Report

Multiple pulmonary metastases of benign meningioma*

ADALBERTO SPERB RUBIN, LILIANA GOMES PELLEGRIN, NELSON DA SILVA PORTO, GERALDO GEYER.

Meningiomas account for approximately one-sixth of all primary neoplasms of the central nervous system and rarely present extracranial metastases. A finding of multiple metastases is rare, as is the presence of respiratory symptoms. Herein, we report the case of a 67-year-old female patient presenting subacute onset of respiratory symptoms. The patient had undergone resection of a benign intracranial meningioma six months prior, but had no history of lung disease. Upon examination, multiple pulmonary metastases, originating from the primary tumor, were observed.

J Bras Pneumol 2005; 31(2): 177- 80.

Key words: Meningioma. Neoplasm Metastasis. Lung Neoplasms..

INTRODUCTION

Meningiomas are primary tumors of the meninges originating in the arachnoid membrane, comprising 14% to 19% of all intracranial and intraspinal tumors⁽¹⁻³⁾. This percentage may be underestimated, since asymptomatic tumors are excluded⁽⁴⁾. Nearly all neoplasms primarily affecting the meninges are meningiomas, although other types of primary tumors may occasionally been seen^(2,5). Meningiomas are considered benign neoplasms since, in general, they do not produce metastases, are rarely invasive and are typically cured through surgical resection⁽⁶⁾.

However, these tumors have the potential of becoming aggressive and invading the brain and skull, as well as of metastasizing out of the central nervous system⁽⁶⁾. Rates of local recurrence after complete resection range from 9% to 32%⁽⁶⁾, and 1:1000 of the meningiomas are assumed to metastasize^(2,6). Recurrence is more frequent in: the upper-half of the brain, convexity of the hemispheres, fold of dura mater, lesser sphenoid wing and olfactory sulcus⁽⁷⁾. Meningiomas typically appear in older individuals, being more common in women (ratio 2:1)⁽⁷⁾. The graduation system of the World Health Organization classifies tumors as

* Study carried out at the Pavilhão Pereira Filho, Santa Casa de Porto Alegre, Fundação Faculdade Federal de Ciências Médicas de Porto Alegre (FFFCMPA).

Address to: Adalberto Sperb Rubin. Rua Almirante Abreu 246/402 CEP 90420010

Porto Alegre - RS - Brasil. E-mail: arubin@terra.com.br

Submitted: 12 April 2004. Accepted, after revision: 14 September 2004.

typical or benign and atypical or malignant, according to cellularity, mitosis, necrosis and brain invasion^(7,8). Approximately 3% of benign meningiomas and 78% of atypical tumors recur within five years. Malignant meningiomas are rare, with an incidence ranging from 2% to 10%⁽⁹⁾. Due to the slow progress of the meningiomas and the favorable prognosis after resection, surgery is the treatment of choice⁽⁶⁾.

Herein, we report a case of meningioma presenting pulmonary metastases diagnosed six months after resection of a tumor mass that was located in the left temporal lobe.

CASE REPORT

A 67-year-old white female patient (housewife) sought medical attention after experiencing dry cough, wheezing and prostration, together with dyspnea upon maximum exertion, for four months. The patient had been treated with bronchodilators for two weeks with no clinical improvement. No history of smoking or previous pulmonary disease was reported and, six months prior, the patient had been submitted to resection of fibroblastic meningioma of the left temporal region. Tomography revealed an intracranial tumor at the original (temporal lobe) site of the primary lesion (Figure 1), probably related to local recurrence of the lesion.

Simple radiogram of the thorax presented diffuse reticulonodular interstitial infiltrate. High-resolution computed tomography of the thorax (Figure 2) revealed micronodules disseminated through both lungs. Laboratory exams were normal. Pulmonary function evaluation presented the following values (and percents of predicted): forced vital capacity of 2.0 L (86%), forced expiratory volume in the first second of 1.62 L (98%), total lung capacity of 3.34 L (87%), current volume of 1.10 L (73%) and diffusing capacity for carbon monoxide of 10.18 mL/min (61%). Fiberoptic bronchoscopy with bronchiolar lavage and transbronchial biopsy was conducted, with no definitive diagnosis. The patient was then submitted to open-lung biopsy, in which wedge fragments were taken from the medial lobe and lower right lobe. The anatomopathological results showed multiple foci of interstitial proliferation of fusiform and oval cells of meningothelial aspect (Figure 3). This result

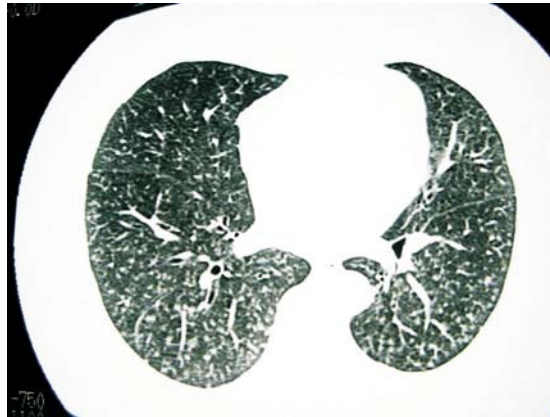

Figure 1. Computed tomography scan of the head, presenting recurrent meningioma in the left temporal lobe

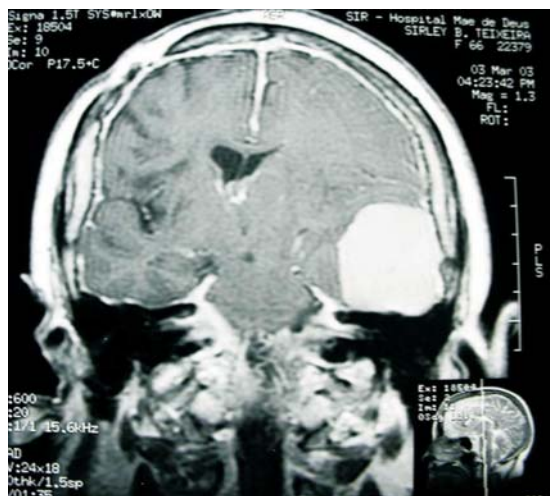


Figure 2. High-resolution computed tomography showing bilateral diffuse micronodules consistent with metastasis

presented similarity with the tumor resected from the left temporal region of the central nervous system, the anatomopathological examination of which showed a fibroblastic meningioma. Regarding the pulmonary metastases of the meningioma, the treatment offered to the patient was anticipatory, involving symptom management and outpatient follow-up treatment.

DISCUSSION

Metastases of meningiomas are rare, with an estimated incidence of approximately 1:1000^(2,6) cases. These tumors typically grow slowly and are therefore considered benign⁽⁶⁾. Metastatic lesions

are also normally of a benign nature⁽⁶⁾. Metastases occur most frequently in the lungs (60%), the liver (34%), cervical lymph nodes (18%), long bones, pelvis and skull (11%), pleura (9%), vertebrae (7%) and central nervous system (5%)^(6,9).

Hematogenic dissemination may explain the incidence of pulmonary metastases⁽⁹⁾. A review of the literature indicates that previous craniotomy, invasion of venous sinuses, local recurrence, histological malignancy and papillary morphology may be risk factors for systemic expansion⁽⁶⁾. It has been more frequently suggested that the occurrence of metastases are due to local recurrence of the tumor after resection⁽⁹⁾. In the case of our patient, although she was submitted to resection of the intracranial tumor, recurrence of the meningioma was observed immediately after surgery, which is a risk factor for the occurrence of metastases. In a Mayo Clinic report, three cases (0.15%) of extracranial metastases were documented between 1972 and 1994. Most patients with metastases of meningiomas are adults between 40 and 60 years of age⁽⁹⁾. Pulmonary metastases are rarely accompanied by local symptoms⁽⁹⁾.

Pulmonary metastases from meningiomas typically present as a single lesion, or, less frequently, as multiple noncalcified nodules of different sizes⁽⁹⁾, which makes the present case even more rare. The presence of respiratory symptoms in our patient may be explained by the extent of the pulmonary involvement, since our patient presented a restrictive functional profile, as well as a significant change in measurement of pulmonary diffusing capacity for carbon monoxide and no concomitance with another respiratory disease.

It is estimated that the interval between the detection of the primary tumor and the detection of the first metastasis is 6.4 years and can reach 24 years⁽⁹⁾. Median survival rates after diagnosis of the primary tumor vary greatly, ranging from 14 days to 24 years^(6,9), with an average of 7.3 years⁽⁹⁾. In our patient, the diagnosis was made immediately after the primary lesion was found, indicating that the metastases were older, although there had been no previous diagnosis.

Complete resection is the treatment of choice for meningiomas. Nevertheless, postoperative radiotherapy has been recommended for the

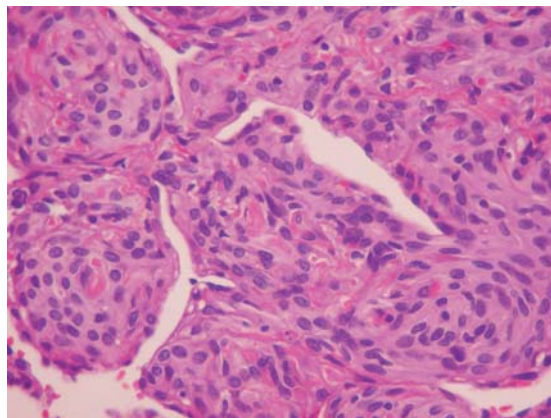


Figure 3. Anatomopathological exam of meningotheelial lung nodes

prevention of local recurrence^(3,10), especially when resection is partial or when histology suggests malignancy⁽¹⁰⁾. The efficacy of chemotherapy for intracranial meningioma is supposedly low, since no satisfactory results have been shown for isolated cases^(3,10).

Several studies have demonstrated a correlation between high expression of progesterone receptors and lower histological level, low recurrence frequency and better prognosis. However, such expression may not be considered an independent prognostic marker⁽³⁾.

Some authors have confirmed the quantitative expression of progesterone receptors in studies involving a variety of meningioma cases, thereby suggesting that it is possible to conduct clinical trials with antiprogestosterone therapy⁽¹⁰⁾.

Although many meningiomas have a good prognosis after treatment, there is still great controversy regarding the best means of management, which requires an understanding of the risks and benefits of radiotherapy and surgical treatment, as well as of the potential long-term risks⁽³⁾. In fact, no treatment regimen has been established for metastases of meningiomas⁽⁹⁾. Similarly, the performance of radiotherapy still needs to be more clearly defined⁽⁹⁾.

To conclude, the presence of multiple pulmonary lesions (micronodules), such as in this case or in isolated cases, in patients with meningiomas (resected or not), should serve as a

guide for those treating intrapulmonary metastases from meningiomas. The significance of these micronodules in the evolution and prognosis of the disease, as well as in determining treatment options, remains to be clarified.

REFERENCES

1. Jhavar BS, Fuchs CS, Colditz GA, Stampfer MJ. Sex steroid hormone exposures and risk for meningioma. *J Neurosurg* 2003;99:848-53.
2. Balmaceda CM, Sisti MB, Bruce JN. Tumores das Meninges. In: Rowland LP, Merritt HH. *Tratado de Neurologia*. 10ª ed. Rio de Janeiro: Guanabara Koogan, 2002;267-73.
3. Whittle IR, Smith C, Navoo P, Colle D. Meningiomas. *Lancet* 2004;363:1535-41.
4. Ramakrishnamurthy TV, Murty AV, Purohit AK, Sundaram C. Bening meningioma metastasizing through CSF pathway a case report and review of literature. *Neurol* 2002;50:326-9.
5. Girolami U, Frosch M, Anthony D. The Central Nervous System. In: Cotran RS, Kumar V, Robbins SL, editors. *Robbins Pathologic Basis Of Disease*. 6th ed. Philadelphia: Saunders Company, 1999;1295-1356.
6. Pramesh CS, Saklani AP, Pantvaidya GH, Herron AA, Naresh KN, Sharma S, et al. Bening Metastasizing Meningioma. *Jpn J Clin Oncol* 2003;33:86-8.
7. Mihaila D, Jankowski M, Gutierrez JA. Meningiomas: analysis of loss of heterozygosity on chromosome 10 in tumor progression and the delineation of four regions of chromosomal deletion in common with other cancers. *Clin Cancer Res* 2003;9: 4435-42.
8. Chen NF, Lin GY, Wang YC, Leu CH, Kwan PC. Intraventricular malignant meningioma: one case report. *J Clin Neurosci* 2003;10:616-20.
9. Adlakha A, Rao K, Adlakha H, Perry A, Crotty TB, Scheithauer BW, et al. Meningioma Metastatic to the lung. *Mayo Clin Proc* 1999;74:1129-1133.
10. Wolfsberger S, Doostkam S, Boecher-Schwarz HG, Roessler K, van Trotsenburg M, Knosp E, et al. Progesterone-receptor index meningiomas: correlation with clinico-pathological parameters and review of the literature. *Neurosurg Rev* 2004;27:238-45.