

Case Report

Bird fancier's lung complicated by pulmonary nocardiosis^{*,**}

Pulmão dos criadores de aves complicado por nocardiose pulmonar

Kosaku Komiya, Hiroshi Ishii, Tetsuo Tsubone,
Eiji Okabe, Bunroku Matsumoto, Jun-ichi Kadota

Abstract

We report the case of an 84-year-old male who was admitted to the hospital with persistent cough and dyspnea. An initial chest X-ray revealed pulmonary infiltrates. *Nocardia asteroides* was detected in sputum, and the patient was treated with antibiotics. However, his symptoms did not completely resolve. He was admitted multiple times, and his symptoms relapsed after every discharge. He was finally suspected of having hypersensitivity pneumonitis and was diagnosed with bird fancier's lung. Pulmonary nocardiosis is likely to develop in patients with chronic pulmonary disorders, such as COPD, as well as in immunosuppressed hosts. To our knowledge, this is the first report of a case of bird fancier's lung complicated by pulmonary nocardiosis.

Keywords: Respiratory hypersensitivity; Bird fancier's lung; *Nocardia asteroides*; Alveolitis, extrinsic allergic.

Resumo

Relatamos o caso de um paciente de 84 anos que foi hospitalizado devido a tosse persistente e dispneia. A radiografia de tórax inicial revelou infiltrados pulmonares. *Nocardia asteroides* foi detectada no escarro, e o paciente foi tratado com antibióticos; entretanto, seus sintomas não melhoraram por completo. O paciente foi hospitalizado várias vezes, e os sintomas reapareceram após cada alta. Houve a suspeita de pneumonite de hipersensibilidade, sendo o paciente diagnosticado com pulmão dos criadores de aves. É provável que a nocardiose pulmonar se desenvolva em pacientes com doenças pulmonares crônicas, como DPOC, e em hospedeiros imunossuprimidos. Até onde sabemos, este é o primeiro relato de um caso de pulmão dos criadores de aves complicado por nocardiose pulmonar.

Descritores: Hipersensibilidade respiratória; Pulmão dos criadores de aves; *Nocardia asteroides*; Alveolite alérgica extrínseca.

Introduction

Bird fancier's lung is a form of hypersensitivity pneumonitis that can progress to irreversible structural lung abnormalities and radiological findings consistent with pulmonary fibrosis, and occasionally emphysema.⁽¹⁻³⁾ Pulmonary nocardiosis often develops in patients with chronic pulmonary disorders, such as COPD, as well as in immunosuppressed hosts.⁽⁴⁻⁶⁾ To our knowledge, this is the first report of a case of bird fancier's lung complicated by pulmonary nocardiosis.

Case report

An 84-year-old Japanese male, without any history of smoking or underlying diseases,

including pulmonary disorders, visited a clinic in April of 2010 because of persistent dry cough and dyspnea for three months. The initial chest X-ray revealed multiple ground-glass attenuation and infiltrates, and he was suspected of having pulmonary tuberculosis. Although he was subsequently admitted to a tuberculosis hospital, no AFB was detected in his sputum, and his symptoms improved within two days after admission, without the use of any medications. However, his symptoms relapsed one week after discharge. The patient was given 500 mg/day of levofloxacin for one week because *Nocardia asteroides* was first detected in long-term culture of his sputum. However, his symptoms did not

* Study carried out in the Department of Internal Medicine 2, Oita University Faculty of Medicine, Yufu, Japan, and in Tenshindo Hetsugi Hospital, Oita, Japan.

Correspondence to: Hiroshi Ishii. 1-1 Idaigaoka, Yufu, Oita, Japan 879-5593.

Tel. 81 97 549-4411. Fax: 81 97 549-4245. E-mail: hishii@oita-u.ac.jp

Financial support: None.

Submitted: 17 February 2012. Accepted, after review: 7 May 2012.

**A versão completa em português deste artigo está disponível em www.jornaldepneumologia.com.br

resolve completely, and he was therefore referred to our hospital in July of 2011.

A physical examination on admission revealed a body temperature of 36.5°C, an SpO₂ of 96%, a blood pressure of 133/81 mmHg, and an HR of 74 bpm. Mild crackles were detected bilaterally on chest auscultation. Laboratory tests revealed a normal leukocyte count (8,020 cells/ μ L) and elevated serum levels of C-reactive protein (4.94 mg/dL) and KL-6 (644 U/mL) by electrochemiluminescence immunoassay (Picolumi KL-6 kit; Eidia, Tokyo, Japan). The arterial blood gas analysis was within the normal range (pH, 7.468; PaO₂, 90.0 Torr; PaCO₂, 36.2 Torr; and bicarbonate, 23.5 mmol/L). An indirect test for *Mycobacterium tuberculosis* complex (QuantiFERON®-TB Gold; Cellestis, Ltd., Carnegie, Victoria, Australia) was negative. Respiratory function tests showed a VC of 1.90 L (68.3% of predicted). A chest X-ray taken at admission (Figure 1A) was virtually unchanged when compared with the one taken at the tuberculosis hospital. Figure 2A shows an HRCT scan demonstrating multifocal airspace consolidation, traction bronchiectasis, ground-glass attenuation, and pleural irregularities. Sputum was collected on admission to our hospital, and the culture revealed *Nocardia* sp, the patient being treated with 3 g/day of i.v. meropenem for two weeks, followed by daily administrations of 1,600 mg/day of sulfamethoxazole and 320 mg/day of trimethoprim. His symptoms gradually disappeared within three days thereafter, and he did not relapse until after being discharged from the hospital.

One week later, however, the patient returned to the hospital due to recurrent dry cough and dyspnea and was finally suspected to have hypersensitivity pneumonitis caused by his living environment. An in-depth history demonstrated that he had been raising approximately twenty chickens for 20 years. He had not noticed any respiratory symptoms at all until those series of episodes. He promptly recovered without any treatment after that last admission; his home had been scheduled to be rebuilt at that time. Consequently, he decided to stay at the hospital to avoid any exposure to the chickens or other antigens until the completion of the home renovation. However, the family of the patient unexpectedly came to the hospital to see him just after the chicken shed had been cleaned

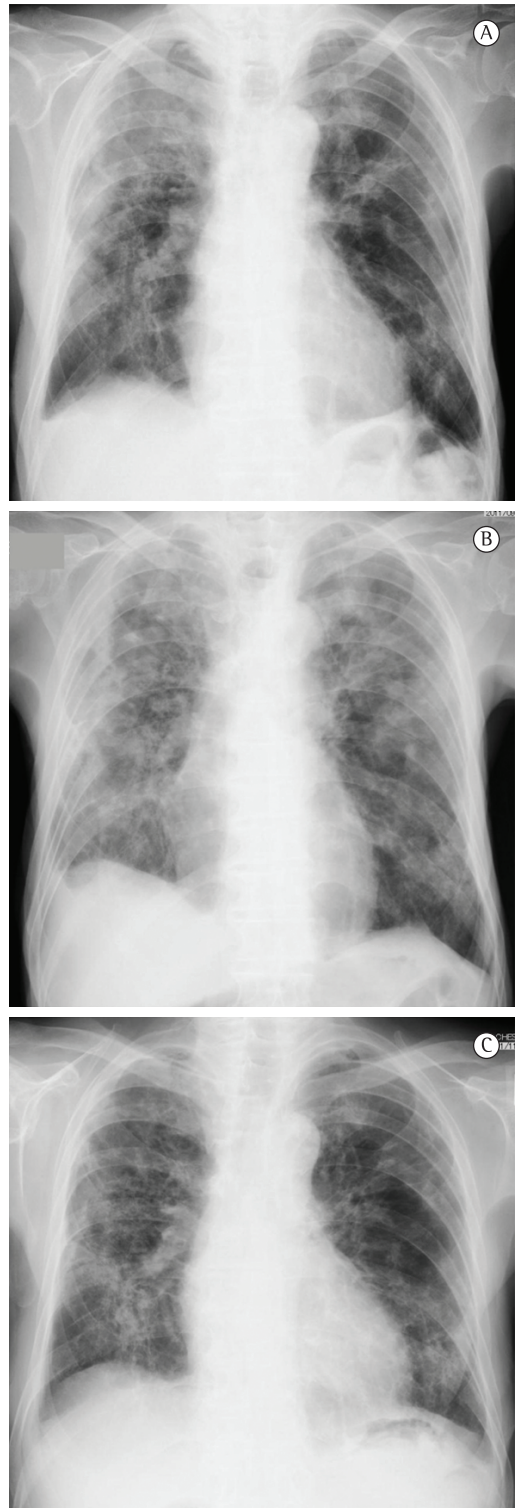

Figure 1 – Chest X-rays showing multiple ground-glass attenuation at admission (in A); just after the family's visit (in B), when the symptoms all worsened; and two months after the treatment with glucocorticoids and sulfamethoxazole-trimethoprim (in C), when the symptoms had improved.

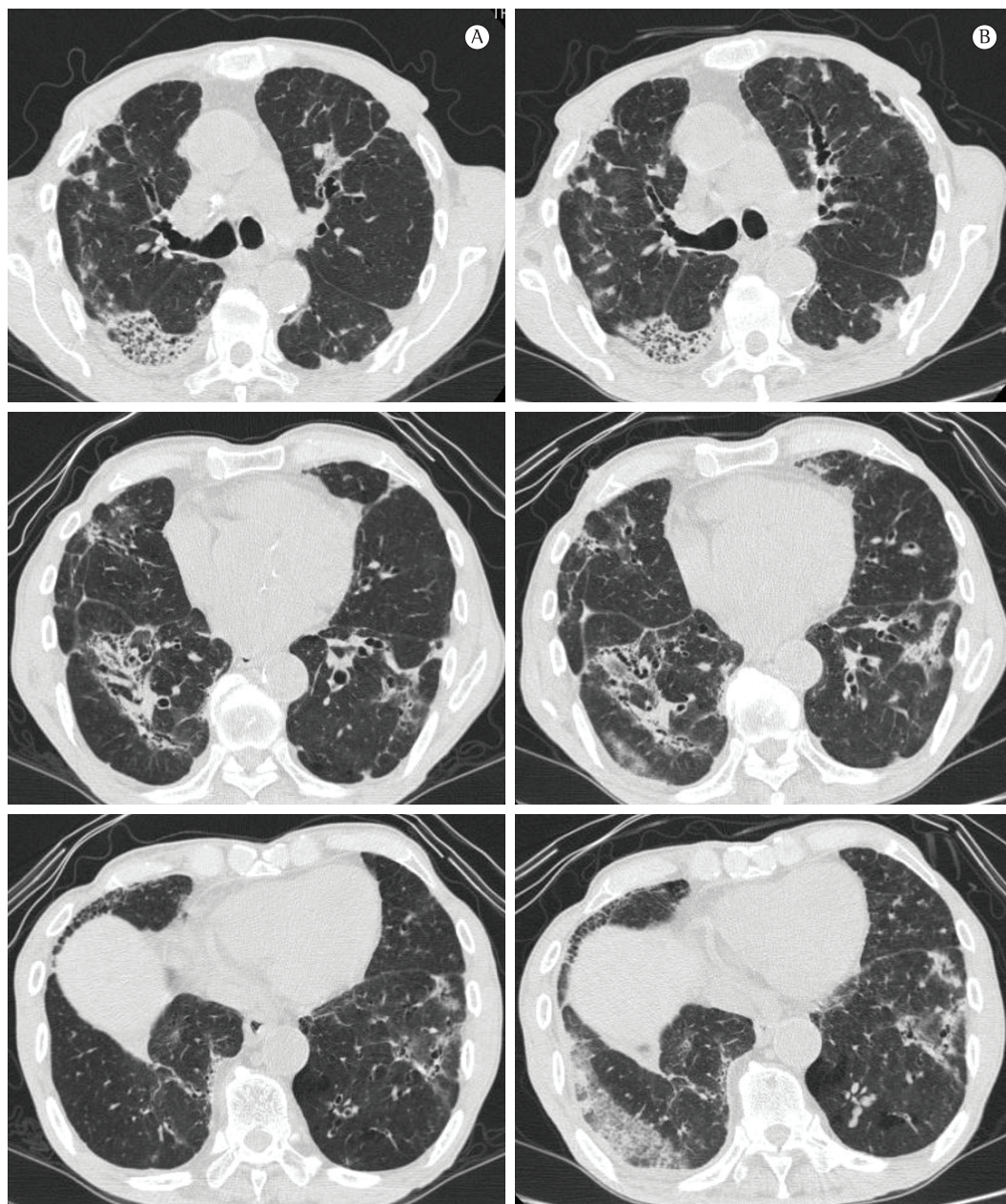


Figure 2 – HRCT scans of the chest showing multifocal, small, ill-defined opacities, traction bronchiectasis, ground-glass attenuation, and pleural irregularities at admission (in A), and expansions of the small, ill-defined opacities, ground-glass attenuation, and pleural irregularities just after the family's visit (in B).

up. A few hours later, the patient complained of cough and dyspnea, followed by pyrexia and hypoxia. A chest X-ray (Figure 1B) and HRCT scans (Figure 2B) showed new or expanding ground-glass attenuation in both lower lobes, despite a partial improvement of the small, ill-defined peribronchial opacities. Transbronchial washing by bronchoscopy showed no evidence of infection,

including nocardiosis. Transbronchial lung biopsy and BAL were not performed because of the poor respiratory status of the patient. Although serum antibodies of *Trichosporon asahii* and pigeon dropping extract (PDE) IgG (optical density of 0.194 in ELISA) were negative, serum PDE IgA antibody (optical density of 0.123 in ELISA) was positive. We therefore made a diagnosis of bird

fancier's lung (hypersensitivity pneumonitis) on the basis of the clinical findings, in accordance with recommended diagnostic criteria.⁽⁷⁾ The patient received steroid pulse therapy (1,000 mg/day of methylprednisolone for three days), followed by maintenance therapy with low dose prednisolone and instructions to avoid exposure to bird-related antigens. His symptoms and the infiltrates on the chest X-rays gradually diminished (Figure 1C). At this writing, there was no evidence of relapse after treatment with 2 g/day of sulfamethoxazole-trimethoprim and 10 mg/day of prednisolone.

Discussion

The present report presented a case of bird fancier's lung complicated by *N. asteroides* infection, in which the diagnosis of hypersensitivity pneumonitis was delayed because of the prior detection of *Nocardia* sp. in sputum.

Although COPD is a frequent predisposing factor to *Nocardia* sp. infection,^(8,9) the present case showed hypersensitivity pneumonitis as the preexisting lung disease. In addition, pulmonary nocardiosis is thought to develop in susceptible individuals with cell-mediated immune deficiency, according to an epidemiological study that showed that various patients with nocardiosis were infected with HIV.⁽⁴⁾ Hypersensitivity pneumonitis results from type III and IV allergic reactions to inhaled antigens,⁽¹⁰⁾ and it is therefore unlikely that the immune status of patients with hypersensitivity pneumonitis directly influences susceptibility to *Nocardia* spp. The structural distortions of lung parenchyma in hypersensitivity pneumonitis, as well as those in emphysema, rather than the immune status, might facilitate an infection by *Nocardia* sp.

The CT findings of pulmonary nocardiosis include lobar or multifocal airspace consolidations or masses.^(8,11) The radiological images of the present case showed multifocal, small, ill-defined opacities and pleural irregularities, which were presumably consistent with those in nocardiosis, as well as traction bronchiectasis and ground-glass attenuation, which reflected chronic hypersensitivity pneumonitis.⁽¹²⁾ However, it is difficult to clearly distinguish the multifocal, small, ill-defined opacities caused by the *Nocardia* infection from those caused by chronic hypersensitivity pneumonitis, because they can be found in both conditions. Considering the time course of the radiological findings (from the first

visit to our hospital to the acute exacerbation after treatment with sulfamethoxazole-trimethoprim), the partially decreased small peribronchial opacities (Figure 2B) could have been caused by the *Nocardia* infection, and the increased airspace consolidation with ground-glass attenuation might have been influenced by hypersensitivity pneumonitis. There seemed to be a mixture of the two different diseases, although we were unable to perform a lung biopsy. The patient had been unaware of any respiratory symptoms until the beginning of those episodes, although he had been raising chickens for a long time. The initial respiratory symptoms seemed to be principally due to the *Nocardia* infection and they might have been followed by the exacerbation of hypersensitivity pneumonitis.

The diagnostic precision of bird fancier's lung was an important consideration concerning the present case. Acute exacerbation after the first discharge from the hospital could be a clue to the onset of hypersensitivity pneumonitis caused by a specific living environment. The second acute exacerbation after his family's visit became a clue to diagnosing bird fancier's lung (hypersensitivity pneumonitis). The use of provocation tests in true patients induces their symptoms, such as fever, within a few hours, and these tests have a high predictive value,^(2,3,13) which is consistent with the present case. The gold standard for the diagnosis of bird fancier's lung has yet to be established. Control groups that do not have pulmonary disorders sometimes reveal high serum levels of PDE IgG, and the positive odds ratio for diagnosis using this antibody is less than is that obtained using provocation tests.⁽³⁾ Therefore, one group of authors set the positive finding of PDE IgG as a selective item in the diagnostic criteria.⁽⁷⁾ The present case was positive because of the unexpected results on the provocation test and was consistent with various of the recommended diagnostic criteria,^(3,7,14) which include the following items: a history of symptoms that appeared or worsened within hours after antigen exposure, positive results for natural challenge, confirmation of exposure to the offending agent based on the patient history, positive precipitating antibodies, lymphocytosis in BAL fluid (if BAL performed), and compatible histological changes (if histology performed). In the present case, the serum PDE IgA antibody titer was positive, but that to IgG was negative;

however, IgA antibodies do not always increase upon acute exacerbation, and no clear mechanism underlying the development of these antibodies has been identified.⁽¹⁵⁾

In conclusion, we have presented a case of bird fancier's lung complicated by pulmonary nocardiosis. It is important to correctly evaluate preexisting lung disease at an early time point, if *Nocardia* sp. is detected in patient specimens.

Acknowledgments

We would like to thank Dr. Y. Yoshizawa (Tokyo Medical and Dental University) for measuring serum antibodies against PDE; Dr. K. Umeki, M. Ohama, T. Iwashita, and H. Miyajima (Tenshindo Hetsugi Hospital) for their advice; and T. Misago, T. Eto, and Y. Watanabe (Tenshindo Hetsugi Hospital) for their technical assistance in the laboratory office.

References

1. McSharry C, Anderson K, Boyd G. A review of antigen diversity causing lung disease among pigeon breeders. *Clin Exp Allergy*. 2000;30(9):1221-9. PMID:10971467. <http://dx.doi.org/10.1046/j.1365-2222.2000.00810.x>
2. Morell F, Roger A, Reyes L, Cruz MJ, Murio C, Muñoz X. Bird fancier's lung: a series of 86 patients. *Medicine (Baltimore)*. 2008;87(2):110-30. PMID:18344808. <http://dx.doi.org/10.1097/MD.0b013e31816d1dda>
3. Lacasse Y, Selman M, Costabel U, Dalphin JC, Ando M, Morell F, et al. Clinical diagnosis of hypersensitivity pneumonitis. *Am J Respir Crit Care Med*. 2003;168(8):952-8. PMID:12842854. <http://dx.doi.org/10.1164/rccm.200301-1370C>
4. Martínez Tomás R, Menéndez Villanueva R, Reyes Calzada S, Santos Durantez M, Vallés Tarazona JM, Modesto Alapont M, et al. Pulmonary nocardiosis: risk factors and outcomes. *Respirology*. 2007;12(3):394-400. PMID:17539844. <http://dx.doi.org/10.1111/j.1440-1843.2007.01078.x>
5. Aidê MA, Lourenço SS, Marchiori E, Zanetti G, Mondino PJ. Pulmonary nocardiosis in a patient with chronic obstructive pulmonary disease and bronchiectasis. *J Bras Pneumol*. 2008;34(11):985-8. PMID:19099108. <http://dx.doi.org/10.1590/S1806-37132008001100016>
6. Baldi BG, Santana AN, Takagaki TY. Pulmonary and cutaneous nocardiosis in a patient treated with corticosteroids. *J Bras Pneumol*. 2006;32(6):592-5. PMID:17435912. <http://dx.doi.org/10.1590/S1806-37132006000600019>
7. Yoshizawa Y, Ohtani Y, Hayakawa H, Sato A, Suga M, Ando M. Chronic hypersensitivity pneumonitis in Japan: a nationwide epidemiologic survey. *J Allergy Clin Immunol*. 1999;103(2 Pt 1):315-20. [http://dx.doi.org/10.1016/S0091-6749\(99\)70507-5](http://dx.doi.org/10.1016/S0091-6749(99)70507-5)
8. Menéndez R, Cordero PJ, Santos M, Gobernado M, Marco V. Pulmonary infection with *Nocardia* species: a report of 10 cases and review. *Eur Respir J*. 1997;10(7):1542-6. PMID:9230244. <http://dx.doi.org/10.1183/09031936.97.10071542>
9. Mari B, Montón C, Mariscal D, Luján M, Sala M, Domingo C. Pulmonary nocardiosis: clinical experience in ten cases. *Respiration*. 2001;68(4):382-8. PMID:11464085. <http://dx.doi.org/10.1159/000050531>
10. Patel AM, Ryu JH, Reed CE. Hypersensitivity pneumonitis: current concepts and future questions. *J Allergy Clin Immunol*. 2001;108(5):661-70. PMID:11692086. <http://dx.doi.org/10.1067/mai.2001.119570>
11. Kanne JP, Yandow DR, Mohammed TL, Meyer CA. CT findings of pulmonary nocardiosis. *AJR Am J Roentgenol*. 2011;197(2):W266-72. PMID:21785052. <http://dx.doi.org/10.2214/AJR.10.6208>
12. Ohtani Y, Saiki S, Kitaichi M, Usui Y, Inase N, Costabel U, et al. Chronic bird fancier's lung: histopathological and clinical correlation. An application of the 2002 ATS/ERS consensus classification of the idiopathic interstitial pneumonias. *Thorax*. 2005;60(8):665-71. PMID:16061708 PMID:1747497. <http://dx.doi.org/10.1136/thx.2004.027326>
13. Ohtani Y, Kojima K, Sumi Y, Sawada M, Inase N, Miyake S, et al. Inhalation provocation tests in chronic bird fancier's lung. *Chest*. 2000;118(5):1382-9. PMID:11083690. <http://dx.doi.org/10.1378/chest.118.5.1382>
14. Jacobs RL, Andrews CP, Coalson J. Organic antigen-induced interstitial lung disease: diagnosis and management. *Ann Allergy Asthma Immunol*. 2002;88(1):30-41. [http://dx.doi.org/10.1016/S1081-1206\(10\)63590-9](http://dx.doi.org/10.1016/S1081-1206(10)63590-9)
15. Inase N, Unoura K, Miyazaki Y, Yasui M, Yoshizawa Y. Measurement of bird specific antibody in bird-related hypersensitivity pneumonitis [Article in Japanese]. *Nihon Kokyuki Gakkai Zasshi*. 2011;49(10):717-22. PMID:22117306.

About the authors

Kosaku Komiya

Researcher. Department of Internal Medicine 2, Oita University Faculty of Medicine, Yufu, Japan.

Hiroshi Ishii

Researcher. Department of Internal Medicine 2, Oita University Faculty of Medicine, Yufu, Japan.

Tetsuo Tsubone

Clinician. Department of Internal Medicine, Tenshindo Hetsugi Hospital, Oita, Japan.

Eiji Okabe

Clinician. Department of Internal Medicine, Tenshindo Hetsugi Hospital, Oita, Japan.

Bunroku Matsumoto

Clinician. Department of Internal Medicine, Tenshindo Hetsugi Hospital, Oita, Japan.

Jun-ichi Kadota

Professor. Department of Internal Medicine 2, Oita University Faculty of Medicine, Yufu, Japan.