

Letter to the Editor

Radiation therapy in the treatment of unicentric Castleman's disease

Radioterapia no tratamento da doença de Castleman localizada

Fabiana Accioli Miranda, Victor Hugo Chiquetto Faria,
Gustavo Viani Arruda, Lucas Godoi Bernardes da Silva

To the Editor:

Castleman's disease (CD) is a lymphoproliferative disorder whose etiology is controversial. There is currently no consensus regarding the most appropriate treatment for unresectable CD. We report the case of a patient with CD and demonstrate the efficacy of radiation therapy as a treatment modality for CD.

In May of 2007, a married, 33-year-old white male driver was referred to our thoracic surgery outpatient clinic from a primary health care clinic in the city of Marília, Brazil. The patient presented with a 4-month history of dyspnea at rest (unrelated to exertion) and of anterior and posterior chest pain (burning pain). He reported dry cough and asthenia in the past few weeks. In addition, the patient reported no hoarseness, hemoptysis, nodules, or weight loss. He also reported no comorbidities other than moderate obesity (body mass index = 35 kg/m²), as well as having reported no history of smoking, alcoholism, or illicit drug use.

Physical examination revealed good general health, as well as having revealed no cervical or supraclavicular lymph node enlargement. There were no cardiopulmonary or abdominal abnormalities.

The patient was admitted for further investigation. A CT scan of the chest revealed a left perihilar mass of 68 × 52 mm in diameter (Figure 1) in the lower lobe, as well as mediastinal lymph node enlargement in the anterior paratracheal and left hilar regions. Laboratory test results were normal.

In July of 2007, the patient was referred for left lobectomy. However, it was impossible to resect the nodule, because it was in contact with the left main bronchus. Therefore, a biopsy of the nodule was the only procedure performed. The biopsy showed a lesion consisting of large lymphoid follicles, which in turn consisted of small

lymphocytes. There was concentric proliferation of endothelial cells in the central portion of the lesion, and the vascular lumen contained erythrocytes. These findings confirmed the diagnosis of CD.

Because CD is a lymphoproliferative disease of indeterminate behavior, a decision was made to treat the patient as an outpatient, follow-up evaluations being performed every 6 months at our thoracic surgery, oncology, and hematology outpatient clinic and chest CT scans being taken during the follow-up period. A CT scan of the chest showed a slight increase in lesion size (72 × 55 mm), the lesion having no clear cleavage plane with the left descending pulmonary artery and being therefore deemed unresectable. Therefore, in August of 2009, the patient was referred to the radiation therapy department for evaluation. Between October 5, 2009 and November 16, 2009, the patient underwent three-dimensional radiation therapy at a total dose of 40 Gy, delivered in 20 fractions by a 6-MV linear accelerator. In addition to the tumor mass, the affected pulmonary hilar, subcarinal, and paratracheal lymph nodes were included in the radiation therapy fields. After the radiation therapy, the patient reported for follow-up evaluation every 3-4 months, a chest

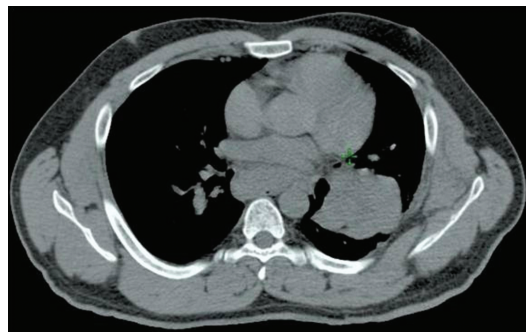


Figure 1 – Chest CT scan showing a left perihilar mass.

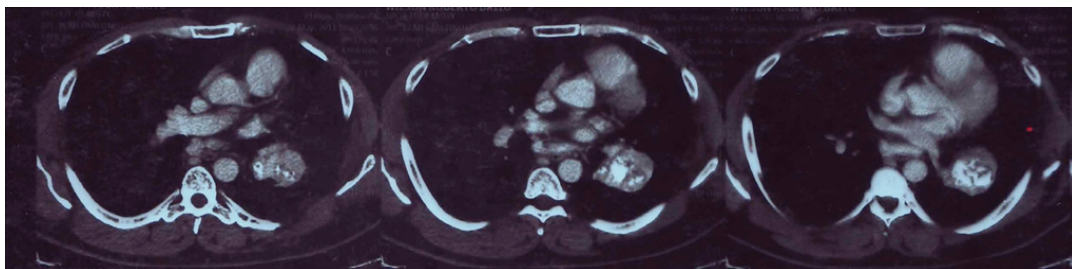


Figure 2 – From left to right, chest CT scans of the lesion at 1, 2, and 3 years of follow-up. Note an increase in the size of the calcified area within the treated lesion.

CT scan showing an approximately 25% decrease in mass size (55 × 45 mm) in comparison with that seen on the chest CT scan taken at the beginning of the treatment (Figure 2). At this writing, the patient was in good general health, his dry cough, asthenia, and chest pain having improved. His dyspnea also improved, although only relatively. After a 3-year follow-up period, echocardiography, electrocardiography, and gallium-67 scintigraphy results were normal, whereas spirometry results showed moderate restrictive lung disease, which was consistent with the degree of obesity.

It is known that CD is a rare cause of pathological proliferation of lymphoid tissue. The etiology of CD remains unknown. The disease can affect individuals of all ages. Unicentric CD occurs most frequently in adolescents and young adults, whereas multicentric CD occurs most frequently in the elderly⁽¹⁾ and in patients with immunodeficiency, particularly AIDS.

Although it is generally benign, CD can behave like a malignant disease.⁽²⁾ Clinically, the release of cytokines (TNF- α , IL-1, and IL-6) can lead to systemic manifestations of CD. Patients can present with fever, cytopenias, hepatosplenomegaly, polyclonal hypergammaglobulinemia, hepatic dysfunction, and renal dysfunction. A biopsy is required for a definitive diagnosis. However, because the pathological features of CD are similar to those of some thymomas and lymphomas, immunohistochemical studies might be needed in order to confirm the diagnosis of CD.⁽¹⁾ Of all known variants of CD, the hyaline-vascular variant appears to be the most sensitive to radiation therapy.

Because of the diversity of clinical situations and the difficulty in defining the therapeutic response retrospectively, the standard treatment has yet to be established.⁽³⁾ In patients with

multicentric CD, reducing the amount of involved tissue through surgery or radiation therapy can aid in reducing signs and symptoms,⁽⁴⁾ the treatment of multicentric CD being based on chemotherapy, corticosteroid therapy, immunomodulators, and monoclonal antibodies.⁽⁵⁾ In cases of unicentric CD, the treatment of choice is surgical excision, the recurrence rate being low. Studies have confirmed that patients with CD can be successfully treated with radiation therapy.^(6,7)

Radiation therapy can avoid the need for overly aggressive therapy and has been successfully used in patients who have unresectable lesions or who cannot undergo surgery because of the presence of comorbidities.⁽⁸⁾ Radiation therapy at doses of 2,700–4,500 cGy can result in disease remission in isolated cases, especially in patients with unicentric CD. In addition, radiation therapy can produce favorable responses, including relief of systemic symptoms and a reduction in the size of the mass.⁽⁷⁾ One group of authors⁽⁹⁾ summarized the findings in 32 CD patients undergoing radiation therapy, including those in 29 patients with unicentric CD. In those 29 patients, the overall response rate was 89.6%, the complete remission rate being 44.8% and the partial remission rate being 44.8%; the authors concluded that, in most cases, radiation therapy (at a dose of 40–50 Gy) can achieve complete or partial remission of the disease.⁽⁹⁾

Fabiana Accioli Miranda
Physician,

Marília School of Medicine,
Marília, Brazil

Victor Hugo Chiquetto Faria
Physician,

Marília School of Medicine,
Marília, Brazil

Gustavo Viani Arruda
Professor,
Department of Radiation
Therapy and Oncology,
Marília School of Medicine,
Marília, Brazil

Lucas Godoi Bernardes da Silva
Resident,
Department of Radiation Therapy,
Marília School of Medicine,
Marília, Brazil

References

1. Gidvani VK, Tyree MM, Bhowmick SK. Castleman's disease: atypical manifestation in an 11-year-old girl. *South Med J*. 2001;94(2):250-3. PMID:11235046.
2. Onishi T, Yonemura S, Sakata Y, Sugimura Y. Renal lymphoma associated with Castleman's disease. *Scand J Urol Nephrol*. 2004;38(1):90-1. PMID:15204435. <http://dx.doi.org/10.1080/00365590410026252>
3. Jongsma TE, Verburg RJ, Geelhoed-Duijvestijn PH. Castleman's disease: A rare lymphoproliferative disorder. *Eur J Intern Med*. 2007;18(2):87-9. PMID:17338958. <http://dx.doi.org/10.1016/j.ejim.2006.09.019>
4. Mendonça C, Rios E, Reis C, Santos A, Silva PS. Doença de Castleman - a propósito de um caso clínico. *Rev Soc Port Med Interna*. 2008;15(4):249-53.
5. Westphal FL, Lima LC, Santana LC, Netto JC, Amaral VC, Silva Mdos S. Castleman's disease associated with follicular dendritic cell sarcoma and myasthenia gravis. *J Bras Pneumol*. 2010;36(6):819-23. PMID:21225186. <http://dx.doi.org/10.1590/S1806-37132010000600020>
6. Li YM, Liu PH, Zhang YH, Xia HS, Li LL, Qu YM, et al. Radiotherapy of unicentric mediastinal Castleman's disease. *Chin J Cancer*. 2011;30(5):351-6. <http://dx.doi.org/10.5732/cjc.010.10402>
7. Chronowski GM, Ha CS, Wilder RB, Cabanillas F, Manning J, Cox JD. Treatment of unicentric and multicentric Castleman disease and the role of radiotherapy. *Cancer*. 2001;92(3):670-6. [http://dx.doi.org/10.1002/1097-0142\(20010801\)92:3<670::AID-CNCR1369>3.0.CO;2-Q](http://dx.doi.org/10.1002/1097-0142(20010801)92:3<670::AID-CNCR1369>3.0.CO;2-Q)
8. Bowne WB, Lewis JJ, Filippa DA, Niesvizky R, Brooks AD, Burt ME, et al. The management of unicentric and multicentric Castleman's disease: a report of 16 cases and a review of the literature. *Cancer*. 1999;85(3):706-17. [http://dx.doi.org/10.1002/\(SICI\)1097-0142\(19990201\)85:3<706::AID-CNCR21>3.0.CO;2-7](http://dx.doi.org/10.1002/(SICI)1097-0142(19990201)85:3<706::AID-CNCR21>3.0.CO;2-7)
9. de Vries IA, van Acht MM, Demeyere T, Lybeert ML, de Zoete JP, Nieuwenhuijzen GA. Neoadjuvant radiotherapy of primary irresectable unicentric Castleman's disease: a case report and review of the literature. *Radiat Oncol*. 2010;5:7. PMID:20122250 PMID:2827478. <http://dx.doi.org/10.1186/1748-717X-5-7>