

## Case Report

---

# Hidradenitis suppurativa: literature review and case report

Mônica Mourthé de Alvim Andrade<sup>1</sup>, José Roberto Monteiro Constantino<sup>2</sup>, Daniel Martins Barbosa M. Gomes<sup>1</sup>, Flávia Fontes Faria<sup>1</sup>, Rodrigo Guimarães Oliveira<sup>1</sup>, Renata Magali R. Silluzio Ferreira<sup>2</sup>, Geraldo Magela Gomes da Cruz<sup>3</sup>

<sup>1</sup>Attending postgraduate program in Coloproctology at Faculdade de Ciências Médicas de Minas Gerais (FCMMG) – Belo Horizonte (MG), Brazil. <sup>2</sup>Assistants of the Group of Coloproctology (GCP), Santa Casa de Belo Horizonte (SCBH) – Belo Horizonte (MG), Brazil. <sup>3</sup>Coordinator of the GCP-SCBH – Belo Horizonte (MG), Brazil.

---

Andrade MMA, Constantino JRM, Gomes DMBM, Faria FF, Oliveira RG, Ferreira RMRS, Cruz GMG. Hidradenitis suppurativa: literature review and case report. *J Coloproctol*, 2012;32(2): 196-201.

**ABSTRACT:** Hidradenitis suppurativa (HS) is a chronic, recurrent and debilitating disease, affecting mainly women, especially in their second and third decades of life. Its most common incidence is in the axillary, inguinal, perianal and inframammary regions. Its complications include chronic fistulizing processes, with involvement of important adjacent structures, such as the sacrum and coccyx, the anal sphincter, urethra and great-caliber vessels, such as the groin vessels. The proportions of some cases of HS requiring extensive surgical procedures at several moments and the application of flaps and grafts, justify unusual cases reports, like this one. The authors present a case of extensive involvement of the perianal and gluteal regions, which required extended resection with flap in the first approach and fistulectomy in a second surgical moment, with good result for the patient.

**Keywords:** hidradenitis suppurativa; buttocks; surgical flaps.

**RESUMO:** A hidradenite supurativa (HS) é uma doença crônica, recorrente e debilitante, que afeta principalmente mulheres, sobretudo na segunda e terceira décadas de vida. Incide mais nas regiões axilar, inguinal, perianal e inframamária. Dentre suas complicações crônicas, são descritos processos fistulizantes com comprometimento de estruturas importantes, como o sacro e o cóccix, aparelho esfinteriano, uretra e vasos calibrosos, como os inguinais. As proporções de alguns casos de HS, exigindo intervenções alargadas, em vários tempos e com aplicação de retalhos e enxertos justificam relatos de casos que fogem da rotina, como o atual. Os autores apresentam um caso de comprometimento extenso da região glútea e perianal, que exigiu ressecção alargada com retalho e fistulectomia em um segundo tempo cirúrgico, com bom resultado para a paciente.

**Palavras-chave:** hidradenite supurativa; nádegas; retalhos cirúrgicos.

---

## INTRODUCTION

Hidradenitis suppurativa (HS) is a chronic, recurrent and debilitating disease, affecting mainly women, especially in their second and third decades of life<sup>1-8</sup>. Its most common incidence is in the axillary, inguinal, perianal and inframammary regions<sup>3,9,7</sup>. Its cause has been attributed to apocrine duct occlusion caused by keratin plugs, involving some triggering factors – friction of adipose tissue, sudoresis, heat, stress, tight clothes – and some facilitating factors – genetic and hormonal

factors<sup>1,2,4-6,8,10,11</sup>. Its chronic complications include chronic fistulizing processes, with involvement of important adjacent structures, such as the sacrum and coccyx, the anal sphincter, urethra and great-caliber vessels, such as the groin vessels<sup>10</sup>. The proportions of some cases of HS requiring extensive surgical procedures at several moments and the application of flaps and grafts, justify unusual cases reports, like this one<sup>2</sup>.

Report a case of perianal and gluteal hidradenitis suppurativa treated with radical resection and rotation flaps.

---

*Study carried out at the Santa Casa de Misericórdia de Belo Horizonte – Belo Horizonte (MG), Brazil.*

*Financing source: none.*

*Conflict of interest: nothing to declare.*

---

*Submitted on: 09/22/2009*

*Approved on: 10/22/2009*

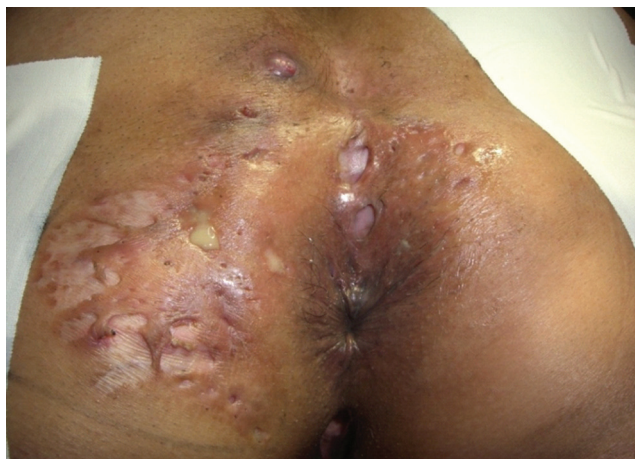## CASE DESCRIPTION

Clinical examination: MAMN, female, 45 years old, with three years of purulent secretion drainage in the gluteal and perianal regions.

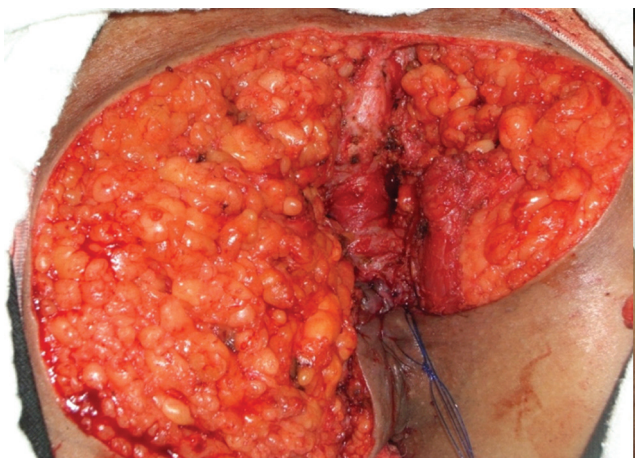
Proctologic examination: at the inspection, several fistulous orifices are observed, with palpable courses through the skin with purulent secretion drainage, located in the gluteal and perianal regions (Figure 1). No anomalies were detected with rectal touch examination and rectosigmoidoscopy.

Colonoscopy: performed until the terminal ileum, without alterations.

Intestinal flow: no alterations.



**Figure 1.** Panoramic view of hidradenitis suppurativa.



**Figure 2.** Panoramic view of the bleeding area of surgical resection and seton insertion to concomitantly approach the anal fistula.

Blood exams: routine exams, as well as hepatic function tests, VHS and PCR, did not show alterations.

Diagnostic hypothesis: hidradenitis suppurativa.

Conduct: radical excision of skin and subcutaneous tissue affected by the disease.

First surgery: a radical excision of affected skin and subcutaneous tissue was performed using seton of a perianal fistula. The bleeding area reconstruction was performed using rotation of subcutaneous skin and muscular fascia flaps (Figures 2 and 3A and B). The final aspect of the surgery was according to expected patterns, with proper skin approximation (Figure 4).

Histopathology examination (HPE): the specimen HPE showed fistulous courses in the subcutaneous tissue, suggesting hidradenitis suppurativa (Figure 5).

Second surgery: the approach to the fistula channeled by seton in the first surgery was performed 40 days later, with excellent surgical result.

Patient control: the patient was examined two and four months after the second surgery, and at these two moments, the final aspect of the surgery was documented (Figures 6 and 7).

## LITERATURE

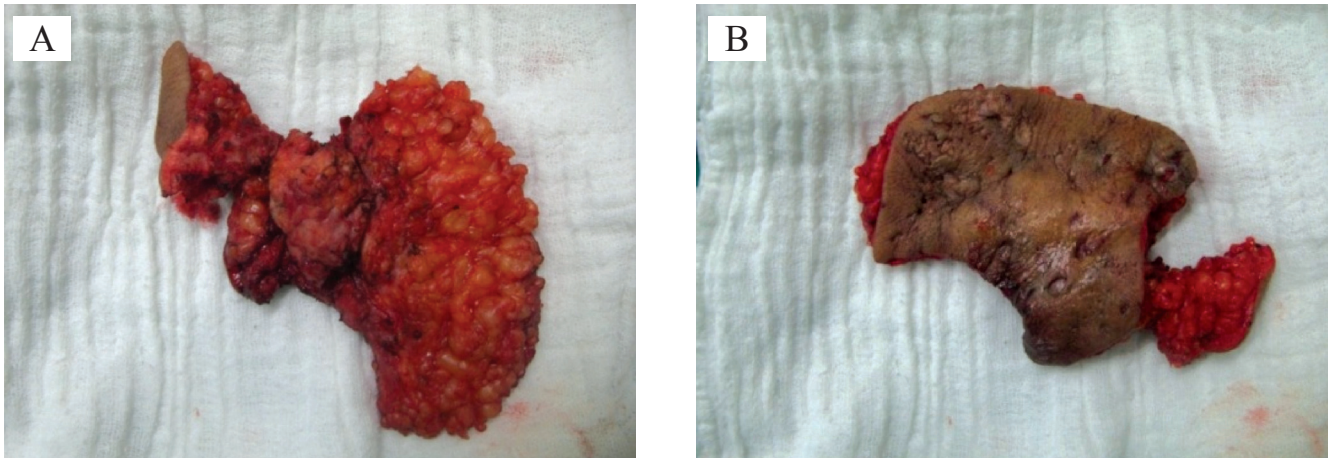
### Other names

Hidradenitis Suppurativa, Hidrosadenitis Suppurativa, Acne Inversa, Acne Conglobata, Verneuil's Disease, Velpeau's Disease<sup>1,3,12,13</sup>.

### History

HS was first described by Velpeau (1839), who reported unusual processes related to the peculiar locations of axillary, mammary and perianal abscesses. For this reason, it was named "Velpeau's disease". After some time, Velpeau was not included in the references, despite his classical study of 1839<sup>13</sup>.

However, that was Verneuil, through his several publications on the subject in the 1850's, who most contributed to the knowledge of this disease, until then known as "Velpeau's disease". For this reason, "Verneuil's disease" was also established, recognizing the importance of his publications<sup>12</sup>.



**Figure 3.** Internal view (A) and external view (B) of the resected surgical specimen.

But the relation of HS with sweat glands was made only about 30 years after that, by Dubreuilh (1893), in his classical study of almost 120 years<sup>14</sup>.

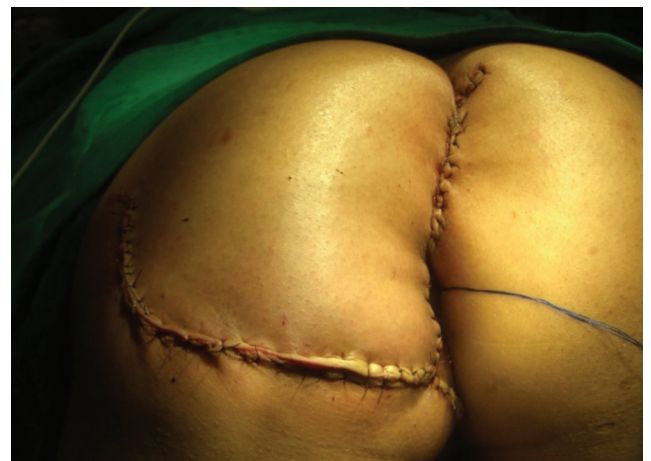Pollitzer, also in 1893, repeated the studies made by Dubreuilh, and the first case of HS was published on around 40 years after Brunsting (1939).

### General

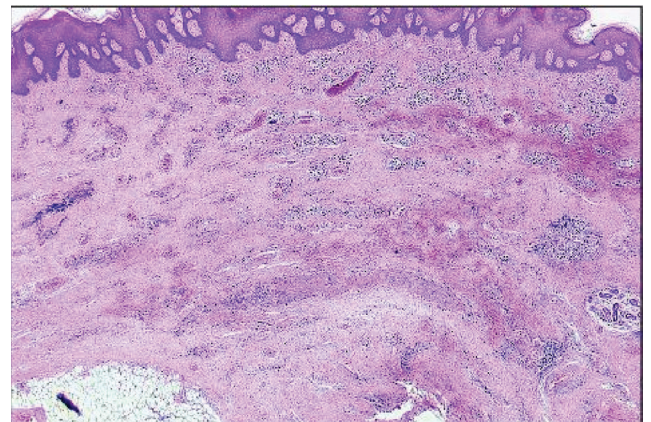
HS is a chronic, recurrent and debilitating disease, affecting mainly women, especially in their second and third decades of life<sup>2-8</sup>. Its most common incidence is in the axillary, inguinal, perianal and inframammary regions<sup>1,3,5,7,9</sup>. Its cause has been attributed to apocrine duct occlusion caused by keratin plugs, involving some triggering factors – friction of adipose tissue, sudoresis, heat, stress, tight clothes – and some facilitating factors – genetic and hormonal factors<sup>1,2,4-6,8,10,11</sup>.

### Diagnosis

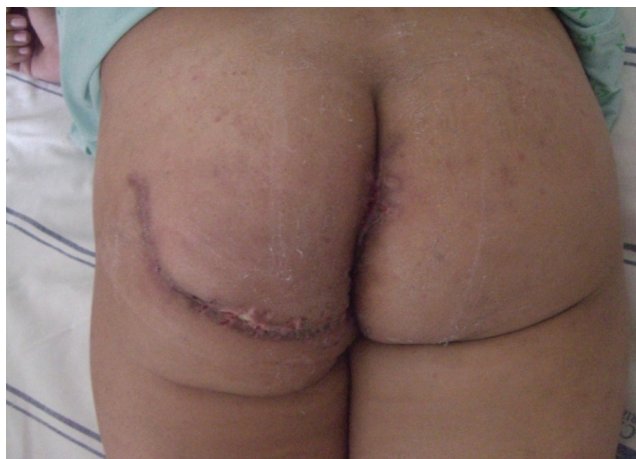The diagnosis is eminently clinical, based on symptoms reported by the patient and signs observed by the physician. The initial symptoms include discomfort, pruritus, erythema and hyperhidrosis in the affected area<sup>7</sup>. With the disease progress, the symptoms are more evident. The physical examination detects lesions in the form of multiple diffused abscesses, with chronic drainage in the form of multiple fistulas through fistulous orifices of varied aspects. The skin and subcutaneous tissue in the affected area become



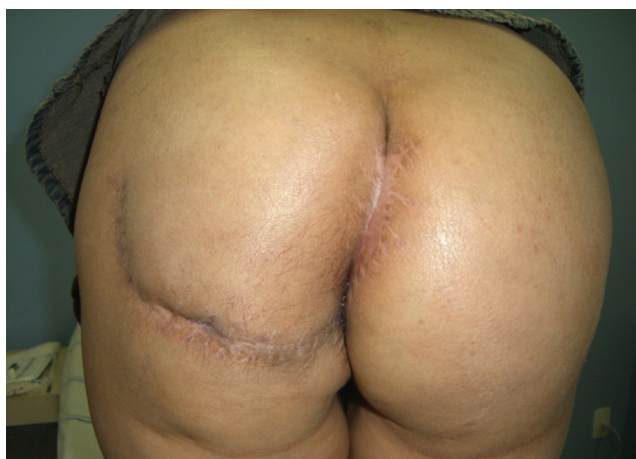**Figure 4.** Panoramic view of the immediate result of the surgery, after using cutaneous flaps.



**Figure 5.** Panoramic view of a plate at the histopathology examination showing cryptic formations in the epithelium and dense conjunctive tissue with perifollicular inflammatory infiltrate.



**Figure 6.** Final panoramic view of the surgery two months after the surgical intervention.



**Figure 7.** Final panoramic view of the surgery four months after the surgical intervention.

hardened, fixed and fibrotic, welding the dermis and epidermis layers together, keeping them from sliding apart<sup>4,7,8,11</sup>.

The clinical condition is characterized by long-term symptoms and signs that may reach 30 years of progress, with recurrent abscesses and fistulas, which, after the inflammatory phase, leave sequelae such as areas of fibroses, fistulous orifices and scarce purulent secretion<sup>1,4,10,11</sup>. When the disease affects the perianal area, it rarely involves the anal sphincter<sup>8,10</sup>. The diagnosis, in the chronic form of the disease, is clinical and easily performed, depending the coloproctologist's experience. In certain situations, a biopsy is required to confirm the diagnosis, such as in the atypical

cases of perianal Crohn's disease, tuberculous ulcer and carcinoma. The association with spinocellular carcinoma, in case of long-term progress, is very rare<sup>1,7,15,16</sup>.

The most important acute complication is characterized by an inflammatory and later infectious process, affecting superficial and deep tissues with cellulitis, abscesses and suppuration. Its chronic complications result from fistulas and the involvement of important structures, such as the sacrum and coccyx, the anal sphincter, urethra and great-caliber vessels, such as the groin vessels<sup>1,4</sup>.

Complementary exams are required in the presence of extensive suppurative areas, deep fistulas and involvement of noble structures. Bacterioscopy and culture of secretions, radiography of the sacrum and coccyx, fistulography and computed tomography of the pelvis can be performed.

The histopathology exam shows a cellular reaction into the lumen of apocrine sweat glands, with distention by leukocytes and cellular infiltration of adjacent conjunctive tissue. In the macroscopic perspective, the subcutaneous tissues have higher density, skin purple discoloration and fistulous orifices with little purulent secretion<sup>8</sup>.

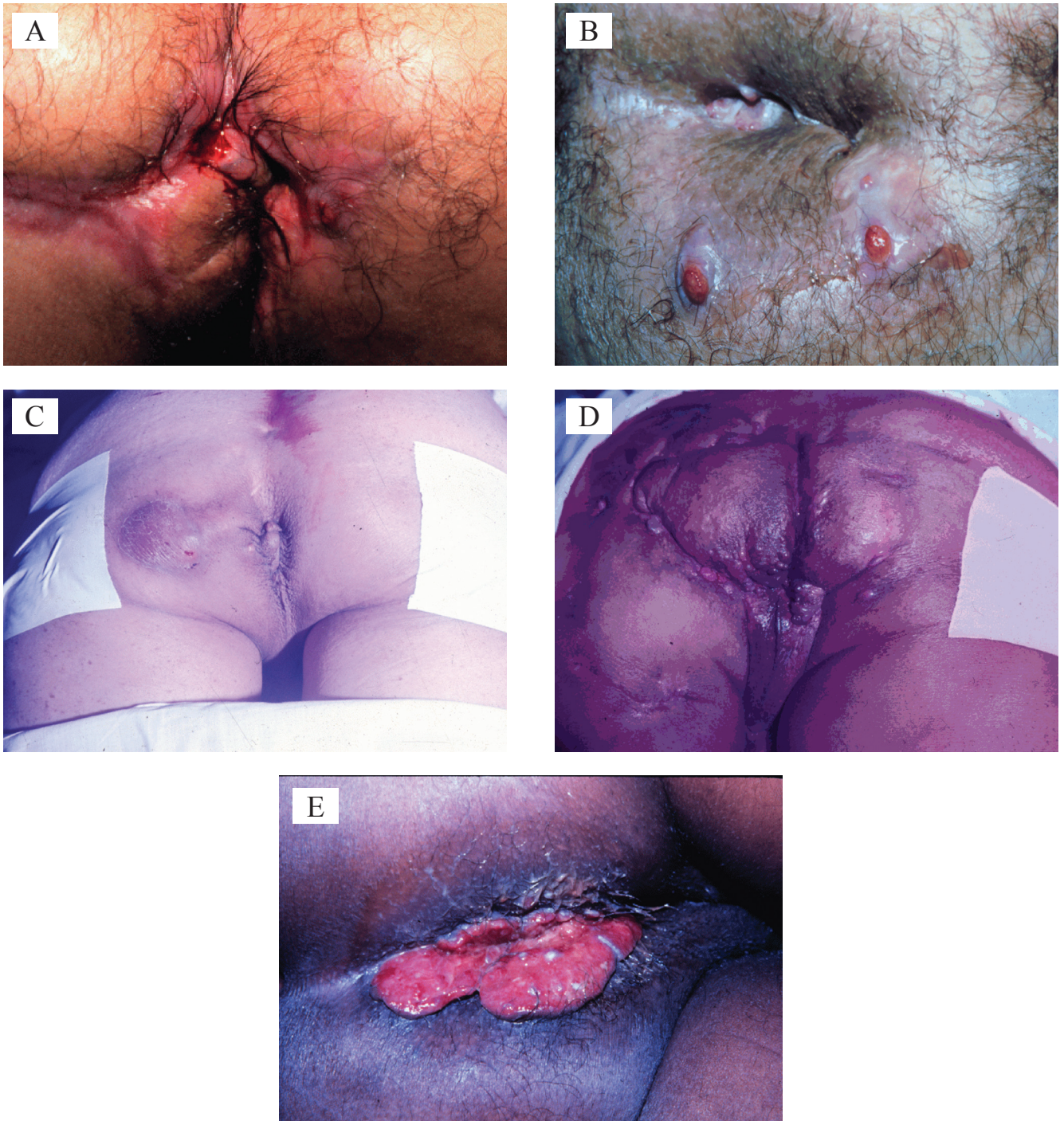
The secretion culture can isolate *Streptococcus milleri*, *Staphylococcus aureus*, anaerobic *Streptococcus* and bacteroids<sup>7,8</sup>.

### Differential diagnoses

The diseases that should be considered and ruled out as differential diagnoses include (Figure 8): Crohn's disease (Figure 8A), anorectal fistulas (Figure 8B), perianal fistulas (Figure 8C), cutaneous tuberculosis (Figure 8D), lymphogranuloma venereum (Figure 8E), pilonidal cyst, as well as other rarer diseases, such as anthrax, epidermoid cyst (infected dermoid cyst), erysipelas, furuncle, granuloma inguinale, steatocystoma multiplex and actinomycosis<sup>5,7,8,15</sup>.

### Associated conditions

The conditions that can be associated with hidradenitis suppurativa include: acanthosis nigricans, certain forms of arthritis, Crohn's disease, Down's syndrome, Graves' disease, Hashimoto's thyroiditis, herpes simplex, hyperandrogenism, irritable bowel syndrome and Sjögren's syndrome<sup>15</sup>.



**Figure 8.** Some morbid entities that should be considered as differential diagnoses of hidradenitis suppurativa: Crohn's disease (A), multiple non-specific anorectal fistulas (B), non-specific perianal fistulas (C), cutaneous tuberculosis (D) and lymphogranuloma venereum (E).

### **Anogenital hidradenitis suppurativa**

It affects more frequently the groin, involving the inguinal region, pubic region, internal face of the thigh and lateral scrotum. The perineum, buttocks and

perianal folds are frequently included; the fistulas may deeply dissect in the tissue, involving the musculature, fascia and bowel. In the perianal form, biopsies are indicated to remove coexisting cancer and perianal

Crohn's disease. It rarely affects the anal canal, but if involved, it is never above the pectineal line<sup>7,8,15</sup>.

### Treatment

Multiple treatment options are available, including antibioticotherapy, systemic retinoids, intralesional corticosteroids, hormonal therapy, immunosuppressors, radiotherapy, cryotherapy, local care of the lesion, laser therapy and surgical treatment. No isolated treatment was effective to the patients<sup>1-4,6-9,17</sup>.

The surgical approach still seems to be the ideal option, and it may vary from simple incision and acute abscess drainage to radical excision of the whole tissue with apocrine glands. The radical excision of the whole affected tissue is the definitive and gold-standard treatment, as the recurrence rate is inversely proportional to the surgical radicality: the recurrence rate ranges from 100% in three months (isolated drainage) to 25% (cases of surgical radicality in 20 months after the radical excision)<sup>1-5,8,11</sup>.

### REFERENCES

1. Jansen I, Altmeyer P, Piewig G. Acne inversa (alias hidradenitis suppurativa). *J Eur Acad Dermatol Venereol* 2001;15(6):532-40.
2. Mitchell KM, Beck DE. Hidradenitis suppurativa. *Surg Clin North Am* 2002;82(6):1187-97.
3. Rompel R, Petres J. Long-term results of wide surgical excision in 106 patients with hidradenitis suppurativa. *Dermatol Surg* 2000;26(7):638-43.
4. Slade DE, Powell BW, Mortimer PS. Hidradenitis suppurativa: pathogenesis and management. *Br J Plast Surg* 2003;56(5):451-61.
5. Wiltz O, Schoetz DJ Jr, Murray JJ, Roberts PL, Coller JA, Veidenheimer MC. Perianal hidradenitis suppurativa. The Lahey Clinic experience. *Dis Colon Rectum* 1990;33:731-4.
6. Kraft JN, Searles GF. Hidradenitis suppurativa in 64 female patients: retrospective study comparing oral antibiotics and antiandrogen therapy. *J Cutan Med Surg* 2007;11(4):125-31.
7. Sohail N, Spencer JP, Mather R. Chronic, draining perianal sinuses. *Am Fam Physician* 2006;74(12):2089-90.
8. Mortimer PS, Lunniss PJ. Hidradenitis suppurativa. *J R Soc Med* 2000;93(8):420-2.
9. Mekkes JR, Bos JD. Long-term efficacy of a single course of infliximab in hidradenitis suppurativa. *Br J Dermatol* 2008;158(2):370-4.
10. Culp CE. Chronic hidradenitis suppurativa of the anal canal. A surgical skin disease. *Dis Colon Rectum* 1983;26(10):669-76.

### CONCLUSION

The approach used in the treatment of hidradenitis suppurativa remains challenging to physicians and frustrating to patients. As the number of randomized studies is insufficient, due to the lack of long series of cases, comparing the several types of treatment, the best approach is based on the patient's clinical condition, results from prior nonsurgical treatments and the physician's experience. The radical excision is considered the gold standard, and it should be the treatment of choice, since it is well indicated. Leaving the surgical wound resulting from enlarged resection of skin and subcutaneous tissue to heal at a second moment should not taken as the best alternative, although this is an option in certain patients; with flap rotations, when well indicated and performed, as an important factor in the immediate quality of life of the patient.

11. Mandal A, Watson J. Experience with different treatment modules in hidradenitis suppurativa: a study of 106 cases. *Surgeon* 2005;3(1):23-6.
12. Verneuil AS. Études sur les tumeurs de la peau: de quelque maladies des glandes sudoripares. *Arch Gen Med* 1854;94:693-9.
13. Velpeau A. Dictionnaire de Médecine. Un Repertoire des Sciences Medicales sous le Rapport. Theorique et Pratique. 2nd ed. Paris. France; 1839. 91 p.
14. Dubreuilh W. Des hidrosadénites suppurées disséminées Archives de médecine expérimentale et d'anatomie pathologique. 1er Janvier 1893;1.
15. Church JM, Fazio VW, Lavery IC, Oakley JR, Milsom JW. The differential diagnosis and comorbidity of hidradenitis suppurativa and perianal Crohn's disease. *Int J Colorectal Dis* 1993;8(3):117-9.
16. Rosenzweig LB, Brett AS, Lefavre JF, Vandersteenhoven JJ. Hidradenitis suppurativa complicated by squamous cell carcinoma and paraneoplastic neuropathy. *Am J Med Sci* 2005;329(3):150-2.
17. Bong JL, Shalders K, Saihan E. Treatment of persistent painful nodules of hidradenitis suppurativa with cryotherapy. *Clin Exp Dermatol* 2003;28(3):241-4.

### Correspondence to:

Dra. Mônica Mourthé de Alvim Andrade  
Avenida do Contorno, 9921 sala 804 – Barro Preto  
CEP: 30110-945 – Belo Horizonte (MG), Brazil  
E-mail: monicamourtheaa@yahoo.com.br