






A Proposal for Modification of Ferguson's Closed Hemorrhoidectomy Technique Aiming Better Outcomes

Fábio Guilherme Campos¹  Paula Gabriela Melo Moraes²  Pablo Veloso Martins² 
Leonardo Alfonso Bustamante-Lopez²  Carlos Augusto Real Martinez^{3,4} 

¹Department of Colorectal Surgery, University of São Paulo, Medical School (USP), São Paulo, SP, Brazil

²Department of Colorectal Surgery, Hospital das Clínicas, University of São Paulo, Medical School (USP), São Paulo, SP, Brazil

³Department of Surgery, State University of Campinas (UNICAMP), Campinas, SP, Brazil

⁴São Francisco University (USF), Bragança Paulista, SP, Brazil

Address for correspondence Fábio Guilherme Campos, MD, Department of Colorectal Surgery, University of São Paulo, Medical School (USP), Rua Padre João Manoel, 222. Cj 120–São Paulo (SP) 01411-001, Brazil (e-mail: fgmcampos@terra.com.br).

J Coloproctol 2024;44(3):e218–e222.

Abstract

Many technical propositions have been incorporated to the surgical management of hemorrhoidal disease during the recent decades. Besides that, escisional techniques are still considered the best option to control symptoms and reduce recurrence. The present manuscript aims to propose a technical modification of the classical closed hemorrhoidectomy described by Ferguson in America. Our proposition is to perform two sutures to close the wound resulting from hemorrhoidal resection. The first one consists of an anchored continuous suture using a very thin (4–0 or 5–0) monofilament thread coming from inside to the outside skin. After tying the stitch, a simple continuous second suture is made over the previous suture only for mucosal approximation, from outside to inside. Finally, the stitch that initiated the first suture is tied up to the stitch used for the second suture, and the knot remains located above the dentate line, not to disturb the patient. The confection of two layers aims to reinforce the closing of the wound and avoid dehiscence. The idea is that this modification influences postoperative outcomes by reducing symptoms such as wound discharge and pain, and thus improving healing and esthetics. In a next step research, a comparison with the classical technique may bring new insights to this issue.

Keywords

- ▶ hemorrhoids
- ▶ hemorrhoidectomy
- ▶ recurrence
- ▶ rectal prolapse
- ▶ treatment outcome
- ▶ treatment failure

Introduction

Hemorrhoidal disease is a very common and widely prevalent anorectal disorder affecting a great number of people that may require surgical intervention in ~10% of the

patients due to complications or refractory symptoms.^{1,2} Methods of surgical management have been designed and modified since famous surgeons from the English school published their initial ideas and concepts.^{3–5}

A little bit later in 1937, Edward Campbell Milligan (1886–1972) and Clifford Naughton Morgan (1901–1986) published their seminal paper from St. Mark's hospital, demonstrating technical principles of

From Sirio-Libanês Hospital and 9 de Julho Hospital, São Paulo, Brazil.

received
December 26, 2023
accepted after revision
February 7, 2024

DOI <https://doi.org/10.1055/s-0044-1782154>.
ISSN 2237-9363.

© 2024. The Author(s).

This is an open access article published by Thieme under the terms of the Creative Commons Attribution 4.0 International License, permitting copying and reproduction so long as the original work is given appropriate credit (<https://creativecommons.org/licenses/by/4.0/>).

Thieme Revinter Publicações Ltda., Rua do Matoso 170, Rio de Janeiro, RJ, CEP 20270-135, Brazil

resecting the hemorrhoidal tissue that are still valid nowadays.⁶

In opposition of the open European technique, an American surgeon called James A. Ferguson published his technique of hemorrhoidectomy in 1955, with the suggestion to close the wounds margins with locking stitches after pedicle ligation.⁷ He was convicted that this option would result in better postoperative outcomes with reduced anal secretions, pain, bleeding and faster wound healing when compared with the closed technique.

In clinical practice, it is worthy to mention that both techniques are widely performed throughout the world, and surgeons usually add personal modifications regarding methods of dissection, energy sources, associated sphincterotomy and others. Hemorrhoidal excisional techniques are still considered "the state of the art" for HD management, despite technical advancements incorporated in recent years such as stapled hemorrhoidectomy and doppler-guided hemorrhoidal dearterialization.^{8,9}

Most discussions about the best option are based on personal experience, comparative studies and metanalysis. Regarding early postoperative results, Ferguson technique is considered to promote a faster wound healing, less bleeding and pain.¹⁰

The present paper aims to suggest a technical modification to the classical Ferguson's closed hemorrhoidectomy. Our personal experience has demonstrated that it provides a better and more comfortable recovery, as it raises the chance that the wound won't open during the early healing process.

Surgical Technique

Our routine preparation includes an intra hospital procedure with the patient under sedation and spinal anesthesia. Preoperative preparation included rectal washout and endovenous antibiotics administered one hour before surgery. With the patient in the lithotomy position, we usually use a retractor to expose anal canal and distal rectum.

In most cases, three hemorrhoidal piles are excised, after xylocaine submucosal infiltration to reduce bleeding and facilitate dissection. The outside border is grasped with Kelly and dissection is either performed with scissors or cold scalpel, from the skin to the anorectal junction. If necessary, a minimal hemostasis with monopolar diathermy helps to maintain the incisional bed clean. When the proximal border of the pile is reached, dissection is finished with electrocautery. The proximal border is sutured with an absorbable 4-0 or 5-0 Monocryl, and then the continuous suture starts (► Fig. 1).

An anchored continuous suture progressing downwards from inside is performed by approximation of both borders laterally and the wound bed posteriorly. The suture must be placed less than 0.5 cm from each border and the stitch must be maintained under continuous traction, similarly to an intestinal suture. As the proximal end of the wound is reached, a small orifice should be maintained open to facilitate eventual discharge of secretions and blood. This first suture is finished outside by tying the stitch with a surgical knot. These features are important to accomplish a stable

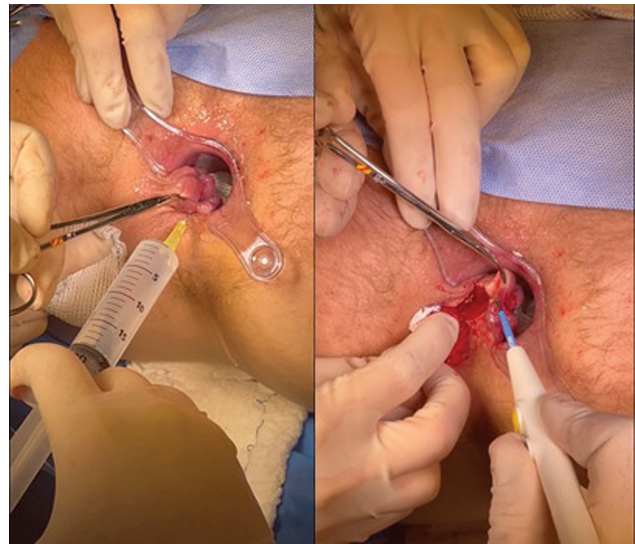


Fig. 1 Submucosal infiltration (left) and final dissection with electrocautery (right).

suture with reduced possibility of sliding the stitch with consequent suture opening.

To achieve this last objective, a second simple (not anchored) continuous suture is confectioned over the previous suture, interesting only the mucosal layer, from outside to inside, trying to close all the little intervals eventually left during the first suture (► Fig. 2). This second plane aims to reinforce the wound suture to avoid its dehiscence in the postoperative period. Finally, the stitch that initiated the first suture is tied up to the stitch used for the second suture, and the knot remains located above the dentate line, not to disturb the patient.

Discussion

Besides the progressive incorporation of new surgical and office-based procedures into clinical practice over the past decades, treatment of HD remains a challenge for the surgeon, who is supposed to decide what is the best operative choice among multiple treatment options in different clinical settings.

Evidence for techniques promising less pain, reduced complications and long-term efficacy is an issue of intense

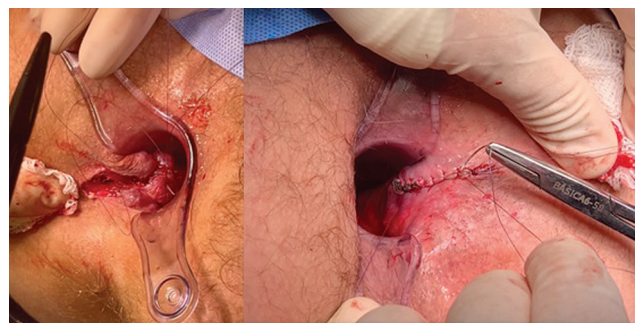


Fig. 2 Hemostatic suture of the wound apex and beginning of the anchored suture at its proximal extremity (left). Progression of continuous suture from outside to the proximal wound (right).

controversy and debate.¹¹ The main problems associated with HD surgical treatment are postoperative pain and recurrence rates. Patient discomfort is mostly associated with excisional techniques like Milligan-Morgan (open) and Ferguson's (closed) techniques. It is worthy to note that modern options such as mechanical rectopexy and dearterialization with mucopexy may also cause pain and suffering.^{8,12}

Ferguson closed hemorrhoidectomy was developed as an effort to mitigate the occurrence and magnitude of some symptoms that were common after an open procedure. But so far, the Milligan-Morgan technique described in Europe remains the current gold standard surgical option for HD in most countries, what makes the controversy involving open versus closed excisional techniques far from a definitive conclusion.

Attention to technical details may obviously promote better outcomes. Pain may derive from a sensitive anoderm

due to edema and inflammation around the wound.¹³ Pain alleviation may be achieved with delicate surgical technique and proper diathermy instruments. Attempts to control discomfort from open wounds with medications (metronidazole, steroids, bupivacaine, local creams and vasodilators) have reported variable results regarding long-term efficacy and side-effects.

On the other hand, the occurrence of bleeding depends on the evacuation of hard stool, the falling of a scar or reabsorption of a transfixed stitch. This complication is also more common after open technique.¹⁴ Thus, it is believed that Ferguson technique may not only reduce pain and bleeding, but it is also associated with faster wound healing.¹⁰

Within this context, the technical modification proposed in the present article aims to be an option to accelerate healing and optimize comfort in the postoperative period. Some points of interest must be emphasized, such as the use of thin (4-0 or 5-0) absorbable wire, the maintenance of traction during the suture and the confection of a second continuous suture over the anchored one. This configuration may lessen the dehiscence risk and help to maintain a clean wound, reducing pain and optimizing anorectal esthetics, if possible.

This aspect is easily verified by inspecting the anus and investigating symptoms during follow-up (►Fig. 3). Surely, this idea deserves the development of a comparative study to evaluate this perspective.

Funding

No fundings were required for this manuscript.

Conflicts of Interests

There are no conflicts of interests.

References

- Mott T, Latimer K, Edwards C. Hemorrhoids: Diagnosis and treatment options. *Am Fam Physician* 2018;97(03):172-179
- Sturiale A, Fabiani B, Menconi C, Cafaro D, Celedon Porzio F, Naldini G. Stapled Surgery for Hemorrhoidal Prolapse: From the Beginning to Modern Times. *Rev Recent Clin Trials* 2021;16(01):39-53. Doi: 10.2174/1574887115666200310164519
- Salmon F. A Practical Essay on Strictures of the Rectum. Third edition London (1828) p. 205.
- Miles WE. Observations Upon Internal Piles. *Surg Gynecol Obstet* 1919;29:497
- Lockhart-Mummery P. Diseases of the rectum and colon (ed 1). London, Bailliere: Tindall and Cox (1923)
- Milligan ETC, Morgan CN, Jones LE, Officer R. Surgical anatomy of anal canal and operative treatment of hemorrhoids. *Lancet* 1937; 2:1119. Doi: 10.1016/S0140-6736(00)88465-2
- Ferguson JA, Heaton JR. Closed hemorrhoidectomy. *Dis Colon Rectum* 1959;2(02):176-179. Doi: 10.1007/BF02616713
- Figueiredo MN, Campos FG. Doppler-guided hemorrhoidal dearterialization/transanal hemorrhoidal dearterialization: Technical evolution and outcomes after 20 years. *World J Gastrointest Surg* 2016;8(03):232-237. Doi: 10.4240/wjgs.v8.i3.232
- Lohsiriwat V. Treatment of hemorrhoids: A coloproctologist's view. *World J Gastroenterol* 2015;21(31):9245-9252. Doi: 10.3748/wjg.v21.i31.9245
- Bhatti MI, Sajid MS, Baig MK. Milligan-Morgan (Open) Versus Ferguson Haemorrhoidectomy (Closed): A Systematic Review and

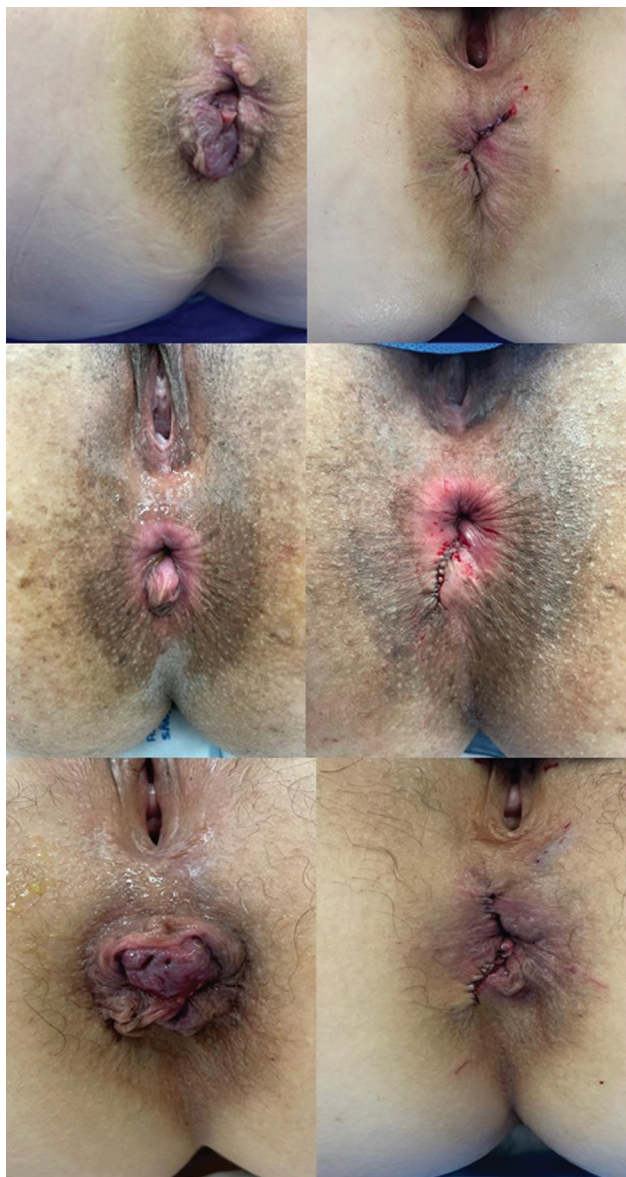

Fig. 3 Three cases showing operative aspects before (left) and after (right) resection and wound closing according to the proposed modified technique.

- Meta-Analysis of Published Randomized, Controlled Trials. *World J Surg* 2016;40(06):1509–1519. Doi: 10.1007/s00268-016-3419-z
- 11 Pata F, Gallo G, Pellino G, et al. Evolution of Surgical Management of Hemorrhoidal Disease: An Historical Overview. *Front Surg* 2021;8:727059. Doi: 10.3389/fsurg.2021.727059
 - 12 Campos FG, Cavallari-Mancuzo D, Bustamante-Lopez LA, Morais PGM, Martinez CAR. Is it possible to optimize stapled hemorrhoidectomy outcomes by enlarging operative criteria indications? Results of a tailored procedure with associated resection in a comparative personal series. *Arq Bras Cir Dig* 2022;35:e1696. Doi: 10.1590/0102-672020220002e1696
 - 13 Pattana-Arun J, Sooriprasoet N, Sahakijrungruang C, Tantiphlachiva K, Rojanasakul A. Closed vs ligasure hemorrhoidectomy: a prospective, randomized clinical trial. *J Med Assoc Thai* 2006;89(04):453–458
 - 14 Ba-bai-ke-re MM, Huang HG, Re WN, et al. How we can improve patients' comfort after Milligan-Morgan open haemorrhoidectomy. *World J Gastroenterol* 2011;17(11):1448–1456