



# Journal of Coloproctology

www.jcol.org.br



## Original article

# Transanal minimally-invasive surgery (TAMIS): technique and results from an initial experience

Carlos Ramon Silveira Mendes<sup>a,b,c,\*</sup>, Luciano Santana de Miranda Ferreira<sup>a,b</sup>,  
Ricardo Aguiar Sapucaia<sup>a,b</sup>, Meyline Andrade Lima<sup>a,b</sup>, Sergio Eduardo Alonso Araujo<sup>d,e</sup>

<sup>a</sup> Service of Coloproctology, Hospital Santa Izabel, Salvador, BA, Brazil

<sup>b</sup> Sociedade Brasileira de Coloproctologia, Rio de Janeiro, RJ, Brazil

<sup>c</sup> Department of Gastroenterology, Faculdade de Medicina, Universidade de São Paulo (USP), São Paulo, SP, Brazil

<sup>d</sup> Service of Colon and Rectal Surgery, Hospital Geral Roberto Santos, Salvador, BA, Brazil

<sup>e</sup> Service of Colon and Rectal Surgery, Hospital das Clínicas, Faculdade de Medicina, Universidade de São Paulo (USP), São Paulo, SP, Brazil

## ARTICLE INFO

### Article history:

Received 15 July 2013

Accepted 7 September 2013

### Keywords:

Rectal neoplasms

Adenomatous polyps

Minimally-invasive surgical procedures

## ABSTRACT

Transanal endoscopic microsurgery is a minimally-invasive approach for rectal lesions. Superior exposure and access to the entire rectum result in lesser risk of compromised margins and lower recurrence rates, when compared to conventional transanal excision. The aim of this study was to describe a single institution's initial experience with transanal minimally invasive surgery (TAMIS). This was a prospective review of our database. Eleven procedures from January 2012 to June 2013 were analyzed. Results: eleven operations were completed. Five men were evaluated. Mean age was 62.9 (40-86). Mean follow-up was 9.3 (2-17) months. Average tumor size was 3.8 (1.8-8) cm. Mean distance from anal verge was 6.3 (3-12) cm. Mean operating time was 53.73 (28-118) min. Postoperative complication rate was 9.1%. There were no readmissions. Mortality was null. Operative pathology disclosed the presence of adenoma in four patients, invasive adenocarcinoma in two, neuroendocrine carcinoma in three, and no residual lesion in one case. TAMIS is a minimally-invasive procedure with low postoperative morbidity at the initial experience. TAMIS is a curative procedure for benign lesions and for selected early cancers. It is useful after neoadjuvant therapy for strictly selected cancers, pending the results of multi-institutional trials.

© 2013 Elsevier Editora Ltda. All rights reserved.

\* Corresponding author.

E-mail: proctoramom@hotmail.com (C.R.S. Mendes)

2237-9363/\$ - see front matter. © 2013 Elsevier Editora Ltda. All rights reserved.

<http://dx.doi.org/10.1016/j.jcol.2013.09.002>

## Cirurgia transanal minimamente invasiva (TAMIS): técnica e resultados em experiência inicial

### R E S U M O

#### Palavras-chave:

Neoplasias retais

Pólipos adenomatosos

Procedimentos cirúrgicos minimamente invasivos

Microcirurgia endoscópica transanal é uma abordagem minimamente invasiva para lesões retais. Apresenta menor risco de margem comprometida e menores taxas de recorrência em comparação com excisão transanal convencional. Objetivou-se descrever a experiência inicial, de uma única instituição, com cirurgia minimamente invasiva transanal (TAMIS). Avaliação prospectiva de nosso banco de dados. Onze procedimentos de janeiro de 2012 a junho de 2013, foram analisados. Resultados: onze operações foram concluídas. Havia cinco homens. A média de idade foi de 62,9 (40-86). O acompanhamento médio foi de 9,3 (2-17) meses. O tamanho médio do tumor foi de 3,8 (1,8-8 cm). Distância média de borda anal foi de 6,3 (3-12) cm. O tempo médio de operação foi de 53,73 (28-118) min. Taxa de complicação pós-operatória foi de 9,1%. Não houve readmissões. A mortalidade foi nula. Achados patológicos foram de adenoma em 4, adenocarcinoma invasivo em 2, carcinoma neuroendócrino em três, e nenhuma lesão residual em um caso. TAMIS é um procedimento minimamente invasivo, com baixa morbidade pós-operatória durante a experiência inicial. TAMIS é curativo para as lesões benignas e de cânceres selecionados. É útil após a terapia neoadjuvante para casos de câncer rigorosamente selecionados, enquanto os resultados de estudos multi-institucionais são aguardados.

© 2013 Elsevier Editora Ltda. Todos os direitos reservados.

## Introduction

Transanal endoscopic microsurgery (TEM) is a minimally invasive technique originally conceived by Dr. Gerhard Buess, in the 80's, to allow resection of rectal cancer.<sup>1</sup> The use of TEM allowed the reduction of local recurrences in comparison to conventional transanal resection.<sup>2</sup> With less morbidity, it can reduce the time of hospitalization, pain during the postoperative period and time away from the usual activities in comparison to laparoscopic rectosigmoidectomy.<sup>3-5</sup>

However, even after the arrival of TEO (Transanal Endoscopic Operations, Karl Storz, Tuttlingen, Germany) and the resulting simplification of the TEM equipment, the latter represents a technique associated with some degree of complexity and a learning curve.<sup>6,7</sup> As a result, it ended up being practiced mostly by a small number of experts associated with performing a high number of procedures. In addition, it requires the availability of equipment and dedicated instruments which, at present, are available in less than a dozen Brazilian medical centers, mostly educational institutions. As a result, in Brazil, the minimally-invasive treatment of rectal tumors, despite being within the common competence of all coloproctology specialists, is limited to a few Brazilian hospitals. Even after 30 years of its introduction, TEM/TEO are not used on a larger scale, in spite of the huge benefits they offer to patients with benign and superficially malignant rectal tumors.

Since its introduction in 2009,<sup>8</sup> the use of the transanal minimally-invasive surgery (TAMIS) technique has been increasing in the United States, in Europe and also in our country as an alternative to TEM for local resection of rectal tumors located in the rectum and distal rectum. TAMIS was initially made available because of the existence of devices for single

port surgery and platforms for transanal surgery (GelPOINT PATH, Applied Medical, Rancho Santa Margarita, CA, USA and SILS Port, Covidien, Mansfield, MA, USA). The technique requires the use of a single port device transanally and allows the use of conventional laparoscopic instruments in addition to endoclamps and advanced bipolar coagulation scissors.

Since its initial description, case reports and small series of TAMIS have been published demonstrating that it is a feasible and accessible alternative for most expert surgeons and of low initial cost when compared to TEM/TEO.<sup>9-14</sup> In Brazil, the initial experience with the method was published by Seva-Pereira et al.,<sup>15</sup> and Alves Filho et al.,<sup>24</sup> but they included only five and four cases, respectively. The aim of this study is to evaluate the efficacy and safety of TAMIS use for surgical treatment of rectal lesions.

## Method

Between January 2012 and June 2013, after approval by the ethics committee of our institution, a prospective data recording was performed regarding the surgical treatment of patients with rectal cancer by TAMIS.

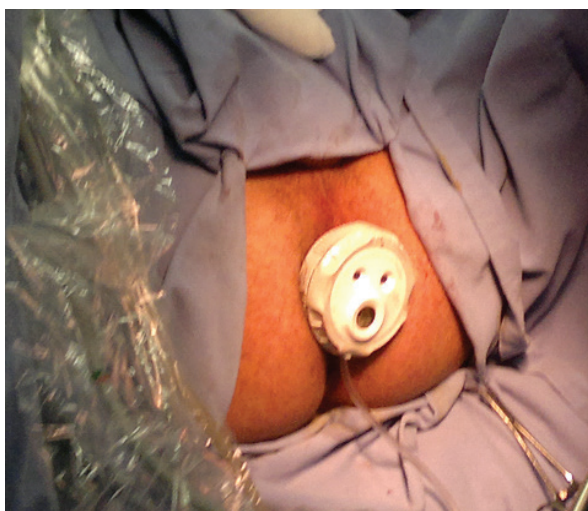
Patient selection included patients with adenomas, neuroendocrine tumors smaller than 2 cm and well-differentiated adenocarcinomas with no lymphatic or lymph node vascular invasion and suspected or confirmed preoperative uT1N0 tumor staging.

The surgical procedure was performed by two surgeons. Mechanical bowel preparation and broad-spectrum antibiotic prophylaxis was carried in all cases prior to surgery. All surgeries were performed under general anesthesia. The patient

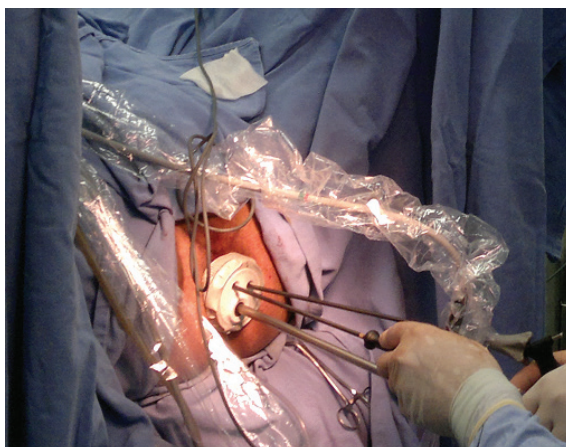
was positioned on the operating table in lithotomy position regardless of the location of lesion.

The SSL (single-site laparoscopic access system, Ethicon Endo-Surgery, Cincinnati, OH, USA) equipment was used (Fig. 1). After lubricating the kit and the anal canal, the port was installed and was established pneumorectum with a pressure of 12 mmHg. A 10 mm and 30o optical fiber cable and two 5 mm ports were employed to work with the laparoscopic instruments such as grasper, electrocautery and scissors (Fig. 2). A full-thickness excision was performed in all lesions with known or suspected submucosal invasion aiming to obtain 1cm lateral and deep excision margins. Wound closure in all cases was performed by continuous primary suture using absorbable sutures, interrupted by laparoscopic clips.

All patients were hospitalized. All immediate and late complications were recorded. All patients included in the study underwent a rigorous follow-up and if they had invasive carcinoma, they were submitted to oncological follow-up, including anoscopy, rectoscopy, serum Carcinoembryonic Antigen (CEA) levels and imaging assessment.



**Fig. 1 - Single-site laparoscopic (SSL™) access system, Ethicon Endo-Surgery, Cincinnati, OH, USA).**



**Fig. 2 - TAMIS: transoperative procedure.**

## Results

Eleven consecutive patients were underwent surgery successfully using TAMIS in the lithotomy position using SSL. Five (45.5%) patients were women. The mean age was 62.9 (40-86) years (Table 1).

**Table 1 - Demographic data.**

Patients (n)	11
Male (%)	5 (45.5)
Female	6 (54.5)
Mean age (range)	62.9 (40-86)

The distance from the lower limit of the lesion to the anal verge determined by preoperative rigid rectoscopy was 6.3 (3-12) cm.

There were no major technical difficulties associated with the procedures. The mean surgical time was 53.73 (28-118) minutes. The mean size of the lesions was 3.8 (1.8 to 8) cm (Table 2). A full-thickness resection was performed in 10 cases.

Of the 11 patients, four patients (36.4%) had adenoma, three patients (27.3%) had carcinoid tumors and two patients (18.2%) had pT1N0 adenocarcinomas. Suspected retrorectal tumor and melanoma were diagnosed each in one case (9.1%) (Table 2).

**Table 2 - Characteristics of patients and lesions in 11 surgical procedures using TAMIS.**

Case Age/ Gender	Distance to anal verge (cm)	Lesion size (cm)	Histological diagnosis
83/m	4	3	moderately differentiated pT1 adenocarcinoma
67/m	3	5	melanoma
79/m	9	8	tubular adenoma with high-grade dysplasia
81/f	3	5	tubular adenoma with high-grade dysplasia
56/f	8	3	carcinoid tumor
61/f	9	2	carcinoid tumor
70/f	4	3	moderately differentiated pT1 adenocarcinoma
46/m	6	1.8	fibrosis
41/m	8	3	carcinoid tumor
65/f	4	4	tubular adenoma with high-grade dysplasia

f, female; m, male.

All tumors were resected with gross negative resection margins, confirmed by anatomopathological analysis.

Regarding the surgical wound closure, it was not performed in only one case (9.1%) of full-thickness resection as excessive tension was observed during the closing attempt, and thus healing by second intention was decided.

Early intraoperative morbidity occurred in only one case (9.1%). In this case, during full-thickness resection of the intraperitoneal lesion, perforation of the rectum with access to the abdominal cavity during surgery was identified and corrected by transanal suture. There was no subsequent adverse outcome in the treatment of this patient.

There were no postoperative complications in all cases. There was no postoperative bleeding or infectious complications. No patient required reoperation. There was no mortality associated with the technique.

The average duration of hospitalization was 1.09 days. Patients have not shown recurrent lesions after a mean follow-up of 9.2 months.

---

## Discussion

In this study, we report the first 11 cases of TAMIS performed at our institution for the treatment of benign and malignant rectal lesions. The sample of TAMIS shown here represents, to our knowledge, the largest series of its kind in Brazil. It was possible to completely resect the rectal lesion in all cases and there was no significant morbidity associated with the approach, even when there was invasion of the peritoneal cavity, an intraoperative occurrence resolved without conversion to abdominal access.

Some authors consider the TEM/TEO surgical procedures as being associated with a significant degree of technical complexity. Fifteen years after the introduction of the technique, the number of procedures performed by Buess et al. did not exceed 500.<sup>16</sup> Among the reasons involved for the limited use of the procedure within expert surgeons were the initial investment associated with equipment acquisition, the need for special training and the small sample of patients who would benefit from the method.<sup>17</sup>

There is evidence that for selected pT1N0 adenocarcinomas, local resection using endoscopic microsurgery have similar recurrence and survival results as those obtained after radical resections.<sup>4,18,19</sup> Furthermore, Lezoche et al. demonstrated that in patients with cT2N0 adenocarcinoma of the rectum submitted to neoadjuvant therapy, local endoscopic microsurgical resection was similar to the radical surgery with total mesorectal excision regarding neoplastic recurrence and survival.<sup>20,21</sup> The indications for TAMIS are the same for TEM/TEO.<sup>22</sup>

Until the last decade, the TEM and TEO platforms were the only way to perform transanal endoscopic resection. However, TEM and TEO are not available in many hospitals. TAMIS emerged as an advanced alternative with better cost-effectiveness and as a result, possibly superior to the TEM/TEO platforms in the future, allowing more centers to perform minimally-invasive treatment of rectal tu-

mors.<sup>9</sup> It is estimated that in the United States, the cost of ports necessary to enable the TAMIS platform (between 500 and 650 dollars) is equivalent to the cost of materials used for CO<sub>2</sub> insufflation with the TEM platform.<sup>9,23</sup>

Rapid preparation of the room before the procedure, a 360° and not 220° view within the rectal lumen and the use of conventional laparoscopic instruments represent another advantages when comparing TAMIS to TEM/TEO. The versatility of positioning the patient in the lithotomy position for virtually all cases of TAMIS is an additional advantage. Finally, an additional benefit of TAMIS is that, because the SSL port protector is flexible with a maximum diameter of 30 mm (compared with 40 mm of TEM/TEO), it is possible that the sphincter dilation during TAMIS is smaller than that performed during TEM/TEO, although its impact on sphincter function has not yet been studied.

One of the main technical difficulties related to TAMIS in some cases is pneumorectum instability, which can lead to intermittent rectal lumen collapse, hampering surgery. This event can be solved, to a greater or lesser degree, by an increase in intrarectal pressure to 20 mmHg, greater relaxation or by reposition of the port. Another difficulty occurs, similarly to that observed for TEM/TEO, to the release of smoke fromed by the activation of the electrocautery. The SSL system has only three ports that are used with the optical devices and surgical instruments and sometimes it is necessary to drain the formed smoke.

In the present study, the presence of positive margins in the resected specimen was not observed in 10 cases. In only one case, the pathological analysis showed that the removed tissue was only fibrosis. In none of the cases specimen fragmentation was identified, which can be attributed to the small mean lesion size (3.8 cm).

The increase of TAMIS, in the literature, with several disposable ports designed for single port surgery<sup>8,9</sup> is still under evaluation. Several aspects need to be clarified. One of them refers to the viability of transanal endoscopic access in upper rectal procedures, as the TAMIS platform does not include a surgical rectoscope, which could theoretically provide stability to the surgical procedure at that site.

One of the cases shown in this series evolved with access to the peritoneal cavity during surgery, which characterizes its location more proximal to the rectum. The procedure in this case was appropriately finished using TAMIS. However, this is one more aspect that deserves further investigation. The performance of TAMIS as an alternative to TEM demonstrates that it is a safe procedure with low morbidity and no mortality. This is a perfectly viable alternative to the TEM/TEO platform for the resection of intra and extra-peritoneal benign and selected malignant lesions of the rectum.

---

## Conflicts of interest

The authors declare no conflicts of interest.



## REFERENCES

1. Buess G. Review: transanal endoscopic microsurgery (TEM). *J R Coll Surg Edinb* 1993; 38(4):239-45.
2. de Graaf EJ, Burger JW, van Ijsseldijk AL, et al. Transanal endoscopic microsurgery is superior to transanal excision of rectal adenomas. *Colorectal Dis* 2011; 13(7):762-7.
3. Middleton PF, Sutherland LM, Maddern GJ. Transanal endoscopic microsurgery: a systematic review. *Dis Colon Rectum* 2005; 48(2):270-84.
4. Moore JS, Cataldo PA, Osler T, et al. Transanal endoscopic microsurgery is more effective than traditional transanal excision for resection of rectal masses. *Dis Colon Rectum* 2008; 51(7):1026-30; discussion 1030-1.
5. De Graaf EJ, Doornebosch PG, Tollenaar RA, et al. Transanal endoscopic microsurgery versus total mesorectal excision of T1 rectal adenocarcinomas with curative intention. *Eur J Surg Oncol* 2009; 35(12):1280-5.
6. Maslekar S, Pillinger SH, Monson JR. Transanal endoscopic microsurgery for carcinoma of the rectum. *Surg Endosc* 2007; 21(1):97-102.
7. Koebrugge B, Bosscha K, Jager G, et al. Accuracy of transrectal ultrasonography in staging rectal tumors that are clinically eligible for transanal endoscopic microsurgery. *J Clin Ultrasound* 2010; 38(5):250-3.
8. Atallah S, Albert M, Larach S. Transanal minimally invasive surgery: a giant leap forward. *Surg Endosc* 2010; 24(9):2200-5.
9. Barendse RM, Doornebosch PG, Bemelman WA, et al. Transanal employment of single access ports is feasible for rectal surgery. *Ann Surg* 2012; 256(6):1030-3.
10. Lim SB, Seo SI, Lee JL, et al. Feasibility of transanal minimally invasive surgery for mid-rectal lesions. *Surg Endosc* 2012; 26(11):3127-32.
11. Rimonda R, Arezzo A, Arolfo S, et al. TransAnal Minimally Invasive Surgery (TAMIS) with SILS Port versus Transanal Endoscopic Microsurgery (TEM): a comparative experimental study. *Surg Endosc* 2013.
12. Matz J, Matz A. Use of a SILS port in transanal endoscopic microsurgery in the setting of a community hospital. *J Laparoendosc Adv Surg Tech A* 2012; 22(1):93-6.
13. Lorenz C, Nimmegern T, Back M, et al. Transanal single port microsurgery (TSPM) as a modified technique of transanal endoscopic microsurgery (TEM). *Surg Innov* 2010; 17(2):160-3.
14. Smith RA, Anaya DA, Albo D, et al. A stepwise approach to transanal endoscopic microsurgery for rectal cancer using a single-incision laparoscopic port. *Ann Surg Oncol* 2012; 19(9):2859.
15. Seva-Pereira G, Trombeta VL, Capochim Romagnolo LG. Transanal minimally invasive surgery (TAMIS) using a new disposable device: our initial experience. *Tech Coloproctol* 2013.
16. Mentges B, Buess G, Effinger G, et al. Indications and results of local treatment of rectal cancer. *Br J Surg* 1997; 84(3):348-51.
17. Whitlow CB, Beck DE, Gathright JB. Surgical excision of large rectal villous adenomas. *Surg Oncol Clin N Am* 1996; 5(3):723-34.
18. Winde G, Nottberg H, Keller R, et al. Surgical cure for early rectal carcinomas (T1). Transanal endoscopic microsurgery vs. anterior resection. *Dis Colon Rectum* 1996; 39(9):969-76.
19. Heintz A, Morschel M, Junginger T. Comparison of results after transanal endoscopic microsurgery and radical resection for T1 carcinoma of the rectum. *Surg Endosc* 1998; 12(9):1145-8.
20. Lezoche E, Guerrieri M, Paganini AM, et al. Long-term results in patients with T2-3 N0 distal rectal cancer undergoing radiotherapy before transanal endoscopic microsurgery. *Br J Surg* 2005; 92(12):1546-52.
21. Lezoche G, Baldarelli M, Guerrieri M, et al. A prospective randomized study with a 5-year minimum follow-up evaluation of transanal endoscopic microsurgery versus laparoscopic total mesorectal excision after neoadjuvant therapy. *Surg Endosc* 2008; 22(2):352-8.
22. Qi Y, Stoddard D, Monson JR. Indications and techniques of transanal endoscopic microsurgery (TEMS). *J Gastrointest Surg* 2011; 15(8):1306-8.
23. Atallah S, Albert M, Debeche-Adams T, et al. Transanal minimally invasive surgery (TAMIS): applications beyond local excision. *Tech Coloproctol* 2013; 17(2):239-43.
24. Alves filho EF, Costa PFO, Guerra JC. Transanal minimally invasive surgery with single-port (TAMIS) for the management of rectal neoplasms: a pilot study. *J Coloproctol*. 2012; 32(4): 402-406.
25. Mendes CRS, Ferreira LSM, Sapucaia RA, Lima MA, Araujo SEA, Silva MJM et al. Transanal endoscopic microsurgery (TEM): initial experience. *J Coloproctol*, 2012;32(4): 411-415.
26. Araujo SEA. Transanal endoscopic microsurgery: a Brazilian initial experience in private practice. *Hepato-Gastroenterology*. 2012; 59:118.