


# Ghost Ileostomy Release Down-Our Initial Experience

Mudassir Ahmad Khan<sup>1</sup> Arshad Baba<sup>2</sup> Rouf Ahmad Wani<sup>3</sup> Asif Mehraj<sup>4</sup> Fazl Q. Parray<sup>3</sup>  
Nisar Ahmad Chowdri<sup>3</sup>

<sup>1</sup> Govt Medical College Rajouri, Rajouri, Kheora, India

<sup>2</sup> Health Services, Kashmir, India

<sup>3</sup> Sher-i-Kashmir Institute of Medical Sciences, Srinagar, Jammu and Kashmir, India

<sup>4</sup> Government Medical College Srinagar, Srinagar, Jammu and Kashmir, India

Address for correspondence Mudassir Ahmad Khan, MBBS, MS, FACRSI, FCRS, FMAS, Govt Medical College Rajouri, Rajouri, Kheora, India (e-mail: kxanmudassir925@gmail.com).

J Coloproctol 2023;43(2):61–67.

## Abstract

**Background** Many publications describe the advantages of the creation of ghost ileostomy (GI) to prevent the need for formal covering ileostomy in more than 80% of carcinoma rectum patients. However, none of the papers describes exactly how to ultimately remove the GI in these 80% of patients in whom it doesn't need formal maturation.

**Aim** To describe and evaluate the ghost ileostomy release down (GIRD) technique in terms of feasibility, complications, hospital stay, procedure time etc. in patients with low anterior resection/ultra-low anterior resection (LAR/uLAR) with GI for carcinoma rectum.

**Method** The present was a prospective cohort study of patients with restorative colorectal resections with GI for carcinoma rectum, Postoperatively the patients were studied with respect to ease and feasibility of the release down of GI and its complications. The data was collected, analyzed and inference drawn.

**Results** A total of 26 patients needed the GIRD and were included in the final statistical analysis of the study. The procedure was done between 7<sup>th</sup> to 16<sup>th</sup> postoperative days (POD) and was successful in all patients without the need of any additional surgical procedure. None of the patients required any local anesthetic injection or any extra analgesics. The average time taken for procedure was 5-minutes and none of the patients had any significant difficulty in GI release. There were no immediate postprocedure complications.

**Conclusion** The GIRD technique is a simple, safe, and quick procedure done around the 10<sup>th</sup> POD that can easily be performed by the bedside of patient without the need of any anesthesia or additional analgesics.

## Keywords

- ▶ ghost Ileostomy
- ▶ ghost Ileostomy release down
- ▶ low anterior resection
- ▶ carcinoma rectum

received

December 9, 2022

accepted after revision

March 7, 2023

DOI <https://doi.org/>

10.1055/s-0043-1769487.

ISSN 2237-9363.

© 2023. Sociedade Brasileira de Coloproctologia. All rights reserved.

This is an open access article published by Thieme under the terms of the Creative Commons Attribution-NonDerivative-NonCommercial-License, permitting copying and reproduction so long as the original work is given appropriate credit. Contents may not be used for commercial purposes, or adapted, remixed, transformed or built upon. (<https://creativecommons.org/licenses/by-nc-nd/4.0/>)

Thieme Revinter Publicações Ltda., Rua do Matoso 170, Rio de Janeiro, RJ, CEP 20270-135, Brazil

## Introduction

Colorectal cancer is the disease with a major worldwide burden in terms of patient sufferings and cost of treatment. Total mesorectal excision (TME) is the gold standard treatment for rectal cancer, with better overall survival and fewer distant and local recurrences.<sup>1-3</sup> The sphincter-preserving low anterior resection (LAR) or ultra-low anterior resection (uLAR) are now considered the standard operations for rectal cancer, which allows a primary anastomosis to be created at a lower level.<sup>4</sup>

Recently, the frequency of abdominoperineal resection and the resulting permanent stomas for rectal cancer has diminished in favor of sphincter-preserving operations.<sup>5</sup> Anastomotic leak (AL) still remains the most significant complication after LAR with TME. Protective stoma is often constructed after LAR for carcinoma rectum to prevent AL, with the hope that by diverting the fecal stream and keeping the anastomosis free of fecal material, leakage will be less likely. Whether a malfunctioning stoma really prevents leaks or merely reduces the consequence of leakage is still up for debate.

There is no clear-cut agreement regarding whether a malfunctioning stoma should be constructed for all rectal anastomoses, only for the low ones, or not at all. Several studies have demonstrated that a malfunctioning stoma decreases the incidence of clinical leakage of a colorectal anastomosis.<sup>6,7</sup> Some authors, however, have reported no difference in leakage rates but with a reduced incidence of reoperation,<sup>8</sup> and still other surgeons have reported that covering with protective stoma had no influence on AL and reoperation rates. Furthermore, the complications that can be caused by the stoma itself should not be ignored.<sup>9-15</sup> In fact, some studies have reported that reversal of the stoma is associated with complications in up to 40% of patients.<sup>16</sup> Many patients will have to live with a covering stoma for several months after primary surgery because of the low clinical priority for reversal,<sup>17</sup> and about 20% of patients are left with a permanent stoma due to postoperative complications of anterior resection.<sup>18</sup>

In short, patients in high-risk group for AL would benefit from stoma protection, while patients in low-risk group simply do not require stoma. However, in patients with a medium-risk of AL, it is very difficult to decide whether or not to construct a protective covering stoma. In the intermediate-risk patients, the concept of ghost ileostomy (GI), also known as prestage or virtual ileostomy, integrates the advantages of a covering ileostomy (CI) while avoiding its complications in patients subjected to low rectal resection.<sup>19</sup> This procedure is just a prestage ileostomy that at any time can be externalized and opened. In case of clinical and radiological AL, the GI is matured to complete the CI in order to divert the fecal stream from the anastomotic site leakage. However, in case of uneventful postoperative course, GI prevents all complications related to malfunctioning ileostomy.<sup>20</sup>

Many publications concluded that the creation of GI in LAR averts the need for formal CI in more than 80% of

carcinoma rectum patients.<sup>21,22</sup> However, none of the papers describe exactly how to ultimately remove or release the GI in these 80% of patients to whom the GI doesn't need formal maturation. Furthermore, almost none of the published literature describes the outcome of the release down of GI. In this article, we also intend to explain in a simple and lucid way the release down of GI technique, along with our initial experience with this procedure.

## Objectives

To describe and evaluate the ghost ileostomy release down (GIRD) technique in terms of feasibility, complications, hospital stay, procedure time etc. in patients with LAR/uLAR with GI for carcinoma rectum.

## Material and Methods

This study was carried out from November 2016 to August 2018 at a Tertiary Care Hospital in North India. The patients were included in this study only after obtaining a proper informed consent for the same from all the included patients. It was a prospective cohort study of restorative colorectal resections (LAR and ultra-LAR) for carcinoma rectum. Our cohort included carcinoma rectum patients who underwent restorative colorectal resections with ghost (prestige/virtual) ileostomy. Before the surgical procedure, all patients were evaluated with detailed history and physical examination and the diagnosis and the stage of disease were confirmed by preoperative colonoscopic biopsy, carcinoembryonic antigen (CEA) levels, contrast-enhanced computed tomography (CECT) of the abdomen/pelvis and chest, and magnetic resonance imaging (MRI) of the pelvis. Regarding the procedure of GI takedown the parameters noted were the easiness of procedure, any procedural difficulty, any intra- or postprocedure complications, procedure time etc.

Patients with rectal cancer stages I to IIIC, according to the American Joint Committee on Cancer's standards for rectal cancer, were included in the study.<sup>23</sup> Carcinoma rectum patients of all age groups and both sexes, operated in elective settings, were included. Alternately, the patients operated in emergency settings having acute bowel obstruction, perforation, and peritonitis, taking immunosuppressant drugs, with stage IV disease, and severe hypoalbuminaemia (serum albumin <2.5g/dl) were excluded from the study. Additionally, the patients with formal CI or with no stoma, those requiring restorative colorectal resections for benign diseases, as well as carcinoma rectum patients with underlying FAP requiring TPC with IPAA were not included. The GI patients having postoperative anastomotic leak and requiring its' maturation were also excluded from this study.

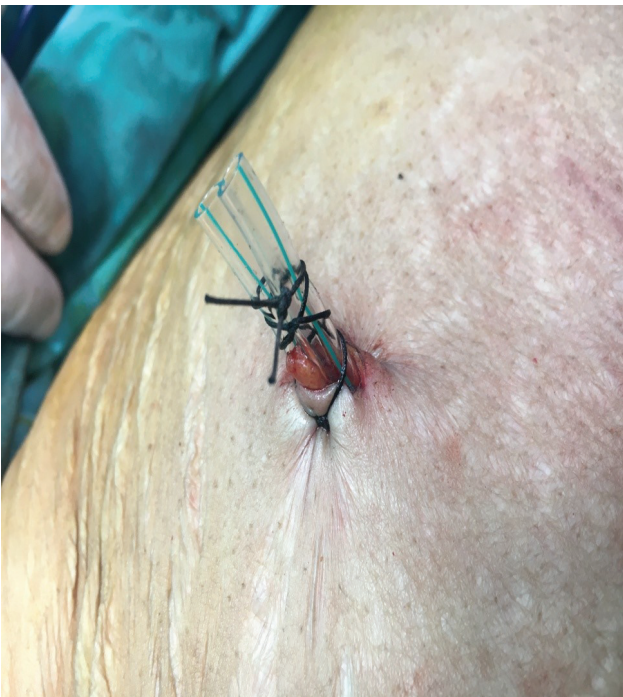## Technique of Release Down of Ghost Ileostomy

All carcinoma rectum patients in this study underwent TME resection (LAR/uLAR) with an adequate circumferential resection margin (CRM), distal and proximal margins followed by colorectal/coloanal end-to-end or end-to-side

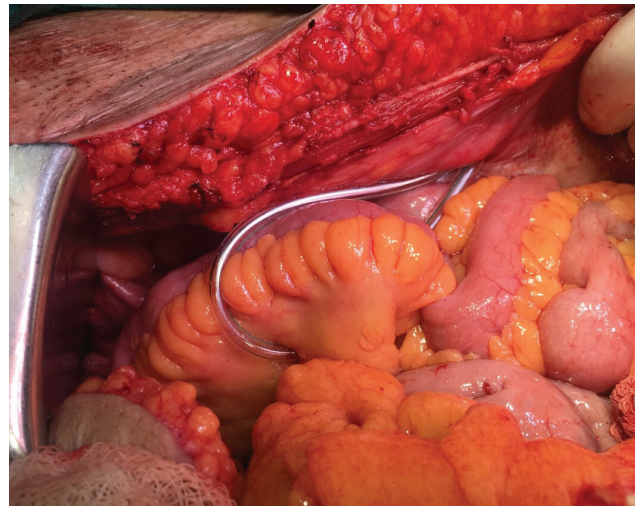
anastomosis using the circular staplers or hand sewn techniques. After the completion of anastomosis, protective GIs were fashioned. In restorative rectal resections, this process averts the necessity and complications of formal CI in more than 80% of carcinoma rectum patients.

However, GI needs to be released down before discharging patients after surgery. Usually, a 10 to 12 Fr Ryle tube or Foley catheter is used for securing the GI loop. The removal of this hanging Ryle tube loop (or any other hanging material) from the abdominal cavity in order to release the tucked ileal loop is referred to as 'release down' of GI. In this regard, it is necessary to ascertain that the patient does not have any anastomotic leak (AL) before performing the GIRD. After confirming by clinical and radiological assessments that there is no AL, the tubing needs to be removed from the abdominal cavity (►Figs. 1 and 2). Preferably, it should be done after 10<sup>th</sup> postoperative day (POD); after ensuring that there are no complications and the bowel movements are normal. The 'release down' of GI can be done as described in following steps:

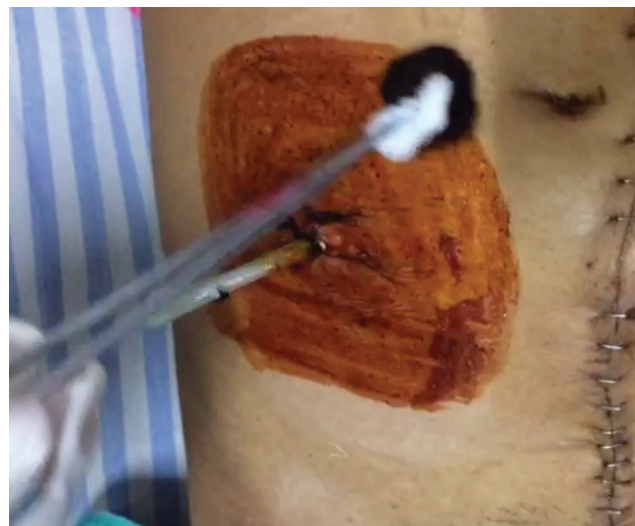- Keep the patient in supine position on their bed in the postoperative ward.
- Uncover the area of GI (usually the right iliac fossa region), taking care to maintain their privacy.
- Gain the patient's confidence for your procedure by giving reassurances, explaining the procedure to them, and seeking consent to proceed.
- After donning the sterile surgical gloves, apply betadine paint on the GI tubing and the skin around it (►Fig. 3). There is no need of use of any local anesthetic agent.
- Cut the fixing suture of the GI tube to free it from the surrounding skin (►Fig. 4).



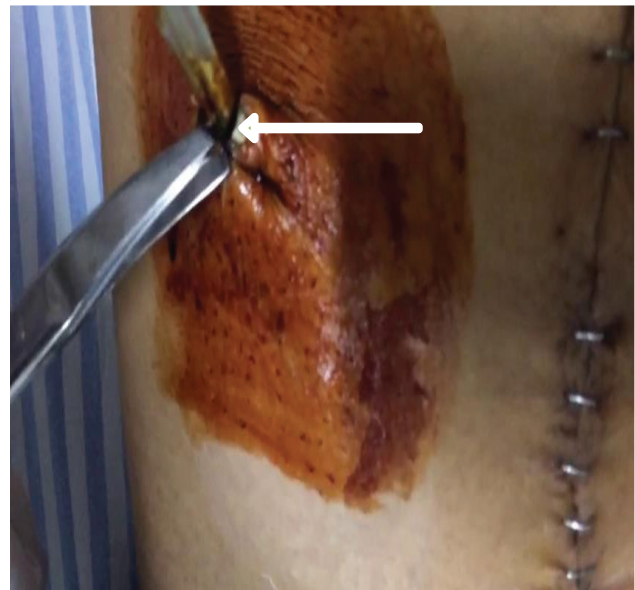
**Fig. 1** Final external appearance of ghost ileostomy.



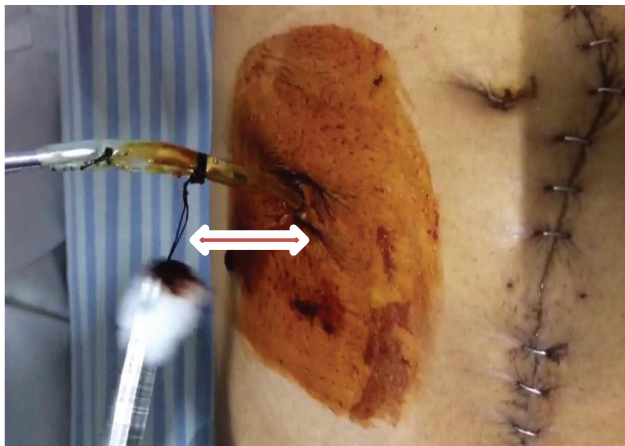
**Fig. 2** Final internal appearance of ghost ileostomy.



**Fig. 3** Bed-side part preparation around the ghost ileostomy tubing.



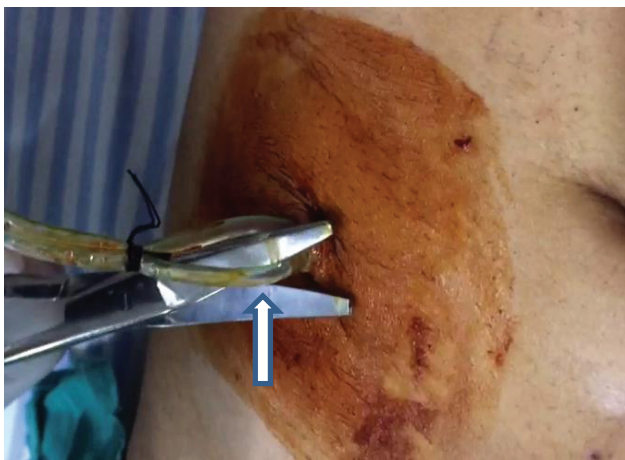
**Fig. 4** Cutting the fixing suture around the ghost ileostomy tubing.



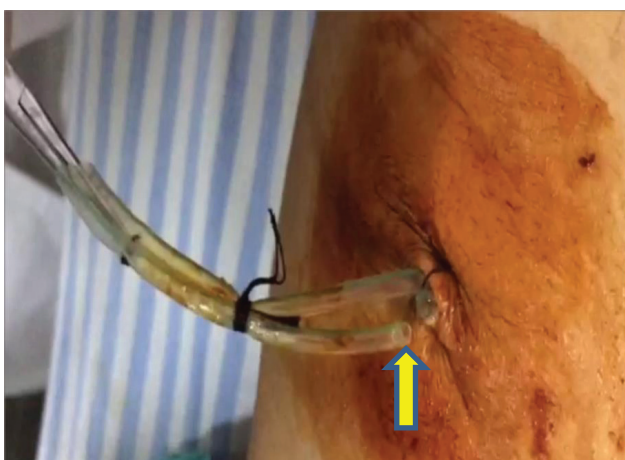
**Fig. 5** Slightly pull out the tubing.

Slightly pull both limbs of the tubing (► **Fig. 5**) and cut one limb with the help of scissors deeper to the skin level (► **Figs. 6 and 7**).

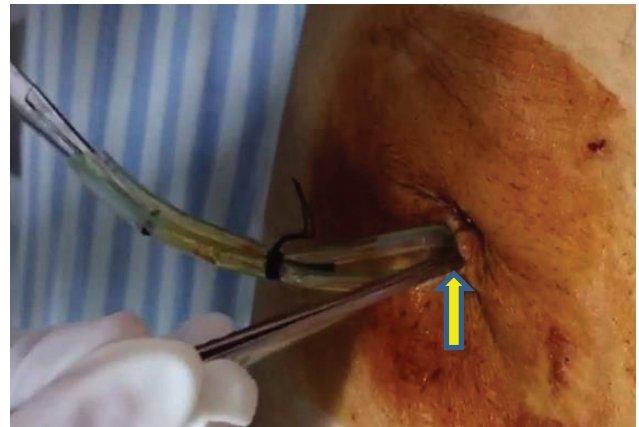- Slightly dip the cut end of the tubing loop into the peritoneal cavity with the help of a forceps (► **Fig. 8**).
- Now gently pull the other end of the tubing from the abdominal cavity to release down the already tucked ileal loop (► **Fig. 9**).



**Fig. 6** Cut one limb of tubing with scissors.

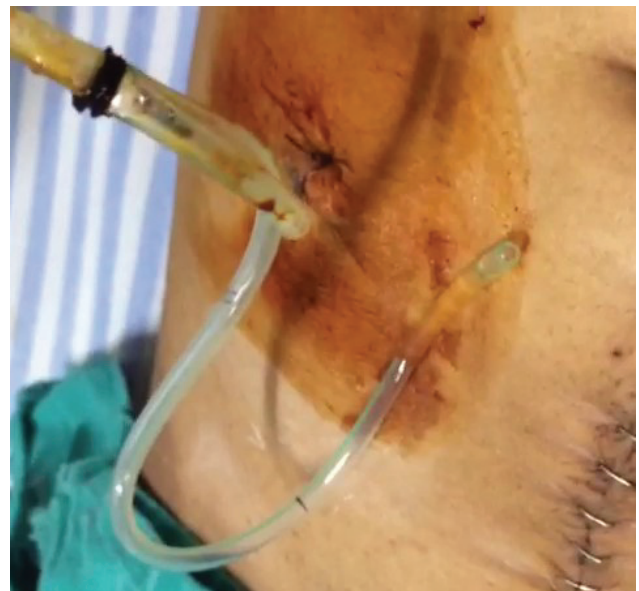

**Fig. 7** One limb of tubing has been cut.

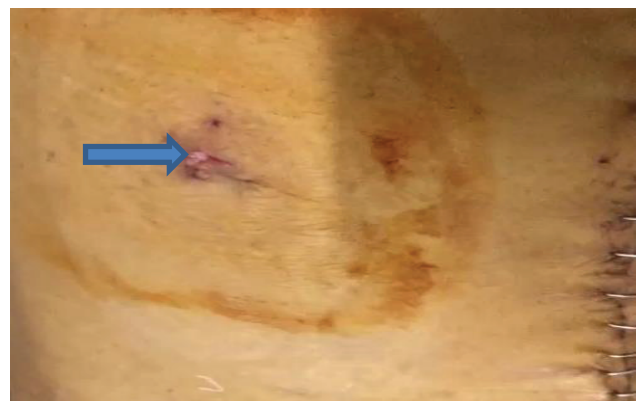


**Fig. 8** Gently dip down the cut end of the tubing with the help of forceps.

- Clean the wound area and apply a small antiseptic dressing (► **Fig. 10**). At the end of the procedure, again reassure the patient and congratulate them on being free from the miseries and morbidities of formal covering stoma.



**Fig. 9** Ghost ileostomy tubing completely pulled out of the abdominal cavity.



**Fig. 10** Final scar (10<sup>th</sup> POD) of ghost ileostomy.

Postprocedure, patients were observed for any complications, morbidity, and mortality, and were followed in the outpatient department, initially weekly and then fortnightly for 1 month.

### Statistical Analysis

The data was compiled; statistically analyzed and the inferences were drawn from the results of the statistical analysis.

### Results

During this approximately 2-year study period and after excluding the patients as described in exclusion criteria in the methods section, a total of 33 patients underwent LAR/uLAR with GI for carcinoma rectum. Out of these patients, 6 (18%) needed maturation (exteriorization) of GI to create a formal loop ileostomy in view of postoperative anastomotic leak. One patient developed paroxysmal supra-ventricular tachycardia (PSVT) and cardiopulmonary arrest on zero POD and died after undergoing resuscitation techniques and mechanical ventilation.

Therefore, only 26 patients actually needed the release down of GI and were included in the final statistical analysis of the study. There were slightly more females than males in this study, with a male to female ratio of 11 to 15. The patients' age ranged from 19 to 75 years, with an average age of 54.84 years. The body mass index (BMI) of patients ranged from 19.53 to 33.46 with an average of 26.31 kg/m<sup>2</sup>.

There were 12 patients with ASA grade I, 13 were ASA grade II and 1 was ASA grade III. The GI in all 26 patients was released down according to the technical steps described above. The GIRD procedure was done only after patients had shown bowel movement postoperatively. It was undertaken between 7<sup>th</sup> to 16<sup>th</sup> PODs after primary surgery with a mean of 9.75 ± 4.25 days.

For most of the patients (22), the GI was released in the same hospital admission in which they were operated for carcinoma rectum. In most cases, it was done a day or so before the patient's discharging from the hospital. However, in some instances (4), patients' GI were released on their first follow up visits. It was possible to release the GI successfully in all patients without the need of any added surgical procedure or incision wound. None of the patients required any local anesthetic injection or additional analgesics. The average time for procedure duration was 5 minutes, and none of the patients had any significant difficulty during GI release.

There were no immediate postprocedure complications. No patients complained of any pain or discomfort during or after the GIRD, even though no local anesthetic solution was used. The GI tubing didn't get stuck during removal in any patient. There was no external or internal bleeding at the GI site. There was no significant surgical site infection (SSI) at the GI tubing site after its removal. After 1-month of follow-up, the GI tubing site scar was less than the abdominal drain site scar, and no ugly scar formation was noticed. None of the patients had any intra- or postprocedure peritoneal or abdominal complications, such as mesenteric bleeding or

hematoma formation, mesenteric injury, mesenteric torsion or intestinal obstruction, GI ileal loop injury, or peritonitis.

### Discussion

The potential disadvantages of a protective stoma include the need for 2<sup>nd</sup> surgery, longer hospital stay, ostomy-related complications and considerable risk of anastomotic leakage at the time of stoma take-down. Moreover, the creation of stoma is hardly acceptable to patients and is an added psychological trauma to patients and care-givers. Therefore, the benefits of a protective stoma in decreasing the rate of AL must be balanced against the morbidity of its construction and closure.<sup>24</sup> The overall incidence of clinical leak in colorectal anastomosis is 8%. Therefore, for the majority of patients (92%), the use of covering stoma has minimal or no clinical usefulness.<sup>25</sup> A recent propensity-matched scoring analysis by Shiomi et al. of about one thousand patients who underwent low anterior resection confirmed that malfunctioning ileostomy does not influence the rate of clinical anastomotic leak but does mitigate its consequences, reducing the need for urgent reoperation.<sup>26</sup>

The GI is relatively a novel concept that bridges out CI to no-ileostomy in LAR. It comes to the rescue of any operating surgeon who may be indecisive regarding CI. It is an alternative to CI in low or medium risk patients for AL. In conclusion, if the anastomosis does not present a risk, but still warrants caution, GI represents the ideal solution as it entails no additional risk and it can be converted, if needed, with extreme ease and total safety. In short, GI prevents all complications related to malfunctioning ileostomy. It is simply a prestage ileostomy that at any time can be externalized if needed.

The creation of GI in LAR for carcinoma rectum patients combines the advantages of a CI without entailing its complications. When compared with formal CI, GI is characterized by shorter recovery, shorter overall hospital stay, lesser degree of total, as well as anastomosis related to morbidity and higher quality of life of the patient.<sup>20,27,28</sup>

Many recent publications suggest that the creation of GI after LAR avoids formal CI in more than 80% of carcinoma rectum patients.<sup>21,22,29</sup> However, none of the papers describe how to ultimately remove or release down the GI in the 80% of patients for whom it doesn't need formal maturation. In our study of 26 patients of restorative resections with GI, we explained in simple and easy steps how to release down this type of ileostomy.

Furthermore, almost none of the published articles describe the outcome of GIRD procedure. During our initial experience with this procedure, we found that GIRD is simple, safe, and quick. It can be done by the patients' bedside, not even needing any local anesthesia nor any additional analgesics. This procedure was done around the 10<sup>th</sup> POD and none of our patients had any complication at GI site. Furthermore, none of our patients had peritoneal or abdominal adversities during or after the procedure.

Gullà et al.<sup>27</sup> carried out a prospective study in 45 patients and made prestage ileostomies in 18 patients (GI group) and

protective ileostomies in 27 patients (CS group). The authors concluded that the GI is feasible, being characterized by shorter recovery, lesser degree of total, as well as anastomosis-related morbidity and higher quality of life for patients and caregivers, when compared to covering stoma. Furthermore, they suggested that GI could be indicated in selected patients that did not present with high risk factors but still require caution for AL for the low level of colorectal anastomosis. As such, GI should be evaluated as an alternative to conventional ileostomy. They also reported that in postoperative courses without complications, in all the GI group, the closure of GI was executed under local anesthesia on POD 10 to 15 after a negative contrast enema.<sup>27</sup>

In their study, Ambe et al. (2018), released the virtual ileostomy between POD 7 and 9, and concluded that in all cases, the postoperative recovery was uneventful.<sup>30</sup>

To report the modified posterior pelvic exenteration technique associated with GI in the treatment of advanced ovarian cancer, Lago et al.<sup>31</sup> concluded that GI may not only prevent the complications related to malfunctioning ileostomy but also presents its advantages in case of AL. Furthermore, if the postoperative course remains uneventful, the GI loop is not removed until discharge from hospital (i.e. 6<sup>th</sup>–9<sup>th</sup> POD). Francesco et al.<sup>32</sup> in their study also concluded that none of the GI patients experienced complications at the site of the procedure.

Miccini et al.<sup>20</sup> implemented a study of 36 cases of carcinoma rectum, whose patients underwent low rectal resection and GI. The authors reported that no local complications related to GI were observed in any of the patients. Furthermore, it was reported that in case of an uncomplicated postoperative course, GI was removed on POD 10 after a negative contrast enema. The authors concluded that if the postoperative course proves uneventful without need of maturation of GI to formal CI, the GI loop can be removed simply by cutting the tape.

## Conclusion

In our initial experience, we concluded that the GIRD is a simple, safe, and quick procedure done around the 10<sup>th</sup> POD. It can easily be performed by the patients' bedside without the need of local anesthesia or analgesics. None of our patients had any complications at the GI's site, or peritoneal or abdominal adhesivities during or after the procedure. In conclusion, if anastomosis does not present a risk, but still warrants caution, GI represents the ideal solution as it entails no additional risk and it can be released down with extreme ease and total safety without the need of any postprocedure care.

### Author Contribution

All authors have contributed equally to the preparation of this article.

### Funding Information

This research project didn't receive any grants from any funding agency in the public, commercial or not-for-profit sectors.

### Conflict of Interests

The authors have no conflict of interests to declare.

### Acknowledgements

We acknowledge the support of all our paramedical staff working in our in-patient ward and operation theatres.

## References

- 1 Enker WE. Total mesorectal excision—the new golden standard of surgery for rectal cancer. *Ann Med* 1997;29(02):127–133
- 2 Heald RJ, Moran BJ, Ryall RDH, Sexton R, MacFarlane JK. Rectal cancer: the Basingstoke experience of total mesorectal excision, 1978–1997. *Arch Surg* 1998;133(08):894–899
- 3 Kapiteijn E, Marijnen CAM, Nagtegaal ID, et al; Dutch Colorectal Cancer Group. Preoperative radiotherapy combined with total mesorectal excision for resectable rectal cancer. *N Engl J Med* 2001;345(09):638–646
- 4 Griffen FD, Knight CD Sr, Whitaker JM, Knight CD Jr. The double stapling technique for low anterior resection. Results, modifications, and observations. *Ann Surg* 1990;211(06):745–751, discussion 751–752
- 5 Mehraj A, Chowdri NA, Nanda S, et al. Validity of APR in the Era of Sphincter Saving Procedures for Low Rectal Cancers. *EC Gastroenterology and Digestive System* 2018;5(03):152–159
- 6 Chude GG, Rayate NV, Patris V, et al. Defunctioning loop ileostomy with low anterior resection for distal rectal cancer: should we make an ileostomy as a routine procedure? A prospective randomized study. *Hepatogastroenterology* 2008;55(86-87):1562–1567
- 7 Tan WS, Tang CL, Shi L, Eu KW. Meta-analysis of defunctioning stomas in low anterior resection for rectal cancer. *Br J Surg* 2009;96(05):462–472
- 8 Matthiessen P, Hallböök O, Rutegård J, Simert G, Sjødahl R. Defunctioning stoma reduces symptomatic anastomotic leakage after low anterior resection of the rectum for cancer: a randomized multicenter trial. *Ann Surg* 2007;246(02):207–214
- 9 Bakx R, Busch OR, Bemelman WA, Veldink GJ, Slors JF, van Lanschot JJ. Morbidity of temporary loop ileostomies. *Dig Surg* 2004;21(04):277–281 [PMID: 15308867 DOI: 10.1159/000080201]
- 10 Cipe G, Erkek B, Kuzu A, Gecim E. Morbidity and mortality after the closure of a protective loop ileostomy: analysis of possible predictors. *Hepatogastroenterology* 2012;59(119):2168–2172 [PMID: 22440245 DOI: 10.5754/hge12115]
- 11 Hallböök O, Matthiessen P, Leinsköld T, Nyström PO, Sjødahl R. Safety of the temporary loop ileostomy. *Colorectal Dis* 2002;4(05):361–364 [PMID: 12780582]
- 12 Kaiser AM, Israelit S, Klaristenfeld D, et al. Morbidity of ostomy takedown. *J Gastrointest Surg* 2008;12(03):437–441 [PMID: 18095033 DOI: 10.1007/s11605-007-0457-8]
- 13 Laurent C, Nobili S, Rullier A, Vendrely V, Saric J, Rullier E. Efforts to improve local control in rectal cancer compromise survival by the potential morbidity of optimal mesorectal excision. *J Am Coll Surg* 2006;203(05):684–691 [PMID: 17084330 DOI: 10.1016/j.jamcollsurg.2006.07.021]
- 14 Law WL, Chu KW, Choi HK. Randomized clinical trial comparing loop ileostomy and loop transverse colostomy for faecal diversion following total mesorectal excision. *Br J Surg* 2002;89(06):704–708 [PMID: 12027979 DOI: 10.1046/j.1365-2168.2002.02082.x]
- 15 van Westreenen HL, Visser A, Tanis PJ, Bemelman WA. Morbidity related to defunctioning ileostomy closure after ileal pouch-anal anastomosis and low colonic anastomosis. *Int J Colorectal Dis* 2012;27(01):49–54 [PMID: 21761119 DOI: 10.1007/s00384-011-1276-7]
- 16 Åkesson O, Syk I, Lindmark G, Buchwald P. Morbidity related to defunctioning loop ileostomy in low anterior resection. *Int J Colorectal Dis* 2012;27(12):1619–1623

- 17 Floodeen H, Lindgren R, Matthiessen P. When are defunctioning stomas in rectal cancer surgery really reversed? Results from a population-based single center experience. *Scand J Surg* 2013; 102(04):246–250
- 18 Lindgren R, Hallböök O, Rutegård J, Sjödahl R, Matthiessen P. What is the risk for a permanent stoma after low anterior resection of the rectum for cancer? A six-year follow-up of a multicenter trial. *Dis Colon Rectum* 2011;54(01):41–47
- 19 Khan MA, Chowdri NA, Wani RA, et al. Technique of Ghost (Khatith) ileostomy: Our Experience and Guidelines. *Ann Colorectal Res.* 2021; 9(02):51–57. Doi: 10.30476/ACRR.2021.89835.1082
- 20 Miccini M, Amore Bonapasta S, Gregori M, Barillari P, Tocchi A. Ghost ileostomy: real and potential advantages. *Am J Surg* 2010; 200(04):e55–e57. Doi: 10.1016/j.amjsurg.2009.12.017
- 21 Sacchi M, Legge PD, Picozzi P, Papa F, Giovanni CL, Greco L. Virtual ileostomy following TME and primary sphincter-saving reconstruction for rectal cancer. *Hepatogastroenterology* 2007;54(78):1676–1678
- 22 Flor-Lorente B, Sánchez-Guillén L, Pellino G, et al. “Virtual ileostomy” combined with early endoscopy to avoid a diversion ileostomy in low or ultralow colorectal anastomoses. A preliminary report. *Langenbecks Arch Surg* 2019;404(03):375–383. Doi: 10.1007/s00423-019-01776-z
- 23 Edge SB, Compton CC. The American Joint Committee on Cancer: the 7th edition of the AJCC cancer staging manual and the future of TNM. *Ann Surg Oncol* 2010;17(06):1471–1474
- 24 Pakkastie TE, Ovaska JT, Pekkala ES, Luukkonen PE, Järvinen HJ. A randomised study of colostomies in low colorectal anastomoses. *Eur J Surg* 1997;163(12):929–933
- 25 Hautefeuille P, Valleur P, Perniceni T, et al. Functional and oncologic results after coloanal anastomosis for low rectal carcinoma. *Ann Surg* 1988;207(01):61–64
- 26 Shiomi A, Ito M, Maeda K, et al. Effects of a diverting stoma on symptomatic anastomotic leakage after low anterior resection for rectal cancer: a propensity score matching analysis of 1,014 consecutive patients. *J Am Coll Surg* 2015;220(02): 186–194
- 27 Gullà N, Trastulli S, Boselli C, et al. Ghost ileostomy after anterior resection for rectal cancer: a preliminary experience. *Langenbecks Arch Surg* 2011;396(07):997–1007
- 28 Mori L, Vita M, Razzetta F, Meinero P, D'Ambrosio G. Ghost ileostomy in anterior resection for rectal carcinoma: is it worthwhile? *Dis Colon Rectum* 2013;56(01):29–34
- 29 Khan MA, Chowdri NA, Parray FQ, et al. Role of ghost ileostomy in low anterior resection for carcinoma rectum. *ANZ J Surg* 2021;91 (05):1039–1039. Doi: 10.1111/ans.16573
- 30 Ambe PC, Zirngibl H, Möslein G. Routine Virtual Ileostomy Following Restorative Proctocolectomy for Familial Adenomatous Polyposis. *World J Surg* 2018;42(06):1867–1871. Doi: 10.1007/s00268-017-4365-0
- 31 Lago V, Domingo S, Matute L, Padilla P, Flor B, García-Granero Á. Ghost ileostomy in advanced ovarian cancer. *Gynecol Oncol* 2017; 147(02):488. Doi: 10.1016/j.ygyno.2017.08.017
- 32 Mari FS, Di Cesare T, Novi L, et al. Does ghost ileostomy have a role in the laparoscopic rectal surgery era? A randomized controlled trial. *Surg Endosc* 2015;29(09):2590–2597. Doi: 10.1007/s00464-014-3974-z