



Original Article

Microscopic analysis of patients with chronic diarrhea without macroscopic disease[☆]



Ary Santos Silva^{a,*}, Doryane Maria dos Reis Lima^{a,b}

^a Hospital São Lucas, Faculdade Assis Gurgacz (FAG), Cascavel, PR, Brazil

^b Sector of Anorectal Physiology, Gastroclínica Cascavel, Cascavel, PR, Brazil

ARTICLE INFO

Article history:

Received 18 June 2015

Accepted 28 August 2015

Available online 21 December 2015

Keywords:

Chronic diarrhea

Microscopic colitis

Colonoscopy

ABSTRACT

Background: Colonoscopy is part of the current diagnostic armamentarium. However, in some patients with chronic diarrhea, a colonoscopy may show normal mucosa; in these cases, serial biopsies can provide important information for the diagnosis and treatment of patients.

Aim: To analyze patients with chronic diarrhea having a macroscopically normal colonoscopy, by evaluating histological changes.

Methods: 30 patients with chronic diarrhea and normal colonoscopy were prospectively evaluated and submitted to serial biopsies of the terminal ileum, ascending colon and rectum.

Results: The sample of 30 patients showed a ratio of 18 men (60%) and 12 women (40%). On histological types, it was found that 13 patients (43.3%) had lymphoid hyperplasia, eosinophilic inflammation in 4 (13.3%), nonspecific inflammation in 4 (13.3%), regenerative changes in 3 (10%), lymphocytic colitis in 2 (6.6%) and changes consistent with Crohn's disease in 1 (3.3%).

Conclusions: One can observe that even chronic diarrhea patients, without other associated factors, benefited from colonoscopy with biopsy, because it held the etiologic diagnosis in some cases as also excluded by histopathology. It was noticed that the frequency of patients with altered biopsy and less dragged diarrheal episodes (84.2%) was large, should consider their achievement.

© 2015 Sociedade Brasileira de Coloproctologia. Published by Elsevier Editora Ltda. All rights reserved.

[☆] Study conducted at the General Surgery Service, Hospital São Lucas, Faculty Assisi Gurgacz (FAG); Concurrent with Gastric Cascavel, Cascavel, PR, Brazil.

* Corresponding author.

E-mail: drarysantos@gmail.com (A.S. Silva).

<http://dx.doi.org/10.1016/j.jcol.2015.08.009>

2237-9363/© 2015 Sociedade Brasileira de Coloproctologia. Published by Elsevier Editora Ltda. All rights reserved.

Análise microscópica de pacientes com diarreia crônica sem doença macroscópica

R E S U M O

Palavras-chave:

Diarreia crônica
Colite microscópica
Colonoscopia

Introdução: A colonoscopia faz parte do arsenal de diagnóstico atual. Porém, em alguns pacientes com diarreia crônica, a colonoscopia pode evidenciar mucosa normal; nesses casos biópsias seriadas podem trazer informações importantes para o diagnóstico e tratamento dos pacientes.

Objetivo: Analisar pacientes com diarreia crônica submetidos à colonoscopia macroscopicamente normal, avaliando assim histologicamente as alterações.

Métodos: Análise prospectiva da histologia 30 pacientes com diarreia crônica e colonoscopias normais, submetidos a biópsias seriadas de íleo terminal, cólon ascendente e reto.

Resultados: A amostra de 30 pacientes mostrou uma proporção de 18 homens (60%) e 12 mulheres (40%). Sobre os tipos de alterações histológicas, foi verificado que 13 pacientes (43,3%) apresentaram hiperplasia linfóide, inflamação eosinofílica em 4 (13,3%), inflamação inespecífica em 4 (13,3%), alterações regenerativas em 3 (10%), colite linfocítica em 2 (6,6%) e alterações compatíveis com Doença de Crohn em 1 (3,3%).

Conclusões: Observou-se que mesmo pacientes com diarreia crônica, sem outros fatores associados, beneficiaram-se da colonoscopia com biópsia, pois a mesma realizou o diagnóstico etiológico em alguns casos como também o excluiu através da histopatologia. Verificou-se que a frequência de pacientes com biópsia alterada e quadros diarreicos menos arrastados (84,2%) foi grande, devendo-se considerar a realização do exame.

© 2015 Sociedade Brasileira de Coloproctologia. Publicado por Elsevier Editora Ltda.
Todos os direitos reservados.

Introduction

Chronic diarrhea is a common disorder, characterized by a course longer than 30 days; on the other hand, it brings discomfort – not only physical but also social – to the patient.¹ Considering that young adults, constituted by a population of individuals who, in their majority, are healthy, when exposed to symptoms such as diarrhea tend to belittle the event, postponing this diagnosis. But often this diagnosis can be very complex and comprehensive, as it may reflect numerous infectious, endocrine-metabolic, neoplastic, functional and drug-derived etiologies.^{1,2}

Currently, colonoscopy is one of the most comprehensive research methods of colorectal diseases.^{2,3} However, in some patients with chronic diarrhea, this method may show a normal mucosa. In such cases, obtaining serial biopsies can provide important information for the diagnosis and treatment.^{4,5} This microscopic analysis is very useful, both for the diagnosis of inflammatory bowel diseases and irritable bowel syndrome, and for the differential diagnosis for lymphocytic, collagenous, actinic, and ischemic colitis, besides cases of infectious colitis (tuberculosis, amebiasis, histoplasmosis, and pseudomembranous colitis) and infections associated with acquired immune deficiency syndrome, by enabling the visualization of mucosa and allowing the collection of material for histopathological analysis.^{3,6}

Thus, the search for microscopic changes in young patients is very useful, since the conditions (including those most severe ones, such as inflammatory bowel disease) can be diagnosed only by histopathology, considering that these

conditions are in such a nascent stage, at the point of an absence of macroscopic lesions.

Objectives

To analyze patients with chronic diarrhea with a macroscopically normal colonoscopy, with the aim to identify the variables of age, gender, duration of diarrhea and histopathological changes, and draw a parallel between such variables.

Methodology

This study was approved by the Research Ethics Committee, Faculdade Assis Gurgacz (FAG), opinion number 1026986/2015 – CEP/FAG. This is a prospective study in which data were stored in the database of the Clinic (in the form of medical charts) and collected in a checklist. Thirty patients with chronic diarrhea, undergoing colonoscopies and serial biopsies from terminal ileum, ascending colon and rectum were selected at Gastroclínica Cascavel – PR from October 2014 to March 2015. The inclusion criteria were: young adults (18–50 years old) with diarrhea lasting more than 30 days, without endoscopic mucosal changes and considered as colonoscopically normal subjects. The samples were subjected to pathologists' assessment according to the Atlas of Nontumor Pathology – Gastrointestinal Diseases (2007)⁵: (1) inflammation or lymphocytic colitis: increased number of intraepithelial lymphocytes in the superficial epithelium with at least 20 lymphocytes per 100 epithelial cells (mean 25–32);

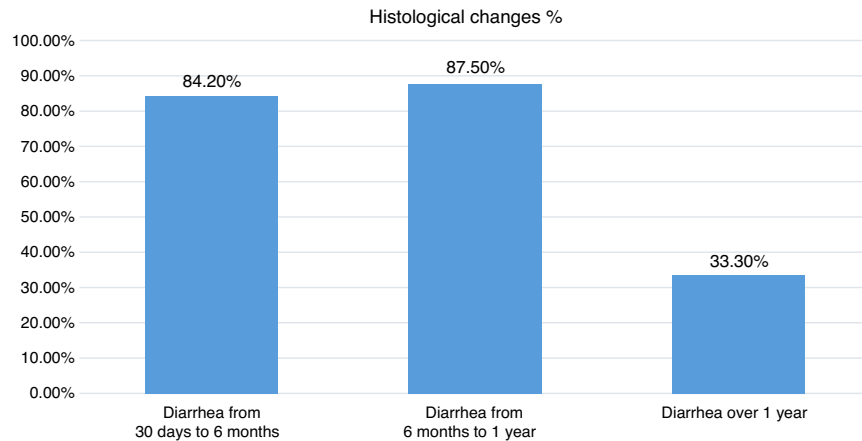


Fig. 1 – Incidence of histological changes with respect to diarrhea duration.

(2) unspecific inflammation: findings that do not meet the criteria of a specific inflammation, however exceeding the limits of a normal or reactional mucosa; (3) lymphoid hyperplasia: activation of mucosa proper lymphoid follicles, with enlargement of the germinal center; (4) eosinophilic colitis: an increase of 20 eosinophils per field, compromising the sub-mucosa and the proper muscle layer.

HIV-positive subjects, individuals with lactose intolerance or celiac disease, or with inflammatory bowel disease previously diagnosed, patients with diverticular disease and its complications, as well as patients with incomplete data, were excluded from this study. The parameters evaluated were: age, gender, duration of diarrhea, medications in use, and results of microscopy. Data were statistically analyzed for significance and compared to the available literature for discussion.

Results

Regarding gender, the sample was composed of 18 men (60%) and 12 women (40%). With regard to age, 11 patients (36.6%) were aged 18–35 years and 19 patients (63.3%) were aged 35–50 years, with a mean age of 30.5 years. It was found that 20 patients (66.6%) did not use any chronic medication, and 10 patients (33.3%) were using continuous medication. Of these latter patients, 3 were using oral contraceptives, 3 were on hypertensives (losartan and propranolol), 2 were on omeprazole, 1 was in use of levothyroxine, and 1 was a multivitamin user. No patient related any of these pharmacological products with the onset of diarrheal symptoms.

Regarding timeline of symptoms, 19 patients (63.3%) were suffering diarrhea lasting from 30 days to 6 months, 8 patients (26.6%) from 6 months to 1 year, and 3 patients (10%) for more than 1 year. The mean duration of symptoms was 3 months. With regard to histology, there were changes in 84.2% of patients with diarrhea lasting from 30 days to 6 months, in 87.5% of those with diarrhea from 6 months to 1 year, and in 33.3% of patients with diarrhea lasting over 1 year (Fig. 1).

As to histopathology, it was found that 4 patients (13.3%) exhibited no change and 26 patients (86.6%) exhibited some histological change. Among those with changes, 5 patients (19.2%) exhibited changes in more than one segment biopsied:

1 patient (3.84%) with changes in all three segments (distal ileum, ascending colon, and rectum) and 4 patients (15, 38%) presented terminal ileum and rectum changes.

As to the types of histologic changes, it was found that 13 patients (50%) exhibited lymphoid hyperplasia: eosinophilic inflammation in 4 (15.38%) patients, unspecific inflammation in 4 (15.38%) patients, regenerative changes in 3 (11.53%) patients, lymphocytic colitis in 2 (7.69%) patients, and changes consistent with Crohn's disease in 1 (3.84%) patient (Fig. 2). Terminal ileum was the most affected segment, with changes observed in 12 patients (46.1%); lymphoid hyperplasia was the most commonly observed change, followed by changes in the ascending colon in 9 (34.6%) patients, with eosinophilic inflammation as the most common change (with rectum) in 5 (19.2%) patients, with predominance of regenerative changes (Table 1).

Discussion

Considering that this is a population composed mostly of healthy, young adults, when exposed to symptoms such as diarrhea, tend to neglect its importance, delaying the diagnosis. However, often the diagnosis can be very complex and wide-ranging, thanks to the potential for numerous (infectious, endocrine-metabolic, neoplastic, functional and drug) etiologies.^{4,6} Colonoscopy has been increasingly used in these patients, especially in those with a history of chronic diarrhea, and for whom one cannot get to a diagnosis with other methods.⁶ With the use of colonoscopy, it is possible to analyze the presence of macroscopic lesions; but in some patients with chronic diarrhea, colonoscopy may show only normal mucosa. In such cases, performing serial biopsies can result in important information for the diagnosis and treatment of these patients.^{4,6}

Although macroscopically the colonoscopies were normal in our study, 86.6% of patients had some histological change. Even considering such a small sample, this figure demonstrates the importance of an investigation into cases of chronic diarrhea. An histological study⁷ of colonic mucosa of patients with diarrhea and with a normal colonoscopy, found 110/162 (67.9%) patients with normal histology; 17/162

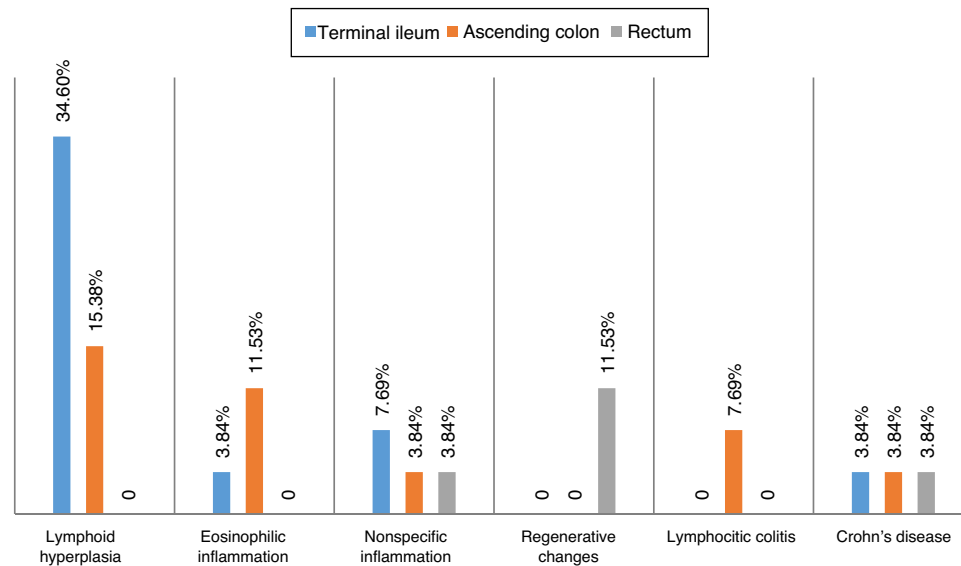


Fig. 2 – Pathological changes (in percentages) found in biopsies of the terminal ileum, ascending colon and rectum biopsies.

(10.5%) with histopathological findings with potential clinical significance, suggestive of collagenous colitis, lymphocytic colitis and melanosis coli; and 35/119 (21.6%) with defined histopathological findings: collagenous colitis, lymphocytic colitis, minimum microscopic colitis, eosinophilic colitis, pericrypt eosinophilic enterocolitis, intestinal spirochaetosis, schistosomiasis, and Crohn's disease – findings similar to those diagnoses found in our study, showing that microscopic colitis and incipient inflammatory bowel disease can be more often diagnosed.

In 2002, one case report of collagenous colitis in a patient with chronic diarrhea of unknown cause associated with the use of lansoprazole was published.⁸ The histopathological changes resolved with the discontinuation of the medication and relapsed with its reintroduction. We observed no association with antidiarrheal medications; but in some cases, drug interaction is an important factor.

Autoimmunity is a condition common to several diseases, being also observed in lymphocytic colitis. A study was conducted⁹ with colonoscopies of 50 patients with Hashimoto's thyroiditis, 5 of them with diarrhea. Of these 50 patients, 20 (40%) had intestinal histological changes consistent with lymphocytic colitis. The authors of this study concluded in favor of a high incidence of lymphocytic colitis

in patients with Hashimoto's thyroiditis, although most of them were asymptomatic, which leads us again to dwell on the importance of using the history of other previous diseases – specially autoimmune diseases – as a starting point in the investigation.

Parallel to the discussion on the need, or not, for routine biopsies in patients with diarrhea with normal colonoscopy, lies the debate on the need, or not, to examine and biopsy the terminal ileum.¹⁰ Other authors¹¹ retrospectively studied 683 ileocolonoscopies, finding that 499 (73.06%) had normal results, 123 (18%) exhibited lymphoid hyperplasia, and 25 (3.66%) suffered from Crohn's disease, demonstrating a high percentage of coincidence between endoscopic and histopathological diagnoses (96.87% in normal ileocolonoscopies, 77.77% in lymphoid hyperplasia, and 77.27% in Crohn's disease), which revealed large numbers of patients with lymphoid hyperplasia, as occurred in our study, and especially in the case of the terminal ileum that, in our patients, was the most affected segment.

What can be said is that the study and treatment of patients with chronic diarrhea are not an easy task, often depending on monitoring of several steps. Several diseases are included in the checklist of differential diagnoses, and, among them, microscopic colitis (collagenous colitis and

Table 1 – Number of alterations found, according to the affected segment and the most frequent injury.

Affected segment	Patients	Most frequent injuries	Number of cases
Terminal ileum, ascending colon and rectum	1	Inflammation suggestive of Chron's disease	1
Terminal ileum and rectum	4	Lymphoid hyperplasia	4
Terminal ileum	7	Lymphoid hyperplasia	7
Ascending colon	8	Eosinophilic inflammation	4
Rectum ^a	0		0

^a No patient was found with only rectal changes in his/her biopsied material.

lymphocytic colitis) in patients with normal macroscopic appearance on their colonoscopy.¹²⁻¹⁴ In cases of collagenous colitis, a thickening of the basement membrane with increased collagen tissue at this level can be observed, and in cases of lymphocytic colitis there is an increased inflammatory infiltrate into the lamina propria, with a predominance of cytotoxic CD8 lymphocytes.¹³⁻¹⁵ These two conditions can cause chronic or intermittent diarrhea, being diagnosed only by histopathology. In suspected cases of microscopic colitis, the entire colon should be biopsied for histopathology.^{15,16}

In analyzing the histopathology of the cases, we found that there is no uniform pattern for reporting both positive data and the presence of inflammatory cell infiltrate or cryptal damage, nor for negative data, for instance, the presence of granulomas, fibrosis, micro-organisms, abscesses, malignancy, specificity, parasites, etc.¹⁴⁻¹⁷

One gets the impression that pathologists do not give due importance to the necessary measurements and countings for characterization, especially in cases of collagenous colitis and lymphocytic colitis, conditions that, from what was discussed, can justify the presence of diarrhea, even with a normal colonoscopy.¹⁸⁻²⁰ Similar to what was done for gastritis with the use of the Sydney classification,²¹ a future idea to be discussed among clinicians, pathologists and endoscopists is the search for some histopathological uniformity for the diagnosis of microscopic colitis.²²⁻²⁴

Conclusion

Microscopic analysis in patients with chronic diarrhea with normal macroscopic results revealed the frequent occurrence of lymphoid hyperplasia, and that the most affected intestinal segment was the terminal ileum. The most affected sites were terminal ileum and ascending colon (21/26 patients), suggesting that these areas deserve to be remembered in the investigation, regardless of their macroscopic appearance.

Conflicts of interest

The authors declare no conflicts of interest.

Acknowledgements

Our sincere thanks to Dr. Carlos Floriano de Moraes from Laboratório APC, and to Dr. Alexandre Galvão Bueno from Laboratório Anatom, for their review of slides and cellular recount with review of pathology reports; and also to Mrs. Claudia Duarte, head of the scientific sector of Gastroclínica Cascavel, for her help in the selection and organization of patient data.

REFERENCES

1. American Gastroenterological Association Medical Position Statement. Guidelines for the evaluation and management of chronic diarrhea. *Gastroenterology*. 1999;6:146-63.
2. Fine KD, Schiller LR. AGA technical review on the evaluation and management of chronic diarrhea. *Gastroenterology*. 1999;116:1464.

3. Ferreira S, Magalhães M, Cotrim I, Pereira A, Saraiva R. Diarreia crônica. *J Port Gastreterol*. 2012;19:140-2.
4. Rafi UD, Manzar Z, Mujeeb-Ur-Rehman AB. Chronic diarrhea: large gut causes. *Prof Med J*. 2008;15:479-85.
5. Noffsinger A, Fenoglio-Preiser CM, Maru D, Gilinsky N. Gastrointestinal diseases, AFIP atlas of nontumor pathology. First series, vol. 5; 2007. p. 656-8.
6. Nogueira da Silva JG. Colonoscopia nos pacientes com diarreia crônica. *Rev Gastroenterol Fugesp*. 2000.
7. da Silva JG, De Brito T, Cintra Damiao AO, Laudanna AA, Sipahi AM. Histologic study of colonic mucosa in patients with chronic diarrhea and normal colonoscopic findings. *J Clin Gastroenterol*. 2006;40:44-8.
8. Wilcox GM, Mattia A. Collagenous colitis associated with lansoprazole. *J Clin Gastroenterol*. 2002;34:164-6.
9. Cindoruk M, Tuncer C, Dursun A, Yetkin I, Karakan T, Kahir N, et al. Increased colonic intraepithelial lymphocytes in patients with Hashimoto's thyroiditis. *J Clin Gastroenterol*. 2002;34:237-9.
10. Cuvelier C, Demetter P, Mielants H, Veys EM, De Vos M. Interpretation of ileal biopsies: morphological features in normal and diseased mucosa. *Histopathology*. 2001;38:1-12.
11. González AH, Garcia OMH, Jimenez G. Estudio endoscópico del íleon terminal. *Rev Cuba Med*. 2002;41:141-5.
12. Elliot VJ, Bateman AC, Green B. The endoscopically normal colon when is mapping biopsy histopathologically justifiable? *Frontline Gastroenterol*. 2012;3:104-8.
13. Howat A, Boyd K, Douce G. Histopathology and cytopathology of limited or no clinical value. The Royal College of Pathologists. 2 ed. London: RCPATH; 2005.
14. Koksar AR, Boga S, Alkim H, Ergun M, Bayram M, Sakiz D. How does a biopsy of endoscopically normal terminal ileum contribute to the diagnosis? Which patients should undergo biopsy? [série online]. *Libyan J Med*. 2014;9:23441.
15. Melo MMC, Cury PM, Ronch LS, Gonçalves-Filho FA, Cunrath GS, Netinho JG. Íleo terminal de pacientes submetidos à colonoscopia: aspectos endoscópicos, histológicos e clínicos. *Arq Gastroenterol São Paulo*. 2009;46:102-6.
16. Melo MMC, Netinho JG. Aspectos endoscópicos no diagnóstico de doenças que acometem o íleo terminal. *Rev Col Bras Cir*. 2010;37:234-9.
17. Münch A, Langner C. Microscopic colitis: clinical and pathologic perspectives. Linköping, Sweden/Graz, Austria: Division of Gastroenterology and Hepatology, Department of Clinical and Experimental Medicine, Faculty of Health Science, Linköpings University/Institute of Pathology, Medical University of Graz; 2014.
18. Nahas SC, Alves PA, Nahas OS, Habr-Gama A, Pinotti HW. Colonoscopia como método diagnóstico e terapêutico na doença do intestino grosso no Hospital das Clínicas da Faculdade de Medicina da Universidade de São Paulo. *Rev Bras Coloproctol*. 1989;9:20.
19. Nahas SC, Alves PRA, Araújo SEA, Sousa JAHS, Sobrado JCW, Nahas CSR, et al. Emprego da colonoscopia como método diagnóstico e terapêutico das doenças do intestino grosso. Resultados observados em 1.715 exames. *Rev Hosp Clín Fac Med São Paulo*. 1998;53:117-21.
20. Nahas SC, Oliveira FDES, Araújo SE, Lourenção JL, Sobrado JCW, Nahas CSR, et al. Colonoscopia: indicações, contraindicações e complicações. *Rev Hosp Clín Fac Med São Paulo*. 1998;53:91-9.
21. Mainguet P, Jouret A, Haot J. The Sidney System, a new classification of gastritis. *Gastroenterol Clin Biol*. 1993;17:T13-7.
22. Nahas SC, Marques CFS, Araújo AS, Aisaka AA, Nahas CSR, Pinto RA, et al. Colonoscopia como método diagnóstico e terapêutico das moléstias do intestino grosso: análise de 2567 exames. *Arq Gastroenterol*. 2005;42:77-82.

23. Nossa FLC, Paula NBLBB, Todinov LR, Barreto NPF, Silva JH, Formiga GJS. Colonoscopia diagnóstica e terapêutica. Avaliação das indicações e resultados. Rev Bras Coloproctol. 1999;19:168-71.
24. Silva JG, Brito T, Cintra DAO, Laudanna AA, Sipahi AM. Histologic study of colonic mucosa in patients with chronic diarrhea and normal colonoscopic findings. J Clin Gastroenterol. 2006;40:44-8.