



# Journal of Coloproctology

www.jcol.org.br



## Original Article

# Cell therapy in experimental model of inflammatory bowel disease<sup>☆</sup>



Mônica Yonashiro Marcelino<sup>a</sup>, Natália Langenfeld Fuoco<sup>a</sup>,  
Ana Elise Valencise Quaglio<sup>b</sup>, Renata Aparecida de Camargo Bittencourt<sup>c</sup>,  
Bruna Cambraia Garms<sup>d</sup>, Thaís Helena da Motta Conceição<sup>e</sup>, Luiz Claudio Di Stasi<sup>b</sup>,  
João Tadeu Ribeiro-Paes<sup>e,\*</sup>

<sup>a</sup> Institute of Biomedical Sciences, Universidade de São Paulo, São Paulo, SP, Brazil

<sup>b</sup> Department of Pharmacology, Biosciences Institute, Universidade Estadual Paulista, Botucatu, SP, Brazil

<sup>c</sup> Institute of Health Sciences, Universidade Paulista, Assis, SP, Brazil

<sup>d</sup> School of Biological and Environmental Sciences, Universidade Federal da Grande Dourados, Dourados, MS, Brazil

<sup>e</sup> Department of Biological Sciences, Universidade Estadual Paulista, Assis, SP, Brazil

## ARTICLE INFO

### Article history:

Received 15 January 2014

Accepted 5 March 2014

Available online 2 July 2014

### Keywords:

Inflammatory bowel disease

Stem cells

Adipose tissue

Cell therapy

## ABSTRACT

Inflammatory bowel disease, which mainly involves Crohn's disease and ulcerative colitis, is an inflammatory condition of the mucosa that can afflict any segment of the gastrointestinal tract. Despite the fact that the existing therapies result in improvement in patient's symptomatology and quality of life, there is no curative treatment. Surgical treatment involves complex procedures associated with high morbidity and mortality rates. In this context, cell therapy with stem cells has emerged as a treatment with broad potential applicability. In this study, we intended to verify the efficacy of transplantation of adipose tissue-derived stem cells in rats with intestinal inflammation induced by trinitrobenzenesulfonic acid. The cell population was isolated from the adipose tissue of inguinal region of rats and processed for culture by mechanical dissociation. The animals were evaluated with respect to clinical and biochemical aspects, as well as by macroscopic, microscopic and histological analyses. In the experimental model of bowel inflammation by 2,4,6-trinitrobenzenesulfonic acid, the infusion of adipose tissue significantly reduced the presence of adhesions in the colon and adjacent organs and decreased the activity of myeloperoxidase, a marker of neutrophil infiltration in the injured mucosa. The results suggest that cell therapy with adipose tissue can promote and/or accelerate the regeneration of damaged intestinal mucosa. It is concluded that the presence of adhesions and the determination of myeloperoxidase activity provide indications that adipose tissue can promote and/or accelerate the regeneration of inflammatory bowel mucosa.

© 2014 Sociedade Brasileira de Coloproctologia. Published by Elsevier Editora Ltda. All rights reserved.

<sup>☆</sup> Study conducted at Department of Biological Sciences, Universidade Estadual Paulista (UNESP), Assis Campus, Assis, SP, Brazil.

\* Corresponding author.

E-mail: [jtrpaes@yahoo.com.br](mailto:jtrpaes@yahoo.com.br), [joao.paes@pq.cnpq.br](mailto:joao.paes@pq.cnpq.br) (J.T. Ribeiro-Paes).

<http://dx.doi.org/10.1016/j.jcol.2014.06.004>

2237-9363/© 2014 Sociedade Brasileira de Coloproctologia. Published by Elsevier Editora Ltda. All rights reserved.

## Terapia celular em modelo experimental de doença inflamatória intestinal

### R E S U M O

#### Palavras-chave:

Doença Inflamatória Intestinal  
Células-tronco  
Tecido Adiposo  
Terapia Celular

A Doença Inflamatória Intestinal (DII), consistindo principalmente da doença de Crohn e retocolite ulcerativa, é uma condição inflamatória da mucosa que pode acometer qualquer segmento do trato gastrointestinal. Apesar das terapias existentes resultarem na melhora dos sintomas e da qualidade de vida dos pacientes, não há nenhum tratamento curativo. O tratamento cirúrgico envolve procedimentos complexos associados a altas taxas de morbimortalidade. Neste contexto, a terapia celular com células-tronco desponta como opção de tratamento potencialmente promissora. Em função destes aspectos, pretendeu-se, no presente estudo, verificar a eficácia do transplante de células-tronco derivadas do tecido adiposo (ASC) em ratos com inflamação intestinal induzida por ácido trinitrobenzenosulfônico (TNBS). As ASCs foram obtidas por dissociação mecânica do tecido adiposo da região inguinal de ratos e processadas para cultivo. Os animais foram avaliados, considerando-se os aspectos clínicos e bioquímicos, além de análises macroscópica, microscópica e histológica. No modelo de inflamação intestinal induzida por TNBS, a infusão de ASCs reduziu significativamente a presença de aderências entre o cólon e órgãos adjacentes, bem como diminuiu a atividade da mieloperoxidase (MPO), um marcador da infiltração de neutrófilos na mucosa lesada. Os resultados obtidos permitem concluir que a terapia celular com ASCs pode promover e/ou acelerar o processo de regeneração da mucosa intestinal inflamada.

© 2014 Sociedade Brasileira de Coloproctologia. Publicado por Elsevier Editora Ltda.

Todos os direitos reservados.

## Introduction

Inflammatory bowel disease (IBD) comprises two nosological entities of chronic and recurrent nature: Crohn's disease (CD) and ulcerative rectocolitis (URC).<sup>1</sup> CD is a transmural inflammatory condition of mucosa that can affect any segment of the gastrointestinal tract.<sup>2,3</sup> Unlike CD, URC is a disease characterized by diffuse inflammation of colonic mucosa. URC affects the rectum (95% of cases) and proximal portions of the colon, in a symmetric and continuous manner.<sup>4,5</sup>

Despite the introduction of new clinical therapeutic approaches and their contribution to improve the quality of life of patients with IBD and/or in the prevention of recurrence, there is no definitive clinical curative treatment. The surgical treatment, in turn, involves complex procedures associated with high rates of morbidity and mortality and postoperative complications.<sup>6,7</sup>

Several studies have shown that mesenchymal stem cells (MSC) may be involved in tissue regeneration, since they have the ability to modulate the immune responses of pro-inflammatory cells to induce an environment with a more tolerant phenotype to inflammation.<sup>8–11</sup> Furthermore, it is proposed that these cells act in regulating the immune system in inflammatory tissues, putting into action proinflammatory cytokines and the secretion of chemokines.<sup>12</sup> Thus, it can be postulated that MSC could exert an anti-inflammatory action in response to the induction of injury in experimental models *in vivo* and, thus, acting as a potential therapeutic agent in inflammatory diseases such as URC and CD.

In light of this, in this study we intended to verify the effectiveness of transplantation of MSC derived from adipose

tissue (ASC) in rats with intestinal inflammation induced by trinitrobenzenesulfonic acid (TNBS). In addition, with this approach we intend to shed light on pathophysiological aspects of IBD, as well as to suggest and evaluate the effectiveness of new alternative therapies.

## Method

### Animals

In this study, Wistar albino rats (*Rattus norvegicus*), raised in the Central Bioterium, UNESP – campus of Assis, were used under controlled temperature (22 °C) and lighting (12 h of light/12 h of darkness) conditions and fed with a solid diet supplemented with Vitagold® (Tortuga, Sao Paulo, Brazil).

### Experimental groups

The animals were divided into the following experimental groups: blank (healthy animals), control (animals with TNBS-induced bowel inflammation and treated with phosphate–PBS buffer) and treated (animals with TNBS-induced bowel inflammation and treated with mesenchymal stem cells) groups.

### Isolation by mechanical dissociation and culture of adipose tissue-derived stem cells

The adipose tissue extracted from the groin of rats was mechanically dissociated with the help of two L-shaped syringe needles (BD™, New Jersey, USA) in RPMI 1640 medium (Gibco®, New York, USA) supplemented with 2%

antibiotic/antimycotic (Gibco®, New York, USA) for cell/tissue separation. Then, the solution containing dissociated cells was filtered through a 70 µm-filter (Cell Strainer – BD Falcon™, New Jersey, USA) for separating cellular debris. The collected material was centrifuged for 10 min at 900 × g. Then, the cells were seeded in ALPHA-MEM medium (Gibco®, New York, USA) supplemented with 20% Fetal Calf Serum – FCS (Gibco®, New York, USA) and 1% antibiotic/antimycotic to a final concentration of 1 × 10<sup>5</sup> cells/cm<sup>2</sup> and incubated at 37 °C in 5% CO<sub>2</sub>. Cells were maintained in culture and, when a 60–80% confluence in relation to the culture dish area was reached, were dissociated with Tryple™ (Gibco®, New York, USA).

### *In vitro* differentiation of adipose tissue-derived stem cells

In order to induce osteogenic, chondrogenic and adipogenic differentiation, specific kits (StemPro® – Gibco®, New York, USA) were used, according to manufacturer's instructions. The osteogenic differentiation was confirmed by analysis of the material stained with Alizarin Red S (Sigma-Aldrich®, St. Louis, MO, USA), the chondrogenic differentiation with Alcian Blue dye (Sigma-Aldrich®, St. Louis, MO, USA), and the adipogenic differentiation with Oil Red O (Sigma-Aldrich®, St. Louis, MO, USA).

### Experimental model of IBD

The induction of the bowel inflammatory process was performed by the method described by Morris et al.,<sup>13</sup> with minor modifications. 2,4,6-Trinitrobenzenesulfonic acid – TNBS (Sigma-Aldrich®, St. Louis, MO, USA) was first lyophilized and subsequently prepared to obtain a solution of 40 mg/mL in 50% ethanol (v/v). Bowel inflammatory process induction was performed by intracolonic administration of 0.25 mL TNBS solution at a point 8 cm from the rectum. The animals in the blank group underwent the same procedure, but with administration of PBS replacing TNBS. All animals were sacrificed seven days after the induction of IBD.

### Cell transplantation

The cell infusion was performed by intravenous route (tail vein). In the treated group, 1 mL of the cell solution diluted in PBS at a concentration of 1 × 10<sup>7</sup> cells/mL was infused. The control group received a similar treatment; however, only PBS was infused.

### Evaluation of anti-inflammatory bowel activity

The animals were evaluated, considering food consumption, body weight and onset of diarrheal stools. At the end of the experiment, the colons were extracted and analyzed for bowel damage.

### Macroscopic analysis

The weight and length of the colon and presence of adhesions in the bowel and surrounding organs were evaluated. An

analysis of severity and extent of bowel injury, according to a scale previously described by Bell et al.,<sup>14</sup> was also performed.

### Biochemical determinations

The determination of total glutathione (GSH) content was performed according to the method described by Anderson,<sup>15</sup> and the determination of myeloperoxidase (MPO) activity in rat colon fragments was performed by the method of Krawisz et al.<sup>16</sup>

### Histologic analysis

Immediately after the macroscopic evaluation of the colonic inflammatory process, tissue samples (0.5 mm) adjacent to the injured area were collected for histological processing. These samples were placed in histological cassettes, fixed in 4% formalin and stained with hematoxylin–eosin (HE).

### Statistical analysis

Results were expressed as mean ± standard deviation. Differences between means were tested by analysis of variance (ANOVA), followed by tests of significance. Nonparametric data (scores) were expressed as median and analyzed by Kruskal–Wallis test. Discontinuous data were analyzed by chi-squared (X<sup>2</sup>) test. Statistical significance was considered when  $p < 0.05$ .

### Ethical aspects

This study was approved by the Ethics Committee on the Use of Animals (CEUA), Universidade Estadual Paulista – UNESP, campus of Assis (Registration No. 012/2011).

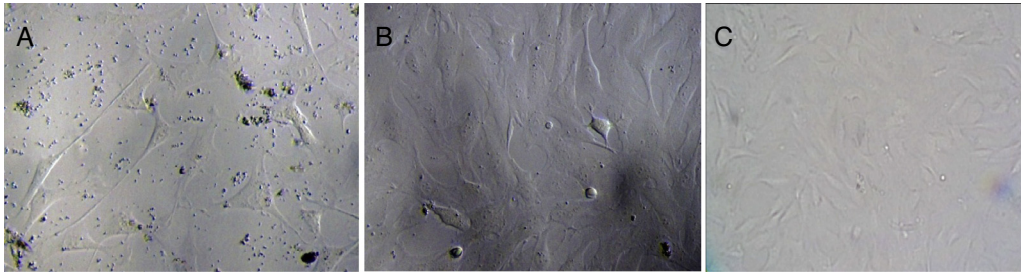
---

## Results

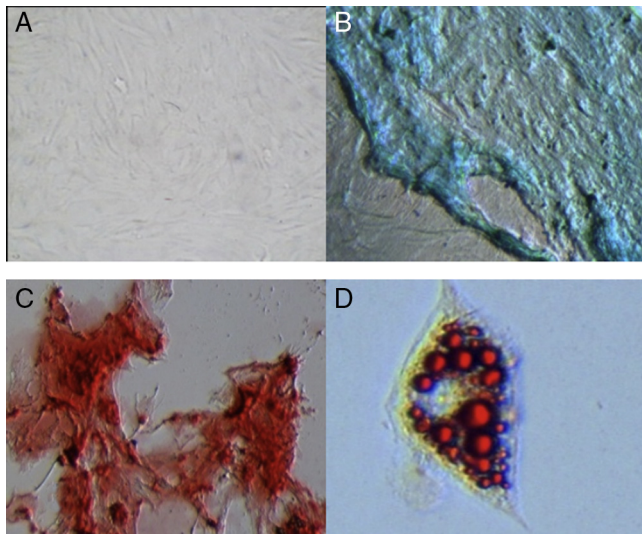
### Culture and characterization of adipose tissue-derived stem cells

As shown in Fig. 1A, on day 7 of culture a significant population of cells with an elongated, fusiform appearance was observed. A 70–80% confluence was achieved around the 11th day of culture (Fig. 1B). After the first dissociation process with Tryple® (Gibco®, New York, USA), the cell growth became faster, because the 70–80% confluence level was reached within 3–4 days. It was also observed that, after the third passage, the culture had assumed the appearance of a uniform monolayer of spindle cells (Fig. 1C), indicating that probably there was no contamination with non-adherent cells, such as mature adipocytes and erythrocytes.

To verify whether the cells isolated from adipose tissue (ASC) met the requirements established by the International Society of Cellular Therapy for validation of MSC,<sup>17</sup> *in vitro* differentiation tests with ASC to obtain chondrocytes, osteocytes and adipocytes were performed. Fig. 2B shows the chondrogenic differentiation. The blue color is indicative of proteoglycan synthesis by chondrocytes. Osteogenesis was confirmed by osteoblasts and osteocytes' bone matrix



**Fig. 1 – Behavior of adipose tissue-derived stem cells at different periods of culture. (A) Primary culture (7 days); (B) after 11 days (70–80% confluence); and (C) homogeneous monolayer of cells with fibroblastoid aspect (third passage).**



**Fig. 2 – Differentiation of ASC into chondrocytes, osteocytes and adipocytes. (A) Culture of ASC in the absence of an induction medium (20×); (B) proteoglycans synthesized by chondrocytes and stained with Alcian Blue (40×); (C) bone matrix stained with Alizarin Red S (40×); and (D) lipid vacuoles stained with Oil Red O (40×).**

staining (Fig. 2C). Finally, the differentiation of ASC into adipocytes was proven. As seen in Fig. 2D, lipid vacuoles are stained in red.

#### Evaluation of bowel anti-inflammatory activity

The food intake showed that the average consumption by healthy animals was higher, when compared with control

group animals. The consumption of blank group animals was statistically different, compared to control and treated groups. However, there was no statistically significant difference between control and treated groups.

The daily body weight evaluation showed that, due to the reduction of food consumption, there was a decrease in body weight of animals subjected to the administration of the alcoholic solution of TNBS. The mean delta body weight of blank group showed statistically significant difference, when compared to control and treated groups. However, there was no statistically significant difference between treated and control groups.

The presence of diarrheal stools was daily monitored in all groups of animals. With respect to control group animals, an incidence of 100% was observed, whereas in treated group animals the incidence was 90%. An analysis of the results showed no statistically significant difference between control and treated groups.

#### Macroscopic evaluation

##### Colon weight/length (W/L)

There is a relationship for colonic injury resulting from inflammation, and this can be quantitatively expressed by an increase in colonic weight/length ratio (W/L in mg/cm). With respect to the results presented in Table 1, we noted that there was no statistically significant difference in relation to colonic W/L between control and treated groups.

##### Adhesions

Presence of adhesions in the intestine and surrounding organs is also considered a characteristic feature of bowel mucosa inflammation. Table 1 shows 83.33% of adhesion in control group animals and 20% in ASC-treated animals. A statistically

**Table 1 – Macroscopic parameters from treatment with adipose tissue-derived stem cells (ASC) in an experimental model of inflammatory bowel disease, by administering an alcoholic solution of TNBS.**

Group	Score (0–10) <sup>a</sup>	Injury extent (cm) <sup>b</sup>	Weight/length ratio (mg/cm) <sup>b</sup>	Adherence (%) <sup>c</sup>
Blank	0 <sup>a</sup>	0 <sup>a</sup>	106.77 ± 3.241 <sup>a</sup>	0 <sup>a</sup>
Control-PBS	7 (5–9) <sup>b</sup>	3.70 ± 0.741 <sup>b</sup>	269.57 ± 43.851 <sup>b</sup>	83.33 <sup>b</sup>
Treated with ASC	6.5 (4–9) <sup>b</sup>	3.51 ± 0.415 <sup>b</sup>	199.36 ± 27.85 <sup>b</sup>	20 <sup>c</sup>

<sup>a</sup> The score values are expressed as median (range).

<sup>b</sup> Injury extent and colonic weight/length ratio are expressed as mean ± SEM (standard error of the mean).

<sup>c</sup> Adherence was analyzed by X<sup>2</sup> test. Values without letters in common show statistically significant difference at  $p < 0.05$ .

significant difference between control and treated groups was found.

#### Severity and extent of bowel injury

The administration of TNBS in control group animals triggered an inflammatory process characterized by lesions along the colon, between 1.20 and 5.50 cm in length and a score between 5 and 9 (Table 1). The results show no statistically significant difference in relation to the lesion length and its score among PBS-control group animals versus ASC-treated animals.

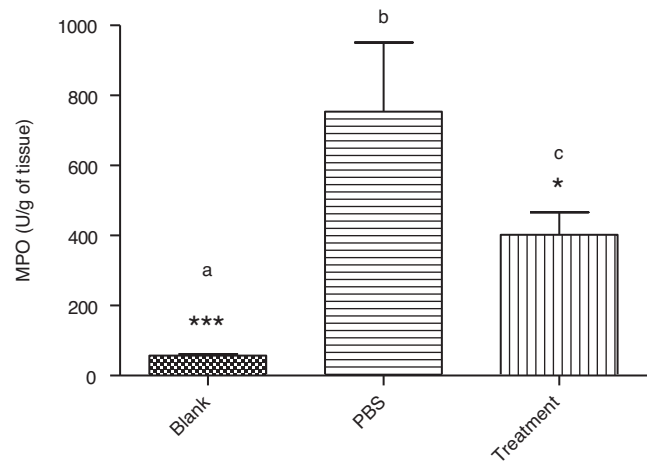
#### Biochemical analysis

The animals treated with the alcoholic solution of TNBS showed a statistically significant difference in regard to a reduction in glutathione levels, when compared to blank group animals. Although GSH levels were higher in treated animals, there was no significant difference when confronting the results among PBS-treated versus ASC-treated animals.

In the case of myeloperoxidase (MPO) activity, it was found that the treatment with adipose tissue-derived stem cells resulted in a statistically significant difference in terms of enzyme activity, when compared to control group, as can be seen in Fig. 3.

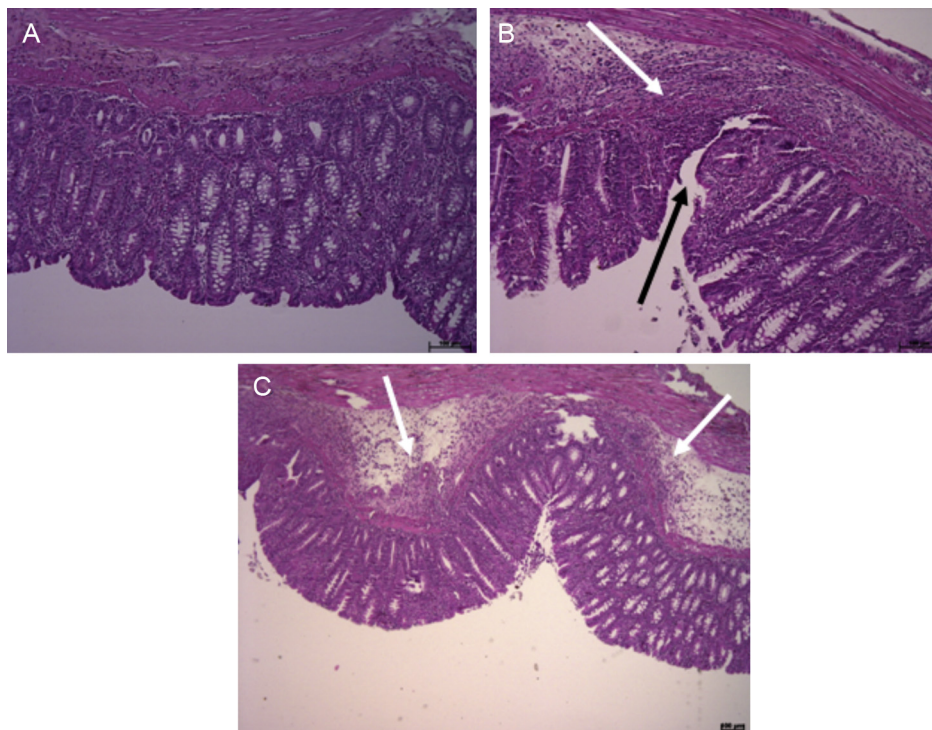
#### Histological analysis

Fig. 4A shows the normal colonic cytoarchitecture of a healthy animal, where the cells are intact, and mucosal, submucosal and muscularis mucosa layers and their dimensions are



**Fig. 3 – Assessment of the activity of myeloperoxidase (MPO) in intestinal mucosa of an inflammatory bowel disease animal model. Data are expressed as mean  $\pm$  SEM. Values without letters in common differ at  $p < 0.05$ .**

clearly identified, without any kind of morphological change. Fig. 4B depicts the colon of an animal with TNBS-induced inflammatory process, characterized by mucosal disruption and the presence of abnormal cells as to form, size and number compared to healthy animals. Additionally, a large submucosal cell infiltrate, typical of neutrophil migration due to colonic inflammation, is perceived. Fig. 4C depicts the colon



**Fig. 4 – Photomicrograph of colonic mucosa of rats after ulcerative colitis induction by administration of an alcoholic solution of TNBS. The sections were stained with hematoxylin-eosin. (A) Non-colitic group (blank): histology of a non-colitic rat colon (10 $\times$ ); (B) control group-PBS: severe ulceration and submucosal infiltration of inflammatory cells (10 $\times$ ); (C) group treated with ASC: submucosal infiltration of inflammatory cells (5 $\times$ ). (B) The black arrow indicates submucosal ulceration and (C) the white arrows indicate an inflammatory cell infiltrate.**

of an animal undergoing treatment with ASC, where a large cellular infiltrate due to TNBS-induced colonic inflammation is noted. However, there is no mucosal disruption – an occurrence clearly seen in PBS-treated animals. The mucosal cells are not significantly altered in shape, and a clear recovery of colonic cytoarchitecture can be perceived.

## Discussion and conclusion

Stem cells derived from adipose tissue (ASC) have been used experimentally as a potentially promising alternative therapy in a number of diseases. The therapeutic effect of stem cells is attributable to a probable immunomodulatory action, with suppression or inhibition of the inflammatory process, as well as by angiogenesis stimulation.<sup>8–12,18</sup> In this context, IBD can be included in the group of diseases that can benefit from cell therapy with stem cells. The ASC used in this study was identified as a population of elongated, fusiform cells, a characteristic feature of MSC and showing plastic surface adherence. Furthermore, ASC presented, when in specific conditions of induction, the functional property of differentiation *in vitro* in chondrogenic, osteogenic and adipogenic lineages, consistent with validation criteria reported by other authors and defined by the International Society for Cellular Therapy.<sup>11,17</sup>

The enzymatic digestion by using collagenase is currently the most widely used procedure for obtaining and isolating ASC.<sup>18,19</sup> In this study, we used an innovative and novel technique of mechanical dissociation for ASC isolation and culture. It should be emphasized that the mechanical dissociation makes unnecessary the use of collagenase, maintaining the efficiency of the process and being cheaper.

It is well established that one of the symptoms of patients suffering IBD is a reduction in body weight, considering that there is a decrease in food intake, besides the occurrence of gastrointestinal disturbances.<sup>20</sup> A reduction in food intake, with consequent weight loss of the animals after the induction of IBD, was seen in colitic groups. However, it was found that food intake and decrease of body weight in ASC-treated animals were similar to those for control group animals. According to Morris et al.,<sup>13</sup> the IBD induction model by TNBS/ethanol produces intestinal wall ulceration and thickening, without affecting significantly the long-term weight increase of animals. Thus, the need for a longer period for restoration of normal food intake and, thus, body weight, is inferred.

Commonly, diarrhea occurs with an inflammation of the colon and small intestine, as a result from the action of inflammatory mediators in bowel epithelium.<sup>21</sup> The occurrence of this observation parameter, a characteristic feature of IBD, was observed in 90% of ASC-treated group animals, showing that, after 7 days of treatment, there is still a large amount of inflammatory mediators in the colon. These data raise the possibility that the period for assessing the effectiveness of cell therapy as an alternative treatment for IBD should be extended beyond the 7-day period adopted in this study.

Other indicators of severity and extent of injury resulting from IBD are: increase in weight and decrease in colonic length in animals with bowel inflammation.<sup>11,13,22</sup> There is a clear

difference in mean W/L ratio, as the [Table 1](#) shows. However, there was no statistically significant difference between animals treated with stem cells versus control animals ([Table 1](#)). This effect is possibly due to the severe injury caused by the administration of the alcoholic solution of TNBS, thereby complicating the regenerating process of the injured mucosa. Ando et al.<sup>11</sup> reported that an injection of ASC directly beneath the colon submucosa significantly decreases the weight of the inflamed colon. This is an indication that the location and route of cell administration can influence the final outcome of a treatment, as previously reported by other authors.<sup>23,24</sup> In this study we adopted an IV infusion route for ASC, so that the divergence among the results of this study and of those reported by Ando et al.<sup>11</sup> could be related to the different infusion route used in the study.

It is also possible to evaluate the intensity of IBD lesion severity by its length and scoring.<sup>25</sup> [Table 1](#) shows that the colonic damage caused by the infusion of alcohol/TNBS was severe and extensive, making the recovery of intestinal mucosa unlikely after 7 days of ASC infusion. In 2009, Wei et al.<sup>26</sup> compared the infusion of hematopoietic stem cells (HSC), bone marrow stem cells (MSC) and a mixture of both cell types in rats with TNBS-induced colitis after 7, 14 and 21 days. The authors found that a decrease in the lesion score occurred only on day 21. Furthermore, this result was only observed in the group treated with a HSC/MSC combination. Thus, we can infer that, due to the intensity and extent of the injury, it would be necessary to increase the time period to evaluate the stem cell performance with respect to the ability to reduce inflammation and promote regeneration of the injured tissue. Another point to be considered refers to the possibility of a HSC/MSC co-infusion, considering that the synergistic effect of these different cell types can act in a beneficial way in the treatment of a number of diseases.<sup>27,28</sup>

The presence of adhesions among the colon and surrounding organs and/or tissues as a result of transmural inflammation is a common feature of IBD, especially in CD.<sup>29</sup> [Table 1](#) shows the occurrence of a significant reduction in the incidence of adhesions in colitic animals and in ASC-treated animals compared with control group animals, suggesting that ASC acted as an agent protecting and/or reducing the inflammatory process.

It can be noted that in experimental models of intestinal inflammation by instillation of TNBS, GSH depletion resulting from colonic inflammation occurred.<sup>22,25,30</sup>

It can be seen that the ASCs used did not present potential to promote increased levels of GSH. It is noteworthy that no study on humans or animal models with intestinal inflammation recording dosages of total glutathione levels after infusion of stem cells has been published.

Among the biochemical analyzes, myeloperoxidase (MPO) is an important tool for identifying the presence of neutrophilic infiltrates and for revealing an inflammatory process as a result of the colonic inflammation. It is known that MPO level reflects the quantity of neutrophils, and a decrease in its activity reflects a decrease in the injured tissue inflammation.<sup>16</sup> In the present study, it was found that ASC-treated animals showed a statistically significant decrease in MPO activity compared to PBS-treated animals ([Fig. 3](#)), showing that ASC can act as an

anti-inflammatory agent, diminishing the damage caused by TNBS administration.<sup>11,30</sup>

The presence of adhesions and the determination of myeloperoxidase activity provide an indication that ASC have the ability to promote and/or accelerate the regeneration process in inflamed intestinal mucosae. However, methodological adjustments should be included in future projects. Among the propositions of readjustment, there should be included an evaluation of the effectiveness of cell therapy for a longer period of time; cell infusion by other routes of administration, in addition to intravenous route; and feasibility of this therapy through co-infusion of ASC in association with hematopoietic stem cells (HSC).

### Conflicts of interest

The authors declare no conflicts of interest.

### Acknowledgments

The authors thank the Mayor of Assis and its City Council (SP – Brazil) and the Consórcio Intermunicipal do Vale do Paranapanema (CIVAP/Health) for financial support. The authors Monica Yonashiro Marcelino and Natalia Langenfeld Fuoco were funded by the Coordenação de Aperfeiçoamento de Pessoal de Nível Superior (CAPES – Brazil).

### REFERENCES

- Almeida-Porada G, Soland M, Boura J, Porada CD. Regenerative medicine: prospects for the treatment of inflammatory bowel disease. *Regen Med.* 2013;8:631-44.
- Lindsay JO, Chipperfield R, Giles A, Wheeler C, Orchard T. A UK retrospective observational study of clinical outcomes and healthcare resource utilisation of infliximab treatment in Crohn's disease. *Aliment Pharmacol Ther.* 2013;38:52-61.
- Baumgart DC, Sandborn WJ. Inflammatory bowel disease: clinical aspects and established and evolving therapies. *Lancet.* 2007;369:1641-57.
- Fite A, Macfarlane S, Furrer E, Bahnami B, Cummings JH, Steinke DT, et al. Longitudinal analyses of gut mucosal microbiotas in ulcerative colitis in relation to patient age and disease severity and duration. *JCM.* 2013;51:849-56.
- Kornbluth A, Sachar DB, MACG. Practice Parameters Committee of the American College of Gastroenterology. Ulcerative colitis practice guidelines in adults: American College of Gastroenterology, Practice Parameters Committee. *Am J Gastroenterol.* 2010;105:501-23.
- Shaffer VO, Wexner SD. Surgical management of Crohn's disease. *Langenbecks Arch Surg.* 2013;398:13-27.
- Orsi PR [dissertação (Mestrado em Ciências Biológicas)] Efeitos sinérgicos da paepalantina, uma isocumarina isolada dos capítulos florais de *Paepalanthus bromelioides*, sobre a atividade da sulfassalazina no modelo de colite ulcerativa induzida por ácido trinitrobenzenosulfônico em ratos. Botucatu: Instituto de Biociências, Universidade Estadual Paulista; 2008.
- Mancheño-Corvo P, Franquesa M, Rosa O, Ramírez C, García-Benzaquén L, Fernández V, et al. Adipose mesenchymal stromal cell function is not affected by Methotrexate and Azathioprine. *Biores Open Access.* 2013;26:431-9.
- Dalal J, Gandy K, Domen J. Role of mesenchymal stem cell therapy in Crohn's disease. *Pediatr Res.* 2012;71:445-51.
- Gonzalez-Rey E, Anderson P, González MA, Rico L, Büscher D, Delgado M. Human adult stem cells derived from adipose tissue protect against experimental colitis and sepsis. *Gut.* 2009;58:1-6.
- Ando Y, Inaba M, Sakaguchi Y, Isuda M, Qaun GK, Omae M, et al. Subcutaneous adipose tissue-derived stem cells facilitate colonic mucosal recovery from 2,4,6-trinitrobenzene sulfonic acid (TNBS)-induced colitis in rats. *Inflamm Bowel Dis.* 2008;14:826-38.
- Tanaka F, Tominaga K, Ochi M, Tanigawa T, Watanabe T, Fujiwara Y, et al. Exogenous administration of mesenchymal stem cells ameliorates dextran sulfate sodium-induced colitis via anti-inflammatory action in damaged tissue in rats. *Life Sci.* 2008;83:771-9.
- Morris GP, Beck PL, Herridge MS, Depew WT, Szewczuk MR, Wallace JL. Hapten-induced model of chronic inflammation and ulceration in the rat colon. *Gastroenterology.* 1989;96:795-803.
- Bell CJ, Gall DG, Wallace JL. Disruption of colonic electrolyte transport in experimental colitis. *Am J Physiol.* 1995;268:G622-30.
- Anderson ME. Determination of glutathione and glutathione disulfide in biological samples. *Method Enzymol.* 1985;113:548-55.
- Krawisz JE, Sharon P, Stenson WF. Quantitative assay for acute intestinal inflammation based on myeloperoxidase activity. Assessment of inflammation in the rat and hamster model. *Gastroenterology.* 1984;87:1344-50.
- Dominici M, Le Blanc K, Mueller I, Slaper-Cortenbach I, Marin F, Krause D, et al. Minimal criteria for defining multipotent mesenchymal stromal cells. The International Society for Cellular Therapy position statement. *Cytotherapy.* 2006;8:315-7.
- Mizuno H. Adipose-derived stem cells for tissue repair and regeneration: ten years of research and a literature review. *J Nippon Med Sch.* 2009;76:56-66.
- Ren Y, Wu H, Zhou X, Wen J, Jin M, Cang M, et al. Isolation, expansion, and differentiation of goat adipose-derived stem cells. *Res Vet Sci.* 2012;93:404-11.
- Strober W, Fuss I, Mannon P. The fundamental basis of inflammatory bowel disease. *J Clin Invest.* 2007;117:514-21.
- Wegmann M, Kämper A, Weber S, Seyberth HW, Köckerling A. Effect of hydroxyeicosatetraenoic acids on furosemide-sensitive chloride secretion in rat distal colon. *J Pharmacol Exp Ther.* 2000;295:133-8.
- Scarmínio V, Fruet AC, Witaicenis A, Rall VLM, Di Stasi LC. Dietary intervention with green dwarf banana flour (*Musa sp* AAA) prevents intestinal inflammation in a trinitrobenzenesulfonic acid model of rat colitis. *Nutr Res.* 2012;32:202-9.
- Castelo-Branco MTL, Soares IDP, Lopes DV, Buongusto F, Martinusso CA, Risario A Jr, et al. Intraperitoneal but not intravenous cryopreserved mesenchymal stromal cells home to the inflamed colon and ameliorate experimental colitis. *PLOS ONE.* 2012;7:e33360.
- Kuo TK, Hung SP, Chuang CH, Chen CT, Shih YR, Fang SC, et al. Stem cell therapy for liver disease: parameters governing the success of using bone marrow mesenchymal stem cells. *Gastroenterology.* 2008;134:2111-21.
- Luchini AC, Oliveira DMC, Pellizzon CH, Di Stasi LC, Gomes JC. Relationship between mast cells and the colitis with relapse induced by trinitrobenzenesulfonic acid in Wistar rats. *Mediat Inflamm.* 2009;1-7.
- Wei Y, Nie Y, Lai J, Wan YY, Li Y. Comparison of the population capacity of hematopoietic and mesenchymal stem cells in experimental colitis rat model. *Transplantation.* 2009;88:42-8.

- 
27. Asari S, Itakura S, Rawson J, Ito T, Todorov I, Nair I, et al. Mesenchymal stem cells facilitate mixed hematopoietic chimerism induction and prevent onset of diabetes in NOD mice. *Pancreas*. 2011;40:846-54.
  28. Liu K, Chen Y, Zeng Y, Xu L, Liu D, Chen H, et al. Coinfusion of mesenchymal stromal cells facilitates platelet recovery without increasing leukemia recurrence in haploidentical hematopoietic stem cell transplantation: A randomized, controlled clinical study. *Stem Cells Dev*. 2011;20:1679-85.
  29. Hoshino A, Kawamura Y, Yasuhara M, Toyama-Sorimachi N, Yamamoto K, Matsukawa A, et al. Inhibition of CCL1-CCR8 interaction prevents aggregation of macrophages and development of peritoneal adhesions. *J Immunol*. 2007;178:5296-304.
  30. Witacenis A, Luchini AC, Hiruma-Lima CA, Felisbino SL, Justulin LA Jr, Garrido-Mesa N, et al. Mechanism and effect of esculetin in an experimental animal model of inflammatory bowel disease. *Eur J Inflamm*. 2013;11:433.