

Management of Complex Fistula-in-ano by Interception of Fistula Track with Application of Ksharasutra (IFTAK): A Novel Technique

Manoranjan Sahu¹  Ashish Sharma¹ 

¹Banaras Hindu University Faculty of Ayurveda, Varanasi, Uttar Pradesh, India

Address for correspondence Manoranjan Sahu, MD (Ay), PhD, Banaras Hindu University Faculty of Ayurveda, Varanasi 221005, Uttar Pradesh, India (e-mail: msahuvns@gmail.com).

J Coloproctol 2022;42(4):279–285.

Abstract

Objective Despite all the technological advances, successful management of complex fistula-in-ano is still a challenge due to recurrence and incontinence. The present study evaluates the outcomes of a novel technique, Interception of Fistula Track with Application of Ksharasutra (IFTAK) in terms of success rate and degree of incontinence.

Methods In the present prospective study, 300 patients with complex fistula-in-ano were treated by the IFTAK technique, whose surgical steps include: incision at the anterior or posterior midline perianal area, identification and interception of the fistulous track at the level of the external sphincter, rerouting the track (and extensions) at the site of interception, and application of a ksharasutra (medicated seton) in the proximal track (from the site of interception to the internal opening) that is laid open gradually, with the resulting wound healing with minimum scarring. The distal track is allowed to heal spontaneously.

Results There were 227 trans-sphincteric and 73 intersphincteric varieties of fistula with supralelevator extension in 23 cases, of which 130 were recurrent fistulas, 29 had horseshoe track, while 25 had blind fistula with no cutaneous opening. The mean duration of the ksharasutra application was 8.11 ± 3.86 weeks with an overall success rate of 93.33% at the 1-year follow-up. A total of 3.67% of the cases reported with a mild impairment of continence on the Wexner incontinence scoring system. Pre- and postoperative anal manometry evaluation showed minimal reduction in median basal and squeeze pressures.

Conclusion The IFTAK technique is a minimally invasive, daycare surgical procedure for the management of complex fistula-in-ano with low recurrence and minimal sphincter damage.

Keywords

- ▶ complex fistula-in-ano
- ▶ ksharasutra
- ▶ IFTAK
- ▶ recurrence
- ▶ incontinence

received
April 18, 2022
accepted after revision
August 1, 2022

DOI <https://doi.org/10.1055/s-0042-1756145>.
ISSN 2237-9363.

© 2022. Sociedade Brasileira de Coloproctologia. All rights reserved.

This is an open access article published by Thieme under the terms of the Creative Commons Attribution-NonDerivative-NonCommercial-License, permitting copying and reproduction so long as the original work is given appropriate credit. Contents may not be used for commercial purposes, or adapted, remixed, transformed or built upon. (<https://creativecommons.org/licenses/by-nc-nd/4.0/>)

Thieme Revinter Publicações Ltda., Rua do Matoso 170, Rio de Janeiro, RJ, CEP 20270-135, Brazil

Introduction

Fistula-in-ano may be defined as an abnormal chronic track lined with granulation tissue that leads from the anorectal lumen (from the internal opening) to the perineum or adjacent structures.¹ Most anal fistulas occur as a sequela of infection of the anal glands, resulting in the formation of an abscess in the intersphincteric plane, from where the sepsis may track in all four directions and may either open at the exterior or extend blindly internally.² The extension of sepsis into deeper or multiple planes and a greater involvement of the sphincter musculature (> 30%) make a fistula complex in nature and pose challenges to treatment.³ The ideal treatment for anal fistula should aim at the eradication of the primary source of infection and promoting healing of the track without jeopardizing continence. Conventional surgical options like fistulotomy and fistulectomy have shown good results for simple, low anal fistulas in terms of success rates and functional outcome. However, in complex cases, a great concern remains about recurrence, greater degree of incontinence, and loss of anatomical integrity which, at times, causes more distress than the disease itself.³⁻⁵ Therefore, various sphincter-sparing procedures like endorectal advancement flaps, fistula plugs, ligation of intersphincteric fistula track (LIFT), and video assisted anal fistula treatment (VAAFT), among others, have been proposed and evaluated over time to time; however, with variable results.⁶⁻⁹

In the traditional Indian Medicine system of Ayurveda, anal fistula is described as *bhagandara*, a surgical disease to be treated either by excision or laying open. Sushruta (500 BC), the ancient Indian surgeon, in addition, prescribed an alternative, safe, and minimally invasive treatment with the use of a medicated seton known as *ksharasutra* (*kshara* - caustic/alkali, *sutra* - thread; in Sanskrit).¹⁰ A *ksharasutra* is prepared by smearing oleoresins of *Commiphora mukul*, powder of *Curcuma longa* and the alkaline ash (*kshara*) obtained from *Achyranthes aspera* on a surgical linen thread no. 20. According to the conventional therapeutic mode, the *ksharasutra* is applied snugly in the fistulous track from one end (opening) to the other using a probe and is changed weekly by the railroad technique. The drugs coated on the thread gradually dissolve and cause lysis of the unhealthy granulation tissue; the whole track is therefore laid open gradually by chemical fistulectomy as well as by mechanical pressure, with an average cutting and healing rate of 1 cm per week.¹¹ Although the success rate of this conventional mode of *ksharasutra* therapy has been reported to be as high as 96.5% with a low incidence of incontinence,¹² the duration of treatment has been long, with patients requiring multiple hospital visits in long fistulas and other complex cases.¹³ To address these difficulties, a novel technique named Interception of Fistula Track with Application of *Ksharasutra* (IFTAK) was devised, in which only a small, proximal part of the fistulous track is laid open and the whole complex fistula is treated in less time with minimal sphincter damage and a good success rate. The present paper describes the technique in detail with its results in a single center, prospective study.

Materials and Methods

After due approval from the ethical committee of the institute, patients with complex fistula-in-ano who attended the Anorectal clinic at Sir Sunder Lal Hospital, Banaras Hindu University, Varanasi, India, were recruited for the study. The study period spanned from August 2011 to July 2018. Fistulas that were anatomically higher (such as high intersphincteric, high trans-sphincteric, or suprasphincteric fistula), which involved significant portions of the sphincter musculature (> 50%), which had multiple tracks and/or distant extensions, as well as high horseshoe and recurrent fistulas were included in the category of complex fistula. Extra sphincteric and noncryptoglandular fistula-in-ano as well as simple fistulas like low intersphincteric and low trans-sphincteric tracks were excluded from the study.

The preoperative assessment of the anatomy of the fistula was performed by clinical examination, three-dimensional (3D)-transrectal ultrasonography (TRUS) (BK medical, transducer type 2052) and MR fistulogram. Assessment of continence status was done by the Jorge and Wexner Scoring system¹⁴ as well as by using 16-channel high resolution water perfusion anal manometry system (The Royal Melbourne Hospital, Victoria, Australia, Model-Kangaroojeff, Software - Trace 1.2V). The procedure was thoroughly explained to all patients and informed consents were obtained. No bowel preparation is needed for this surgical approach and only sodium phosphate enema (100 ml) was given to the patient before the operative procedure. Follow-up was conducted 15 days, 1 month, 3 months, 6 months, and, finally, at 1 year.

Surgical Technique

The extended lithotomy position was adopted for the procedure. Local infiltration anesthesia with an injection of lignocaine 0.5% with adrenaline (1:200,000) was preferred in most cases. Regional or general anesthesia was also used in some cases whenever considered necessary. The internal opening and the course of the fistulous track was assessed by digital rectal examination as well as with the cautious help of a malleable silver probe. If necessary, the internal opening was also visualized by injecting methylene blue or hydrogen peroxide into the fistulous track, which could be seen with the help of an illuminated anal speculum. Invariably, the internal opening was found either in the posterior or in the anterior midline; accordingly, a 1- to 1.5-cm linear vertical incision was made either in the posterior or in the anterior midline ~ 2 cm away from the anal verge (►Fig. 1a). The underlying tissue and muscle fibers were separated by using a pair of mosquito artery forceps at the level of the external sphincter until the fistulous track was identified. Fistulous tracks are usually whitish, shiny, cord-like structures and can be identified after proper dissection near their site of origin or the internal opening. However, at times of difficulties like in cases of blind fistulas or of high trans-sphincteric tracks, digital guidance by the index finger of the opposite hand placed in the anal canal as well as a malleable probe passed

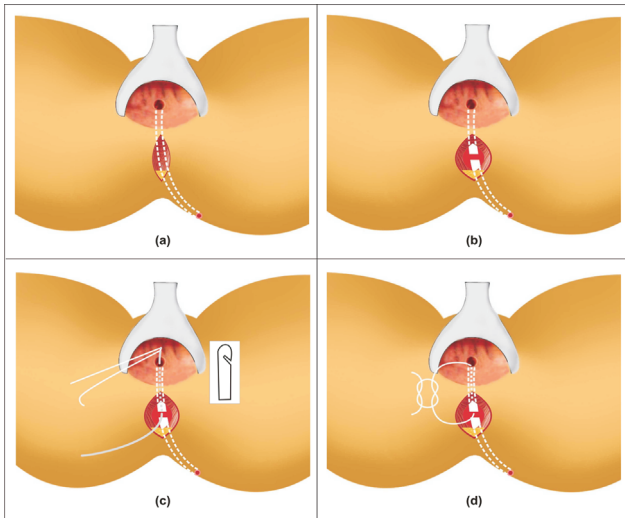


Fig.1 Diagrammatic demonstration of the IFTAK technique in a case of posterior trans-sphincteric fistula (track shown by white dotted lines) extending from the left perianal region to the posterior midline with internal opening at the 6 o'clock position; (a) A linear vertical incision made in the posterior midline ~2cm away from the anal verge to explore the fistulous track; (b) Tissue over the fistulous track carefully separated to reach up to the track that is identified as a white cord-like structure and is intercepted at the level of the external sphincter; (c) Probe passed in the proximal track through the site of interception (window) and the *ksharasutra* is mounted at the tip of the probe. (Inset shows the tip of the probe with a notch like a cobbler's needle); and (d) *Ksharasutra* applied in the proximal track.

into the fistulous track can help in better identifying and intercepting the track.

Once the track was identified, it was intercepted by a pair of fine scissors (►Fig. 1b and ►Fig. 2c). Thus, the fistulous track was divided into a proximal and a distal part with a gap (window) in between, which was widened by using a pair of artery forceps to provide adequate drainage to the primary track as well as to the secondary extensions or abscesses located in adjacent anatomical spaces. A soft, malleable, blunt tip silver probe with a notch at the tip (like a cobbler's needle) was then passed through the window up to the internal opening at the pectinate line (►Fig. 1c and ►Fig. 2e) and *ksharasutra* was applied in the proximal track (►Fig. 1d and ►Fig. 2f). The distal part of the fistulous track was left as such for healing. The wound was dressed with a sterile pad.

Postoperative pain could be managed effectively by oral nonsteroid anti-inflammatory drugs (NSAIDs). After 2 hours of observation for immediate postoperative complications like bleeding etc., the patients were sent home with an advice to take sitz bath with lukewarm water (40 to 45°C) twice daily to keep the wound clean and to continue their daily routine as usual. A bowel softener like psyllium husk was prescribed for smooth bowel movements.

The patients were advised to visit the outdoor clinic at 7- to 10-day intervals for change of *ksharasutra* as well as to assess the patency of the window (site of interception) and the condition of the external opening for any discharge or

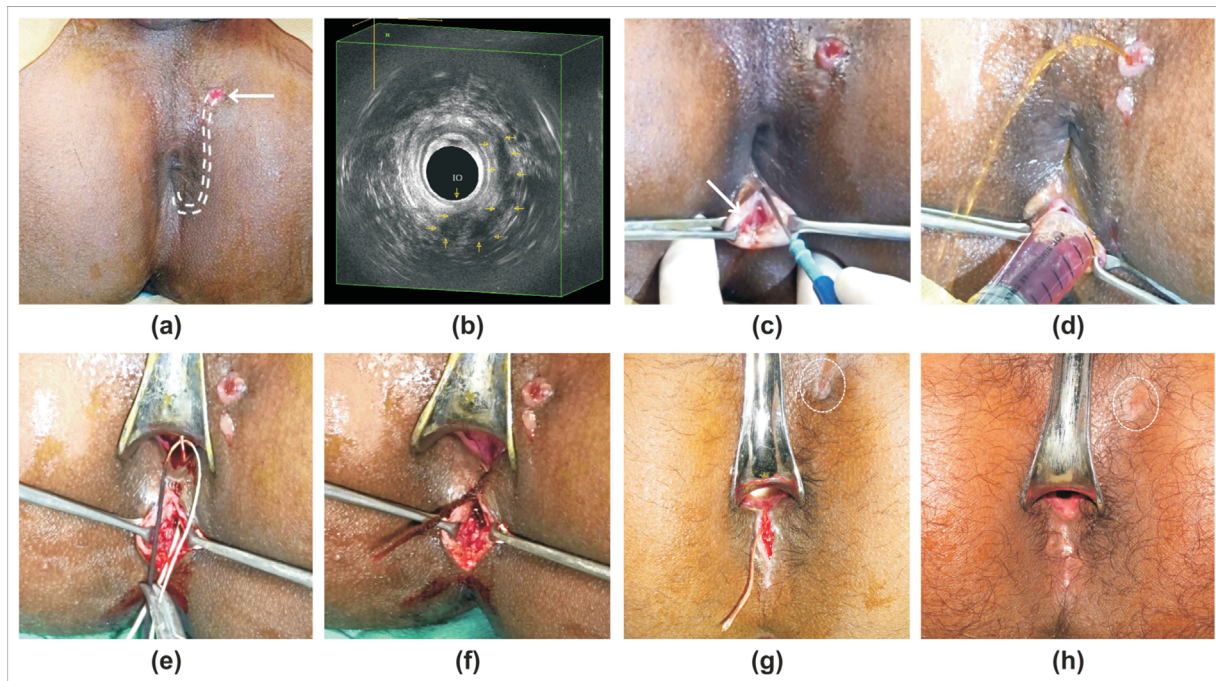


Fig.2 Demonstrating the IFTAK technique and its outcome; (a) Left trans-sphincteric fistula (curved track shown by white dotted lines) extending from the 1 o'clock position of the external opening (white arrow) to the posterior midline at the 6 o'clock position of the internal opening; (b) 3D-TRUS image showing the course of the track (yellow arrows) from the 1 o'clock position, traversing along the external sphincter on the left lateral side and piercing through the sphincters at the posterior midline to open into the anal canal at the 6 o'clock position; (c) Linear vertical incision taken in the posterior midline with interception of fistulous track (white arrow); (d) Jet of fluid coming out from the external opening on injecting the fluid through the site of interception (window) showing the free communication of the track with the window; (e) Probe passed in the proximal track through the site of interception (window) with *ksharasutra* mounted at the tip of the probe; (f) *Ksharasutra* applied in the proximal track; (g) Healed external opening (yellow dotted circle) with healthy granulating wound after 1 week with *ksharasutra* in situ; and (h) Completely healed fistula (yellow dotted circle) after 3 weeks of IFTAK treatment with minimal scarring in the posterior midline.

Table 1 Success rate after the interception of fistula track with application of *ksharasutra* technique and mean duration of therapy (*ksharasutra* application) with reference to the type of fistula

Type of fistula		No. of cases			Duration of therapy (weeks) (mean \pm SD)
		Total	Cured	Failed to heal	
Intersphincteric	With unilateral high blind track	63	61	2	6.63 \pm 3.48
	With contralateral intersphincteric extension	10	10	0	9.3 \pm 3.06
Trans-sphincteric	High trans-sphincteric with no secondary extension	92	90	2	7.55 \pm 3.88
	With unilateral intersphincteric extension	60	54	6	8.77 \pm 3.51
	With bilateral intersphincteric extension	24	19	5	9.87 \pm 5.16
	With unilateral ischiorectal extension	32	30	2	8.78 \pm 3.26
	With bilateral ischiorectal extension	19	16	3	9.63 \pm 3.74
Total		300	280	20	8.11 \pm 3.86
p-value		<0.05*			<0.001 [#]

Abbreviation: SD, standard deviation.

*Pearson chi-squared test.

[#]Kruskal-Wallis Ttest.

state of healing. During each visit, the *ksharasutra* in the proximal track was replaced by a new one by the railroad technique and the window was kept wide open to ensure adequate drainage. Once the external opening(s) ceased to discharge and showed signs of healing, which invariably occurs within 1 to 2 weeks (**Fig. 2g**), the *ksharasutra* was tied snugly so that it resulted into progressive laying open and healing of the proximal fistulous track with minimum scarring (**Fig. 2h**).

Results

Our series consisted of 300 cases, 294 (98%) males and 6 (2%) females; with a mean age of 39.27 years old (range: 15 to 72 years old). There were 227 (75.67%) trans-sphincteric and 73 (24.33%) intersphincteric types of complex fistula-in-ano. Of the trans-sphincteric cases, 135 had extensions into the intersphincteric or ischiorectal spaces either on one or both sides, while 18 of them were also associated with a supralevator extension. Among the intersphincteric fistulae, 10 patients had a contralateral intersphincteric extension, while in 5 cases the sepsis also extended into the supralevator space. In most (88%) fistulas, the internal opening was present in the posterior midline with 130 (43.33%) of the total 300 cases being recurrent fistulas; 29 (9.67%) cases presented with a horseshoe nature of the track with ≥ 2 external openings on either side of the anal canal; 25 (8.33%) cases were blind in nature, with no cutaneous opening around the anal orifice.

Four patients each were operated under regional and general anesthesia while the rest was operated under local anesthesia. The operative time varied between 10 and 20 minutes depending on the nature of the track and on

the extension to the deeper structures. No intraoperative or immediate postoperative complication was observed in any patient. The patients operated under local anesthesia were discharged on the same day after 2 hours of observation while the patients operated under regional or general anesthesia were discharged on the next morning. All patients resumed their daily routine after discharge. Use of oral NSAIDs for the management of postoperative pain was limited only to 1 or 2 days after the procedure.

Successful healing was achieved in 280 (93.33%) cases. The overall mean duration of *ksharasutra* application (from the day of the operation until the laying open of proximal track) was 8.11 \pm 3.86 weeks (95% confidence interval [CI]: 7.67–8.55 weeks), ranging a mean of 6.63 to 9.3 weeks for intersphincteric fistulas and of 7.55 to 9.87 weeks for trans-sphincteric fistulas (**Table 1**). The duration of therapy showed a statistically significant relationship with types of fistula ($p < 0.001$; Kruskal-Wallis test) as well as with the presence of supralevator extension ($p < 0.01$; Pearson chi-squared test). After complete laying open of the proximal track by *ksharasutra* application, the resulting wound healed completely within 6 to 8 weeks.

All patients were followed-up for 1 year after healing of the wound, 79 of which underwent post-therapy anal manometry, and the results showed a reduction of 11.81 mmHg in median resting pressure (pretherapy: 79.35 \pm 15.97; post-therapy: 67.54 \pm 14.50) and 23.54 mmHg in squeeze pressure (pretherapy: 158.42 \pm 36.83; post-therapy: 134.87 \pm 37.28). Although the difference was statistically significant ($p < 0.001$), the subjective assessment done with the Wexner Incontinence Scoring system¹⁴ showed only a mild impairment of flatus continence in 11 (3.67%) cases, with a score increment from 0 to 1 in 7 of the primary

fistula cases and of 1 to 2 in 4 of the recurrent fistula cases. Two of these recurrent cases also developed rare incontinence to liquid stool (score 1) after IFTAK therapy.

The remaining 20 cases did not respond to this method of treatment and continued to discharge pus through the external opening. They were subsequently treated by conventional *ksharasutra* therapy. Two of these were intersphincteric fistulas with high blind track reaching up to the supralelevator area. The rest consisted of trans-sphincteric cases, of which 2 were high trans-sphincteric cases with no secondary extension, 11 had intersphincteric extensions (6 unilateral and 5 bilateral), while 5 had ischiorectal extensions (2 unilateral and 3 bilateral) (►Table 1). Two of the trans-sphincteric fistulas with bilateral intersphincteric extensions also had supralelevator involvement. The chi-squared analysis revealed that treatment failure was independent of factors such as gender of the patient ($p = 0.5$), history of previous surgery ($p = 0.12$), and blind ($p = 0.16$) or horseshoe nature of the track ($p = 0.4$), but showed statistically significant relationships with the age of the patient ($p < 0.05$), the type of fistula ($p < 0.05$), and the presence of supralelevator extension ($p < 0.05$).

Discussion

Fistula-in-ano is considered a troublesome and difficult-to-treat disease since ancient times.¹⁵ Recurrence and incontinence have been a common phenomenon associated specially with complex fistulas since the cure and the continence come at the cost of each other, similar to what happens with fistulotomy; although the recurrence rate has been reported as being low (4 to 7%) in some studies, high rates of postoperative incontinence (27 to 82%) suggest its limitation in complex cases.^{16–18} Outcomes of fistulectomy and even of cutting seton have also not been satisfactory in terms of incontinence rates, reaching up to 25% for the former¹⁹ and 67% for the latter.²⁰ Therefore, the sphincter-sparing techniques emerged but had one or more significant limitations. For example, the advancement flap repair of fistulas has an average success rate of 80.8%, with a 13.3% incontinence rate, but graft failure, wound dehiscence, ectropion etc. are some of the important complications associated with this technique in addition to the high technical expertise it demands.⁶ On the other hand, use of fibrin sealants or fistula plugs are simple and easy to perform options but reports of very low success rates (9 and 14% for fibrin glue,^{21,22} and 13.9 and 24% for fistula plugs)^{23,24} make these an ineffective choice, only to be recommended for cases in which other options are not feasible.⁴ High extrusion rates and cost have been additional issues related with the use of fistula plugs.²⁵ The LIFT technique is another popular example in this list that has shown a quite good success rate (between 94.1 and 94.4%) in some studies^{26,27} but has been deemed successful mostly in uncomplicated intersphincteric and trans-sphincteric cases as the chances of failure increase in the presence of associated abscesses or multiple tracks.⁴ In case of VAAFT and laser closure of fistulas, the overall estimated success rates have been moderate so far (76.0 and 67.3%, respectively) and their efficacy in cases of complex fistula-in-ano is yet to be established.^{9,28}

Conventional *ksharasutra* therapy has shown high success rates ranging from 94.1 to 100% in single-center prospective studies to 96% in multicenter randomized controlled trials involving both low and high types of fistulas with no or minor incontinence.^{29–31} The therapy is a daycare procedure and the patients remain ambulatory during treatment.^{12,30} Dutta et al. found *ksharasutra* therapy to be more cost-effective than fistulotomy as the hospital stay was shorter in the *ksharasutra* group and around three-fourths of the subjects remained ambulatory and resumed their work the day after the procedure.³² However, the conventional method has some disadvantages in complex cases, like big scars, as it involves laying open the whole track,¹³ prolonged treatment duration,^{13,29} and multiple hospital visits for change of *ksharasutra*, which may be painful at times.^{30,33} The long duration of the treatment and multiple visits also increase the overall financial burden on the patient.

Interception of fistula track with application of *ksharasutra* is a minimally-invasive technique, the rationale of which is based on the concept of eradicating the primary source of cryptoglandular infection (the infected anal crypt) by the application of *ksharasutra* and rerouting the fistula track and its extensions at the site of interception. A persistent drainage of the extensions or cavities located in various anatomical spaces such as intersphincteric, ischiorectal, or supralelevator is provided through the newly-created window, which is further facilitated by the application of *ksharasutra*. *Ksharasutra*, in addition to eradicating the infected crypt and facilitating drainage, gradually lays open the proximal track while the distal track heals spontaneously, being cut off from the primary source of infection, which may be demonstrated by transrectal ultrasonography (►Fig. 3) as well as by histopathological examination (►Fig. 4). In a study comparing LIFT with LIFT plus partial coring-out fistulectomy of the distal track, the authors found no significant difference between healing rates in both groups and, therefore, concluded that the excision of the distal fistulous track provided no additional increase in the success rate.³⁴

Ksharasutra applied in the proximal track also has other merits. In an earlier study, Srivastava et al. showed that drugs coated with *ksharasutra* help healing the fistulous track by debriding the unhealthy granulation tissue, and reducing the inflammatory components, early fibroblastic proliferation, proper collagen laying, and vascular proliferation in the wound.¹¹ Moreover, the alkaline nature of the drugs coated with *ksharasutra* that are released in the fistulous track change the local environment toward alkaline and render it unfavorable to microbial growth. Thus, in addition to gradual cutting of the track, a simultaneous healing of the wound also takes place. Therefore, the damage to the sphincter is minimal and the chances of incontinence become practically lower.

The technique is also equally effective in cases of recurrent fistula-in-ano that, otherwise, pose a problem while being treated with other techniques due to more fibrosis and difficulty in the identification of the track.³⁵ It is an ambulatory daycare procedure unlike operative techniques such as endorectal flaps, core out fistulectomy etc., which may require hospital stay extending up to a week or more.^{36,37}

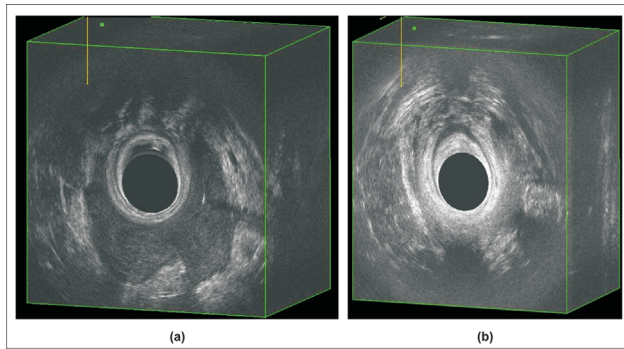


Fig.3 Changes in the fistulous track after IFTAK therapy by 3D-TRUS; (a) Preoperative image showing a hypoechoic area around the posterior 2/3rd of the anal canal suggestive of a horseshoe-type trans-sphincteric fistula with bilateral intersphincteric involvement, postanal, and the left ischioanal spaces; and (b) Postoperative image of the same patient 7 months after the completion of IFTAK therapy showing the mixed echogenicity suggestive of healed fistulous track with obliteration of the cavities.

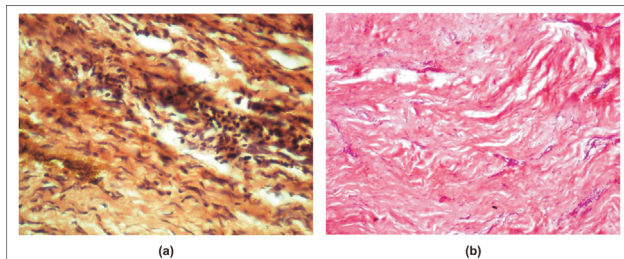


Fig.4 Changes in the fistulous track after IFTAK therapy by histopathological examination; (a) Intraoperative biopsy of the fistulous track showing the diffuse infiltration of chronic inflammatory cells with fibroblastic proliferation suggestive of active fistulous track; (b) Subsequent biopsy of the remaining (distal) track taken after 3 weeks showing the hyalinized scar tissue suggestive of healing of fistulous track (Hematoxylin and Eosin staining; magnification: 40x).

The patients can continue their daily routine during the treatment period. Due to minimal intervention, there is less postoperative pain, which is manageable with NSAIDs only. The requirement of postoperative antibiotics is limited only in few cases to manage secondary infection. Being a daycare procedure performed under local anesthesia, the cost of treatment is also lower.

A total of 6.67% of the cases in our study did not respond to the treatment; the possible cause for this was observed to be inadequate drainage of the blind pockets or ramifications of the track in higher or deeper planes. This inadequate drainage may occur due to the inverted bottleneck phenomenon that is further augmented by the muscle tone of the sphincter, which tend to narrow the site of interception. The other possible reason was inaccurate identification of the involved infected crypt or inappropriate interception of the track.

Conclusion

The primary cause of fistula-in-ano is the infection of anal glands or crypts from where the sepsis extends around the anal canal into the perianal area that, at times, may extend

into the deeper planes and distant regions (scrotal, gluteal, thigh etc.) by traversing through the previously healthy structures and making the disease complex. The aim of fistula treatment should primarily focus on the eradication of this root-cause, that is, the cryptoglandular infection rather than laying open or excising the entire fistulous track. The IFTAK technique addresses this issue by eradicating the cryptoglandular infection with the application of *ksharasutra* while the distal part of the fistulous track is left to heal as such without cutting or laying open the innocent tissues through which it travels. Even multiple tracks or branches of a fistula can be dealt effectively through a single, small incision. Hence, there is a need to reconsider the laying open or coring out of the entire fistulous track in the management of fistula-in-ano, which seems to be unnecessary.

Conflict of Interests

The authors have no conflict of interests to declare.

Acknowledgments

The authors would like to thank Prof. Mohan Kumar, Former Head, Department of Pathology, Institute of Medical Sciences, Banaras Hindu University, Varanasi -221005 (U.P.), India, for his help in the histopathological examination of the biopsy tissue from fistulous tracks and Dr. KKVS Peshala, Research Scholar, Department of Shalya Tantra, Faculty of Ayurveda, IMS, BHU, Varanasi, India, for the help in Anal Manometry analysis.

References

- Williams NS, O'Connell PR, McCaskie AW, , Eds. Bailey & Love's short practice of surgery. 27th ed. Florida: CRC Press, Taylor and Francis Group; 2018:1363-7
- Abcarian H. Relationship of abscess to fistula. In: Abcarian H, editor. Anal fistula: principles and management. New York: Springer Science & Business Media; 2014:13-4
- Vogel JD, Jhonson EK, Morris AM, et al. Clinical Practice Guideline for the Management of Anorectal Abscess, Fistula-in-Ano, and Rectovaginal Fistula. *Dis Colon Rectum* 2016;59(12):1117-1133
- Williams G, Williams A, Tozer P, et al. The treatment of anal fistula: second ACPGIB Position Statement - 2018. *Colorectal Dis* 2018;20(Suppl 3):5-31
- Sheikh P, Baakza A. Management of fistula-in-ano – the current evidence. *Indian J Surg* 2014;76(06):482-486
- Soltani A, Kaiser AM. Endorectal advancement flap for cryptoglandular or Crohn's fistula-in-ano. *Dis Colon Rectum* 2010;53(04):486-495
- O'Riordan JM, Datta I, Johnston C, Baxter NN. A systematic review of the anal fistula plug for patients with Crohn's and non-Crohn's related fistula-in-ano. *Dis Colon Rectum* 2012;55(03):351-358
- Zirak-Schmidt S, Perdawood SK. Management of anal fistula by ligation of the intersphincteric fistula tract - a systematic review. *Dan Med J* 2014;61(12):A4977
- Garg P, Singh P. Video-Assisted Anal Fistula Treatment (VAAFT) in Cryptoglandular fistula-in-ano: A systematic review and proportional meta-analysis. *Int J Surg* 2017;46:85-91
- Shastri AD, Ed. Ayurveda Tattwa Sandeepika Hindi Commentary on Sushruta Samhita, Chikitsa Sthana, Chapter 17, Verse 29-32. Reprint ed. Varanasi: Chaukhambha Sanskrit Sansthan; 2009:101

- 11 Srivastava P, Sahu M. Efficacy of ksharasutra therapy in the management of fistula-in-ano. *World J Colorectal Surg* 2010;2(01):6
- 12 Deshpande PJ, Sharma KR. Treatment of fistula-in-ano by a new technique. Review and follow-up of 200 cases. *Am J Proctol* 1973; 24(01):49-60
- 13 Ramesh PB. Anal fistula with foot extension-Treated by kshara sutra (medicated seton) therapy: A rare case report. *Int J Surg Case Rep* 2013;4(07):573-576
- 14 Jorge JMN, Wexner SD. Etiology and management of fecal incontinence. *Dis Colon Rectum* 1993;36(01):77-97
- 15 Shastri AD, . Ed. *Ayurveda Tattva Sandeepika Hindi commentary on Sushruta Samhita, Sootra Sthana, Chapter 33, Verse 4-5*. Reprint ed. Varanasi: Chaukhamba Sanskrit Sansthan; 2009:163
- 16 Atkin GK, Martins J, Tozer P, Ranchod P, Phillips RKS. For many high anal fistulas, lay open is still a good option. *Tech Coloproctol* 2011;15(02):143-150
- 17 Tozer P, Sala S, Cianci V, et al. Fistulotomy in the tertiary setting can achieve high rates of fistula cure with an acceptable risk of deterioration in continence. *J Gastrointest Surg* 2013;17(11):1960-1965
- 18 Tozer P, Phillips RKS. Fistulotomy and lay open technique. In: Abcarian H, editor. *Anal fistula: principles and management*. New York: Springer Science & Business Media; 2014:53-64
- 19 Herold A. Fistulectomy with primary sphincter reconstruction. In: Abcarian H, editor. *Anal fistula: principles and management*. New York: Springer Science & Business Media; 2014:65-8
- 20 Ritchie RD, Sackier JM, Hodde JP. Incontinence rates after cutting seton treatment for anal fistula. *Colorectal Dis* 2009;11(06):564-571
- 21 Damin DC, Rosito MA, Contu PC, Tarta C. Fibrin glue in the management of complex anal fistula. *Arq Gastroenterol* 2009; 46(04):300-303
- 22 Buchanan GN, Bartram CI, Phillips RKS, et al. Efficacy of fibrin sealant in the management of complex anal fistula: a prospective trial. *Dis Colon Rectum* 2003;46(09):1167-1174
- 23 Safar B, Jobanputra S, Sands D, Weiss EG, Noguera JJ, Wexner SD. Anal fistula plug: initial experience and outcomes. *Dis Colon Rectum* 2009;52(02):248-252
- 24 Lawes DA, Efron JE, Abbas M, Heppell J, Young-Fadok TM. Early experience with the bioabsorbable anal fistula plug. *World J Surg* 2008;32(06):1157-1159
- 25 Eisenstein S, Ky AJ. Biological fistula plugs. In: Abcarian H, editor. *Anal fistula: principles and management*. New York: Springer Science & Business Media; 2014:83-8
- 26 Rojanasakul A, Pattanaarun J, Sahakitrungruang C, Tantiphlachiva K. Total anal sphincter saving technique for fistula-in-ano; the ligation of intersphincteric fistula tract. *J Med Assoc Thai* 2007;90 (03):581-586
- 27 Parthasarathi R, Gomes RM, Rajapandian S, et al. Ligation of the intersphincteric fistula tract for the treatment of fistula-in-ano: experience of a tertiary care centre in South India. *Colorectal Dis* 2016;18(05):496-502
- 28 Elfeki H, Shalaby M, Emile SH, Sakr A, Mikael M, Lundby L. A systematic review and meta-analysis of the safety and efficacy of fistula laser closure. *Tech Coloproctol* 2020;24(04): 265-274
- 29 Panigrahi HK, Rani R, Padhi MM, Lavekar GS. Clinical Evaluation of Kshara sutra Therapy in the management of Bhagandara (Fistula-in-Ano)- A prospective study. *Anc Sci Life* 2009;28(03):29-35
- 30 Mohite JD, Gawai RS, Rohondia OS, Bapat RD. Ksharsootra (medicated seton) treatment for fistula-in-ano. *Indian J Gastroenterol* 1997;16(03):96-97
- 31 Shukla NK, Narang R, Nair NGK. Indian Council of Medical Research. Multicentric randomized controlled clinical trial of Ksharasootra (Ayurvedic medicated thread) in the management of fistula-in-ano. *Indian J Med Res* 1991;94:177-185
- 32 Dutta G, Bain J, Ray AK, Dey S, Das N, Das B. Comparing Ksharasutra (Ayurvedic Seton) and open fistulotomy in the management of fistula-in-ano. *J Nat Sci Biol Med* 2015;6(02): 406-410
- 33 Ho KS, Tsang C, Seow-Choen F, et al. Prospective randomised trial comparing ayurvedic cutting seton and fistulotomy for low fistula-in-ano. *Tech Coloproctol* 2001;5(03):137-141
- 34 Sirikurnpiboon S, Awapittaya B, Jivapaisarnpong P. Ligation of intersphincteric fistula tract and its modification: Results from treatment of complex fistula. *World J Gastrointest Surg* 2013;5 (04):123-128
- 35 Limura E, Giordano P. Modern management of anal fistula. *World J Gastroenterol* 2015;21(01):12-20
- 36 Jarrar A, Church J. Advancement flap repair: a good option for complex anorectal fistulas. *Dis Colon Rectum* 2011;54(12): 1537-1541
- 37 Roig JV, Garcia-Armengol J, Jordán J, Alos R, Solana A. Immediate reconstruction of the anal sphincter after fistulectomy in the management of complex anal fistulas. *Colorectal Dis* 1999;1(03): 137-140