




## Case Report

# Management of rectal prolapse (Guda Bhramsa) through Kshara Karma (chemical cauterisation) – a case study



Madan Bhandari \*, Basavaraj Chanda, Prasanna N. Rao, Gopikrishna B.J, Sahanasheela K.R

Sri Dharmasthala Manjunatheshwara College of Ayurveda & Hospital, Department of Shalya Tantra, Hassan, Karnataka, India

### ARTICLE INFO

#### Article history:

Received 19 March 2019

Accepted 22 May 2019

Available online 17 June 2019

#### Keywords:

Rectal prolapse

Ayurveda

Kshara Karma

Susruta

### ABSTRACT

Rectal Prolapse is a condition where the rectum protrudes beyond the anus. The explanation of this condition can be traced back to ancient Ayurveda text like Susruta Samhita, Ebers Papyrus of 1500 B.C., etc. The exact cause of rectal prolapse is unclear but it is predominant on female gender and on people having constipation, previous anorectal surgeries etc. Both partial and complete varieties of rectal prolapse are extremely debilitating because of the discomfort of the prolapsing mass and variety of symptoms like rectal bleed, intermittent constipation or fecal incontinence. Although, diverse modalities of surgical management of rectal prolapse are present, no single optimal procedure is proved and the choice of operation is determined by the patient's age, sex, degree of incontinence, operative risk, as well as by the surgeon's experience. In Ayurveda, Guda Bhramsa (Rectal prolapse) is explained by Acharya Susruta under Kshudra Rogas (chapter of minor diseases) and has elaborated its conservative management very beautifully. In this case, a female with partial rectal prolapse was treated with Kshara application and managed without complications. So, Kshara application can be a safe and effective alternative for the management of rectal prolapse.

© 2019 Sociedade Brasileira de Coloproctologia. Published by Elsevier Editora Ltda. This is an open access article under the CC BY-NC-ND license (<http://creativecommons.org/licenses/by-nc-nd/4.0/>).

### Manejo do prolapso retal (Guda Bhramsa) usando Kshara Karma (cauterização química) – um estudo de caso

#### RESUMO

O prolapso retal é uma condição em que o reto se projeta para além do ânus. A explicação desta condição foi relatada em antigos textos Ayurveda como Susruta Samhita e Ebers Papyrus, datados de 1500 aC. A causa exata do prolapso retal não é clara, mas essa condição é predominante no sexo feminino e nas pessoas com constipação e histórico de cirurgias anorretais anteriores. Tanto o prolapso retal parcial quanto total são extremamente debilitantes

#### Palavras-chave:

Prolapso retal

Ayurveda

Kshara Karma

Susruta

\* Corresponding author.

E-mail: [madanbhandari750@gmail.com](mailto:madanbhandari750@gmail.com) (M. Bhandari).

<https://doi.org/10.1016/j.jcol.2019.05.008>

2237-9363/© 2019 Sociedade Brasileira de Coloproctologia. Published by Elsevier Editora Ltda. This is an open access article under the CC BY-NC-ND license (<http://creativecommons.org/licenses/by-nc-nd/4.0/>).

devido ao desconforto da massa prolapsante e da variedade de sintomas como sangramento retal, constipação intermitente ou incontinência fecal. Embora diversas modalidades de tratamento cirúrgico para corrigir o prolapso retal tenham sido relatadas na literatura, nenhum procedimento é consensual; a escolha da operação é determinada pela idade, sexo, grau de incontinência, risco operatório e experiência do cirurgião. Na Ayurveda, Guda Bhramsa (prolapso retal) é explicado por Acharya Susruta no Kshudra Rogas (capítulo de doenças menores) e seu manejo conservador é descrito de forma bastante completa. No presente caso, uma paciente do sexo feminino com prolapso retal parcial foi tratada com aplicação de Kshara e administrada sem complicações. Assim, a aplicação de Kshara pode ser uma alternativa segura e eficaz para o manejo do prolapso retal.

© 2019 Sociedade Brasileira de Coloproctologia. Publicado por Elsevier Editora Ltda. Este é um artigo Open Access sob uma licença CC BY-NC-ND (<http://creativecommons.org/licenses/by-nc-nd/4.0/>).

## Introduction

Rectal Prolapse or procidentia is a condition where the rectum protrudes beyond the anus. The explanation of this condition can be seen on ancient Ayurveda text like Susruta Samhita<sup>1</sup> and also on Ebers Papyrus of 1500 B.C.<sup>2</sup> The prevalence of the rectal prolapse is estimated to occur in less than 0.5% of general population and more frequently on elderly population and in females.<sup>3</sup> The exact cause of rectal prolapse is unclear but it is predominant on female gender<sup>4</sup> and on people having constipation, previous anorectal surgeries,<sup>5</sup> etc. There are 2 clinical varieties of rectal prolapse i.e. complete or full thickness and partial or mucosa only prolapse Both of these variety are extremely debilitating because of the discomfort of the prolapsing mass and variety of symptoms like rectal bleed, intermittent constipation or fecal incontinence.<sup>6</sup> This clinical entity can be diagnosed on thorough history taking and physical examination whereas additional test like colonoscopy, defecography, barium enema etc. can be done to define the diagnosis and to know other important pathology.<sup>7</sup> Although, diverse modalities of surgical management of rectal prolapse are present no single optimal procedure is proved and the choice of operation is determined by the patient's age, sex, degree of incontinence, operative risk, as well as by the surgeon's experience. In Ayurveda, Guda Bhramsa (Rectal prolapse) is explained by Acharya Susruta under Kshudra Rogas (chapter of minor diseases)<sup>1</sup> and has elaborated it's conservative management very beautifully.<sup>8</sup> Acharya Vagbhata has described it as a complication of Atisaara (diarrhea).<sup>9</sup>

## Case study

### Chief complaints

A female patient of 40 years old, housewife from Hassan, Karnataka came to SDM College of Ayurveda & Hospital with the complaint of mass per rectum from 1 year.

### History of present illness

According to the patient she was apparently healthy 1 year back, and then she felt something protruding out from rectum

while straining during defecation. It was painless but was occasionally associated with streaks of blood. The mass of rectum was very often self reducing in nature, requiring manual reduction rarely. She was also suffering from intermittent constipation and tenesmus.

### History of past illness

No any relevant past history of illness.

### Treatment history

She consulted some nearby house doctors for the same complaint and was under over the counter herbal laxative. It reduced the complaints of intermittent constipation but the protrusion of mass was the same or even increasing (according to the patient).

### Personal history

The appetite of patient was good. The bowel was constipated intermittently and bladder habit was regular. The patient used to have sound sleep. The patient didn't have any habit of alcohol consumption or smoking.

### Examination of patient

The blood pressure of patient was 130/80 mm of Hg on supine position. The pulse rate was 76 beats per minute. The patient had mild pallor, no icterus, no lymphadenopathy, no cyanosis, no clubbing, no edema, no dehydration.

Per Abdomen, Cardiovascular, Respiratory, CNS examination yielded normal findings.

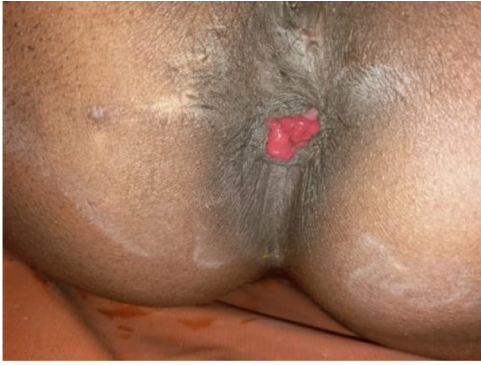### Local examination

Inspection on Lithotomy position – No any abnormalities detected.

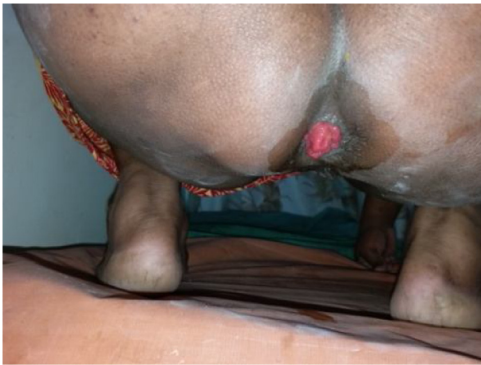On straining: Small circumferential mucosal protrusion present (Figs. 1–8).

Digital Rectal Examination: Patulous anal verge with hypotonic anal sphincter admitting 2 fingers easily.

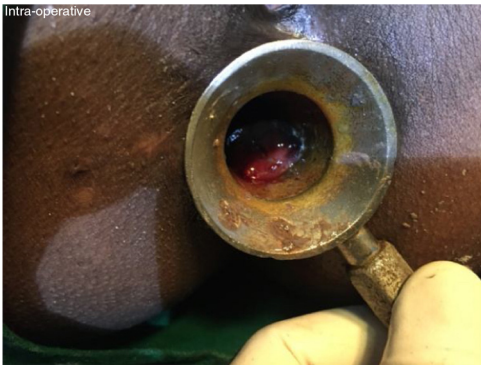Proctoscopy: Easily permissible proctoscope due to lax anal sphincter.



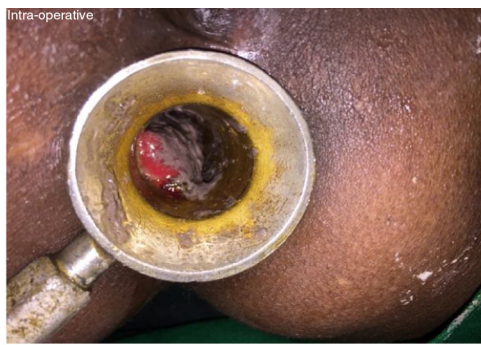**Fig. 1 - Straining on Lithotomy position.**



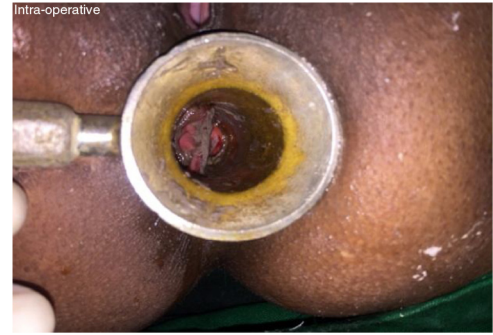**Fig. 2 - Straining on Squatting position.**



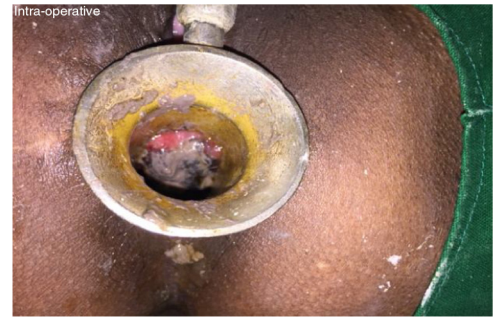**Fig. 3 - Kshara application.**



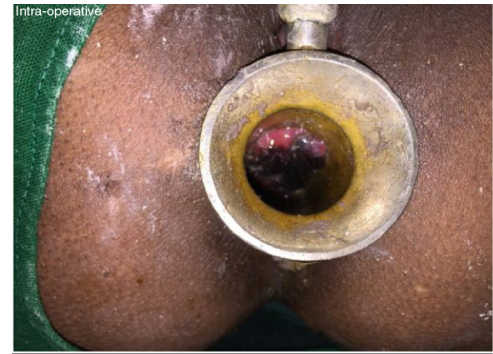
**Fig. 4 - Kshara application.**



**Fig. 5 - Kshara application.**



**Fig. 6 - Kshara application.**



**Fig. 7 - Blackish discolouration after Ksharakarma.**



**Fig. 8 - After circumferential Kshara application.**

**Table 1 – Laboratory investigations.**

Hemoglobin	9.8 g%
Total leucocytic count	10,500 cells/cmm
Differential leucocytic count	Neutrophils-70, lymphocytes-40, monocytes-2, eosinophils-3, basophils-0
Fasting blood sugar	102 mg/dL
Post-prandial blood sugar	130 mg/dL

Then, the patient was taken on Squatting position: On Inspection with straining circumferential mucosal prolapse (about 3 cm) present.

### Investigations (Table 1)

#### Diagnosis

Partial Rectal Prolapse (Gudabhramsa).

#### Treatment

After all laboratory investigations and pre-operative evaluations, Kshara karma (application of checmical cautery) with Apamarga Pratisaraneeya Kshara (Alkaline preparation made where *Achyranthes aspera* is used) was planned for the patient.

#### Preoperative procedure

Keeping the patient Nil by mouth from 6 h prior to surgery;

Written surgical consent;

Part preparation;

Inj. Tetanus Toxoid 0.5 cc intramuscular stat;

Inj. Lignocaine test dose 0.2 cc intradermal stat;

Proctoclysis enema.

#### Intraoperative procedure

Under spinal anesthesia patient taken on Lithotomy position.

Painting and draping at the perianal site.

Slit Proctoscopy and application of Apamarga Pratisaraneeya Kshara on the anal and rectal mucosa circumferentially extending from the mucocutaneous junction outside to 1 cm above the ano-rectal junction.

After 100 seconds the part applied with Kshara becomes dark (Jambuphala Sadrisha) and then it was gently washed with Nimbu Swaras (fresh lemon juice).

The same procedure was repeated circumferentially until all the anal mucosa was applied.

Anal pack of gauze soaked with Yastimadhu taila (oil where *Glycyrrhiza glabra* is the chief ingredient).

Dressing the wound done and the patient shifted to Post-operative ward.

#### Postoperative procedure

Nil by mouth till next 6 h;

Intravenous fluids;

Intravenous antibiotics and analgesics;

Tab. Anuloma DS (herbal Laxative) 2 tab per oral at night;

Sitz bath TID;

Matra Basti (Oil enema) with Yastimadhu Taila 20 mL after dressing B.D.

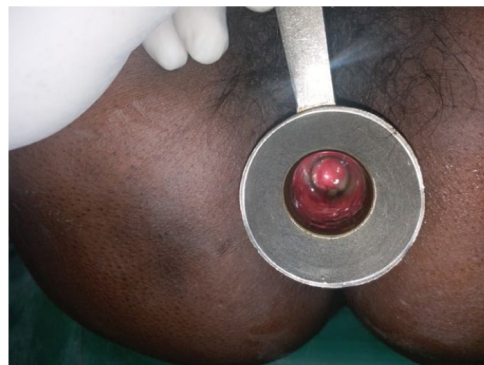Observations (After 1 week) (Table 2)

**Table 2 – BT-AT comparison after 1 week of Kshara Karma.**

Parameters	Before treatment	After treatment
Mass per rectum (during straining)	Present	Absent (Fig. 10)
Streaks of blood	Present	Absent
Intermittent constipation	Present	Very rare
Intermittent tenesmus	Present	Absent
Excessive mucus discharge (wetting of undergarments)	Present	Present (quantity reduced)

**Table 3 – BT-AT comparison after 1 month of Kshara Karma.**

Parameters	Before treatment	After treatment
Mass per rectum (during straining)	Present	Absent
Streaks of blood	Present	Absent
Intermittent constipation	Present	Absent
Intermittent tenesmus	Present	Absent
Excessive mucus discharge (wetting of undergarments)	Present	Absent



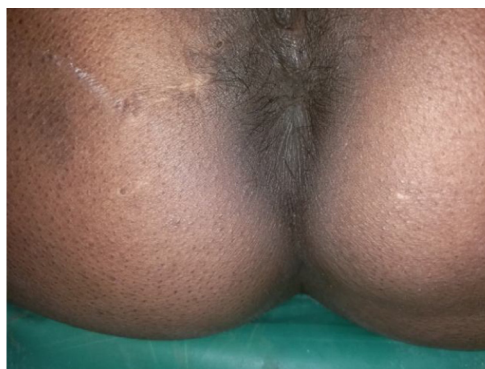**Fig. 9 – (AT) Proctoscopy examination.**

Observations (After 1 month) (Table 3)

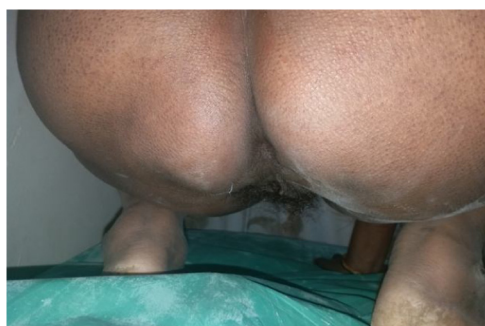After 1 week of treatment (Figs. 9–11)

## Discussion

Rectal prolapse is basically treated by surgery. There are diverse surgical options for the management of rectal prolapse indicating that the precise etiology and treatment guidelines have not been clearly established.<sup>10</sup> Among the surgeries for rectal prolapse, perineal approaches has higher recurrence rates (5–21%)<sup>11–13</sup> and reduced improvement of fecal incontinence whereas abdominal approaches are accompanied by significant incidence of peritoneal adhesions, longer recovery time, greater morbidity and possible compromise of sexual



**Fig. 10 – (AT) Straining on Lithotomy position.**



**Fig. 11 – AT Straining on Squatting position.**

function.<sup>7</sup> In Ayurveda, Acharya Susruta has proposed the line of conservative management as repositioning of prolapsed rectum after mild sudation and oil application followed by mechanical support for the ano-rectal region by special leather bandage (Gophana bandha). Susruta also stresses on Vata alleviating treatment (especially Apaana Vata) through the local and oral use of Musikadya Taila (oil prepared by mixing rats' carcasses removing intestines, milk, Vrihatpanchamoola plants and other Vata pacifying plants).<sup>14</sup> Susruta also explains the surgical management of Gudabhramsa (rectal prolapse) by the application of Kshara (caustics).<sup>15</sup> Kshara application is proposed to induce aseptic fibrosis of the anal mucosa and adheres it properly. During the wound healing process it causes cicatrization and strengthens the anorectal ring. In this case, the symptoms of the patient which were present before treatment were markedly reduced at the 7th post-operative day (Table 2). Chief complaint of mass per rectum was not present at all (Fig. 10). Unlike other symptoms, mucus discharge was not completely reduced up to 7th post-operative day but the Matra Basti (medicated oil enema) was continued and the complaint was absent after 1 month of surgery.

## Conclusion

Rectal prolapse is a very debilitating condition which lacks exact management guidelines. Different surgical procedures

have different disadvantages. Kshara Karma (chemical cauterisation) has been very beneficial on the management of rectal prolapse owing to the post-operative symptoms and complications too as in the aforementioned case. It can be done under local anesthesia as a day care surgery and is very cost effective. So, Kshara Karma can be a boon for the management of rectal prolapse.

## Conflicts of interest

The authors declare no conflicts of interest.

## REFERENCES

1. Singhal GD, Editor (reprint). *Susruta Samhita ancient Indian surgery, Part-1, Nidana Sthana; Kshudraroga Nidanam: Chapter 13, Verse 61.* Delhi: Chaukhamba Sanskrit Pratishthan; 2015:599.
2. Ballantyne GH. *The historical evolution of anatomic concepts of rectal prolapse.* *Semin Colon Rectal Surg.* 1991;2:170–9.
3. Kairaluoma MV, Kellokumpu IH. *Epidemiologic aspects of complete rectal prolapse.* *Scand J Surg.* 205;94:207–10.
4. Townsend Courtney M, Beauchamp R. Daniel, Evers Mark B, Mattox Kenneth L. *Sabiston textbook of surgery, 2, 18th India: Elsevier; 2010.*
5. Bordeianou L, Hicks CW, Kaiser AM, Alavi K, Sudan R, Wise PE. *Rectal prolapse: an overview of clinical features, diagnosis, and patient-specific management strategies.* *J Gastrointest Surg.* 2014;18:1059–69.
6. Varma M, Rafferty J, Buie WD. *Standards Practice Task Force of American Society of Colon and Rectal Surgeons Practice parameters for the management of rectal prolapse.* *Dis Colon Rectum.* 2011;54:1339–46.
7. Ashley Stanley W, Cance William G, Chen Herbert, Jurkovich Gregory J, Napolitano Lena M, Pemberton John H, et al. *ACS surgery: principles and practice, 2, 7th ed India: Jaypee Brothers Medical Publishers; 2014.*
8. Singhal GD, Editor (reprint). *Susruta Samhita ancient Indian surgery, Part-2, Chikitsa Sthana; Kshudraroga Chikitsa: Chapter 20, Verse 61-62.* Delhi: Chaukhamba Sanskrit Pratishthan; 2015:352.
9. Murthy KR. Srikantha, translator (2nd ed.) *Astanga Samgraha of Vagbhata, Nidanasthana; Atisara Chikitsam: Chapter 11, Verse 14-15.* Varanasi: Chaukhamba Orientalia; 1999:401–2.
10. Jin shin E. *Surgical treatment of Rectal Prolapse; 2011.* Retrieved from: [https://www.researchgate.net/publication/50832433\\_Surgical\\_Treatment\\_of\\_Rectal\\_Prolapse](https://www.researchgate.net/publication/50832433_Surgical_Treatment_of_Rectal_Prolapse) [9.01.19].
11. Johansen OB, Wexner SD, Daniel N, Nogueras JJ, Jagelman DG. *Perineal rectosigmoidectomy in the elderly.* *Dis Colon Rectum.* 1993;36:767.
12. Lechaux JP, Lechaux D, Perez M. *Results of the Delorme procedure for rectal procedure: advantage of a modified technique.* *Dis Colon Rectum.* 1995;38:301.
13. Ripstein CB. *Surgical treatment of rectal prolapsed.* *Pac Med Surg.* 1967;75:329.
14. Singhal GD, Editor (reprint). *Susruta Samhita ancient Indian surgery, Part-2, Chikitsa Sthana; Kshudraroga Chikitsam: Chapter 20, Verse 61-62.* Delhi: Chaukhamba Sanskrit Pratishthan; 2015:352.
15. Singhal GD, Editor (reprint). *Susruta Samhita ancient Indian surgery, Part-2, Chikitsa Sthana; Arsha Chikitsam: Chapter 6, Verse 8.* Delhi: Chaukhamba Sanskrit Pratishthan; 2015:222.