

Cutting of Sphincter in Fistulectomy with Primary Closure in Complex Fistula-in-Ano: Is it Feasible?

Amrendra Verma¹ Reena Kothari² Dhananjaya Sharma² Pawan Agarwal²

¹Department of General Surgery, Netaji Subhash Chandra Bose Medical College and Hospital, Jabalpur, Madhya Pradesh, India

²Department of Emergency Medicine, Department of General Surgery, Division of Surgery, NSCB Medical College, Netaji Subhash Chandra Bose Medical College and Hospital, Jabalpur, Madhya Pradesh, India

Address for correspondence Amrendra Verma, MBBS MS DNB, Netaji Subhash Chandra Bose Medical College and Hospital, Jabalpur, Madhya Pradesh, India (e-mail: verma.amrendra4@gmail.com).

J Coloproctol 2023;43(3):e204–e207.

Abstract

Introduction Treatment of complex fistulas such as inter- or transsphincteric, recurrent, and high fistulae have high rate of recurrence or incontinence. Fistulectomy with primary sphincter reconstruction might represent an effective and safe alternative to reduce rate of recurrence and incontinence. The aim of this study is to assess incontinence and recurrence after fistulectomy with primary sphincter reconstruction for management of complex fistulas.

Material and Methods There were 60 patients with complex fistulae involving the sphincter, with 56 male and 4 female, mean age 40.6 years, operated by fistulectomy and primary sphincter repair over a period of 7 years. Patients were followed up for 6 months for any complications, recurrence, and incontinence.

Results The majority of patients (50, 83.3%) had complete wound healing in 2 weeks, while 4 (6.6%) patients had hematoma and superficial wound dehiscence, which were managed conservatively and healed in 4 weeks. There was one recurrence. All patients had good continence postoperatively, except for mild fecal incontinence (FI, score 3), seen in 6 (10%) patients. However, all these patients regained continence within 6 weeks.

Conclusions Primary reconstruction of anal sphincter with fistulectomy is a safe option for complex fistula-in-ano.

Keywords

- ▶ anal sphincter
- ▶ fistulectomy
- ▶ complex fistula-in-ano
- ▶ primary sphincteroplasty

Introduction

The treatment of complex anal fistula is challenging, and one has to weigh recurrence against incontinence. Many surgical and conservative procedures have been described in the treatment of anal fistulas and can be divided in to cutting (fistulotomy and fistulectomy with primary sphincter reconstruction) and noncutting (endorectal advancement flap,

fibrin sealant injection, and fistula plug) procedures.¹ Complex fistulas such as inter- and transsphincteric, recurrent and high fistulae consist of 23 to 70% of total fistulae.² Surgical management of these fistulae results in recurrence rates between 0 and 65% and postoperative incontinence between 0 and 63%.³ Total sphincter-preserving surgery may result in a high rate of recurrence, while the more radical approaches may lead to fecal continence. Therefore,

received

May 14, 2023

accepted after revision

July 19, 2023

DOI <https://doi.org/10.1055/s-0043-1774726>.

ISSN 2237-9363.

© 2023. Sociedade Brasileira de Coloproctologia. All rights reserved.

This is an open access article published by Thieme under the terms of the Creative Commons Attribution-NonDerivative-NonCommercial-License, permitting copying and reproduction so long as the original work is given appropriate credit. Contents may not be used for commercial purposes, or adapted, remixed, transformed or built upon. (<https://creativecommons.org/licenses/by-nc-nd/4.0/>)

Thieme Revinter Publicações Ltda., Rua do Matoso 170, Rio de Janeiro, RJ, CEP 20270-135, Brazil

fistulectomy with primary sphincter reconstruction might represent an effective and safe alternative, as it has a lower rate of recurrence and incontinence.

Fistulectomy and primary sphincter reconstruction have not gained great popularity due to the risk of sphincter damage. However, patients with third- and fourth-degree perineal tear can achieve continence after primary sphincter repair.⁴⁻⁷ This forms the basis of primary surgical reconstruction of the anal sphincter for treatment of complex fistulas. The aim of this study is to assess incontinence and recurrence after fistulectomy with primary sphincter reconstruction for management of complex fistulae.

Materials and Methods

This prospective interventional study was conducted in the tertiary referral center in central India. Prior approval from the institution's Ethical Committee and informed consent from patients were obtained. All the patients older than 18-years having complex fistulae, fistula with multiple external openings, and ASA I & II were included. Patients younger than 18-years, with ASA > II, with coagulation disorder, and those unwilling were excluded. Diagnosis was made by clinical history, as well as digital-rectal and proctoscopic examination. Digital x-ray and magnetic resonance imaging (MRI) fistulograms of the perineal region were done when required.

Both pre- and postoperative fecal incontinence (FI) were assessed by the Wexner continence grading system. This scale assesses the continence on a scale from 0 to 20, with a

score of 0 meaning perfect continence and 20 as total incontinence.⁸

Operative Technique

The patients were placed in lithotomy position under spinal/general anesthesia. The fistulous tract and internal opening were delineated with 5 Fr feeding tube and methylene blue dye. The tract was excised from external opening to internal opening with the help of monopolar cautery, after giving traction to fistula tract. In case of intersphincteric and transsphincteric fistulae, sphincter fibers were sharply cut to dissect the fistulous tract. The tract was excised completely. After complete excision of fistula, the mucosal layer was repaired by polyglactin continuous suture to make it watertight from cranial to caudal end. Then, the sphincter's muscle fibers were identified and repaired in layers by interrupted polyglactin 2-0 suture with an overlapping technique. A corrugated drain is placed in the cavity and taken out from the separate incision, which was removed on the 5th day. Skin and subcutaneous tissue were closed with an interrupted polyglactin 2-0 suture (► Fig. 1).

Postoperative Care

Antibiotics were given 12 hours before surgery, at the time of induction of anesthesia, and continued up to the 3rd post operative day. Perineal wound care included sitz's baths and local povidone-iodine ointment application. Patients were prescribed laxatives and analgesics according to need.

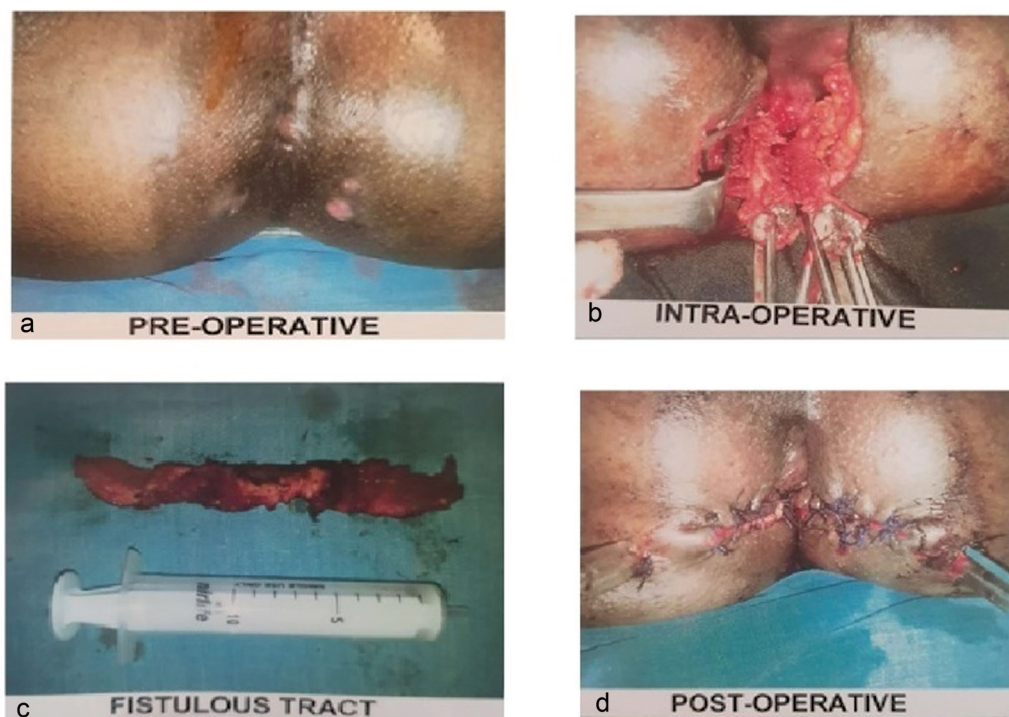


Fig. 1 Patient images a) preoperative, b) intraoperative, c) excised fistula tract, d) post operative.

Table 1 Postoperative negative outcomes

S no.	Outcome	No. of patients
1	Perianal hematoma/ wound dehiscence	4 (6.6%)
2	Fecal incontinence	6 (10%)
3	Recurrence	1 (1.6%)

Follow-up was done on the 2nd week, 4th week, 3-months, and 6-months for any complications, recurrence, and incontinence.

Results

There were 60 patients, 56 male and 4 female, operated for fistula over a period of 7 years (August 2012 to December 2019). Their ages ranged from 19 to 60 years (mean: 40.6 years). From the total, 50 patients had single external opening and 10 had multiple external openings. All patients had complex fistulae involving sphincters, including 14 transsphincteric (23.3%) and 46 intersphincteric (76.6%). In order of frequency, the presenting symptoms were pain (56.7%), swelling (33.3%), constipation (30%), and bleeding (10%).

The majority of patients (50, 83.3%), had complete wound healing in <2 weeks' time. However, 4 (6.6%) patients had hematoma and superficial wound dehiscence, which were managed conservatively and healed in 4 weeks (►Table 1).

None of the patient had preoperative incontinence. All patients had good continence postoperatively except mild fecal incontinence (score 3) was seen in 6 (10%) patients (►Table 2). All these patients had transsphincteric fistulas with multiple openings. However, all these patients regained

continence within 6 weeks without any intervention. One patient, who had tuberculosis as etiology, had a recurrence of fistula (►Table 3). Histopathological examination of the fistulous tract showed nonspecific granulation of tissues in 58 (96.6%) and tuberculosis in 2 (3.33%) patients. The mean postoperative hospital stay was 5.4 ± 1.5 days. The mean follow-up period was 6 months.

Discussion

The fact remains that an "ideal" procedure for anal fistula remains elusive. Treatment of anal fistula depends on anatomical relationships of the fistula with sphincter complex. Low fistulas can be treated in a single stage by fistulotomy with minimal risk of recurrence or incontinence.⁹ The complex fistulas include high transsphincteric, suprasphincteric, extrasphincteric, all anterior transsphincteric fistulas in women, and those caused by inflammatory diseases.¹⁰ However, fistulotomy, even for "simple" fistula, can result in some form of incontinence in approximately 12% of patients.¹¹ This makes management of high complex fistulas even more challenging, because cure has to be weighed against incontinence.

In an attempt to preserve continence, various noncutting procedures such as simple drainage (seton), fibrin sealant, or anal fistula plug, endorectal or dermal flaps, and ligation of intersphincteric fistula tract (LIFT) have been proposed. Though these procedures result in low rate of incontinence but recurrence rate is significantly higher, and their long-term efficacy needs to be clarified in large long-term randomized trials.¹²

In search of an ideal treatment (associated with low recurrence rates, minimal incontinence, and good quality of life) for anorectal fistulae, fistulectomy with primary reconstruction of sphincter has been tried. However, primarily cutting the

Table 2 Postoperative outcomes – FI

FI score*	Preoperative	Postoperative			
		2 weeks	4 weeks	3 months	6 months
0–3 (mild)	Nil	6 (10%)	1 (1.6%)	Nil	Nil
4–8 (moderate)	Nil	Nil	Nil	Nil	Nil
9–20 (severe)	Nil	Nil	Nil	Nil	Nil

Abbreviation: FI, fecal incontinence. Note: *According to the Wexner continence grading scale.

Table 3 Classification of fistula in relationship with sphincter

Type of fistula*	External Openings	N = 60 (100%)	FI = 6 (10%)	Recurrence = (1.6%)	Etymology
Extrasphincteric	–	Nil	–	–	–
Suprasphincteric	–	Nil	–	–	–
Transsphincteric	Single	5 (8.3%)			–
	Multiple	9 (15%)	5 (8.3%)	1 (1.6%)	Tuberculosis
Intersphincteric	Single	45 (75%)	–	–	–
	Multiple	1 (1.6%)	1 (1.6%)	–	–
Submucosal	–	Nil	–	–	–

Abbreviation: FI, fecal incontinence. Note: *According to Parks et al.'s classification of fistula-in-ano.²

sphincter to remove fistula tract is regarded with skepticism.^{13,14} Loss of sphincter integrity may cause loss of neuromuscular coherence, which is responsible for continence. Furthermore, the lower risk of incontinence after sphincter cutting has been demonstrated by comparative anatomical studies, which show the uniqueness of this surgical procedure and provide adequate data. Therefore, continence will be maintained even when part of the ring musculature needs to be divided in patients with high anorectal fistulae.¹⁵ The other mechanism that helps maintenance of continence in primary reconstruction techniques include reconstruction of the sphincter with an overlapping technique that enhances the resistance of the sphincter by increasing functional sphincter length.⁶ The rate of incontinence for fistulectomy and sphincter reconstruction differs between 3.6 and 21.7%, with minor incontinence in most cases. Furthermore, the risk of sphincter dehiscence after overlapping sphincter reconstruction is low.¹⁶⁻²¹

Better understanding of physiology and anatomy of anorectal sphincter leads to venturing the surgeons to cutting the sphincter, removing the fistula and resuturing to preserve continence. Patients with third- and fourth-degree perineal tear achieved good continence after primary sphincter repair and only a few experienced incontinence of flatus. Though some of them will have persistent sonographic external and internal anal sphincter defect, none will have clinically evident incontinence.⁴⁻⁷ Sceptics believe this radical approach seems logical for malignancy or incontinent patients following third degree perineal tear or congenital malformations. However, using same approach for benign disease like fistula-in-ano is not justifiable, especially if few patients become incontinent. One must define the exact indications for this technique and, presently, complex high fistulas and recurrent fistula may be the only ones.

In this study, complex fistulae were treated by fistulectomy and primary sphincter repair with low rate of recurrence. Also, few patients developed mild fecal incontinence, which recovered spontaneously. Cases of FI were more common in transsphincteric fistulas with multiple openings due to weakening of both internal and external anal sphincters.

To summarize, in cases of complex fistula-in-ano, complete removal of disease may require surgical interference in the sphincter's muscle fibers. Our study has shown good results after primary reconstruction of sphincter. However, limitations of the study include subjective assessment of FI, because of nonavailability of rectal ultrasonography and anorectal manometry.

Conclusion

Primary reconstruction of anal sphincter with fistulectomy is a safe, option for intersphincteric and transsphincteric, complex, high, and recurrent fistula-in-ano. However, the risk of postoperative minor fecal incontinence should be discussed with patients preoperatively.

Conflict of Interests

The authors have no conflict of interests to declare.

References

- Soltani A, Kaiser AM. Endorectal advancement flap for cryptoglandular or Crohn's fistula-in-ano. *Dis Colon Rectum* 2010;53(04):486-495
- Parks AG, Gordon PH, Hardcastle JD. A classification of fistula-in-ano. *Br J Surg* 1976;63(01):1-12
- Arroyo A, Pérez-Legaz J, Moya P, et al. Fistulotomy and sphincter reconstruction in the treatment of complex fistula-in-ano: long-term clinical and manometric results. *Ann Surg* 2012;255(05):935-939
- Sultan AH, Monga AK, Kumar D, Stanton SL. Primary repair of obstetric anal sphincter rupture using the overlap technique. *Br J Obstet Gynaecol* 1999;106(04):318-323
- Rasmussen OØ. Fecal incontinence. Studies on physiology, pathophysiology and surgical treatment. *Dan Med Bull* 2003;50(03):262-282
- Lestár B, Asztalos I, László S, et al. [Possibilities in the preservation and restoration of anal continence]. *Magy Seb* 2001;54(03):168-173
- Fitzpatrick M, Behan M, O'Connell PR, O'Herlihy C. A randomized clinical trial comparing primary overlap with approximation repair of third-degree obstetric tears. *Am J Obstet Gynecol* 2000;183(05):1220-1224
- Jorge JM, Wexner SD. Etiology and management of fecal incontinence. *Dis Colon Rectum* 1993;36(01):77-97
- Vasilevsky CA, Gordon PH. The incidence of recurrent abscesses or fistula-in-ano following anorectal suppuration. *Dis Colon Rectum* 1984;27(02):126-130
- Loungnarath R, Dietz DW, Mutch MG, Birnbaum EH, Kodner IJ, Fleshman JW. Fibrin glue treatment of complex anal fistulas has low success rate. *Dis Colon Rectum* 2004;47(04):432-436
- Garcia-Aguilar J, Belmonte C, Wong WD, Goldberg SM, Madoff RD. Anal fistula surgery. Factors associated with recurrence and incontinence. *Dis Colon Rectum* 1996;39(07):723-729
- Cadeddu F, Salis F, Lisi G, Ciangola I, Milito G. Complex anal fistula remains a challenge for colorectal surgeon. *Int J Colorectal Dis* 2015;30(05):595-603. Doi: 10.1007/s00384-014-2104-7
- Parkash S, Lakshmiratan V, Gajendran V. Fistula-in-ano: treatment by fistulectomy, primary closure and reconstitution. *Aust N Z J Surg* 1985;55(01):23-27
- Ratto C, Litta F, Donisi L, Parello A. Fistulotomy or fistulectomy and primary sphincteroplasty for anal fistula (FIPS): a systematic review. *Tech Coloproctol* 2015;19(07):391-400
- Stelzner F. The morphological principles of anorectal continence. *Prog Pediatr Surg* 1976;9:1-6
- Roig JV, García-Armengol J, Jordán JC, Moro D, García-Granero E, Alós R. Fistulectomy and sphincteric reconstruction for complex cryptoglandular fistulas. *Colorectal Dis* 2010;12(7 Online):e145-e152
- Lewis A. (1996) Core out. In: Phillips RKS, Lunniss PJ, eds. *Anal fistula: surgical evaluation and management*. London, UK: Chapman & Hall; 81-6
- Seyfried S, Bussen D, Joos A, Galata C, Weiss C, Herold A. Fistulectomy with primary sphincter reconstruction. *Int J Colorectal Dis* 2018;33(07):911-918. Doi: 10.1007/s00384-018-3042-6
- Farag AFA, Elbarmelgi MY, Mostafa M, Mashhour AN. One stage fistulectomy for high anal fistula with reconstruction of anal sphincter without fecal diversion. *Asian J Surg* 2019;42(08):792-796. Doi: 10.1016/j.asjsur.2018.12.005
- Iqbal N, Dilke SM, Geldof J, et al. Is fistulotomy with immediate sphincter reconstruction (FISR) a sphincter preserving procedure for high anal fistula? A systematic review and meta-analysis. *Colorectal Dis* 2021;23(12):3073-3089. Doi: 10.1111/codi.15945
- Maqbool J, Mehraj A, Shah ZA, et al. Fistulectomy and incontinence: do we really need to worry? *Med Pharm Rep* 2022;95(01):59-64. Doi: 10.15386/mpr-2045