


# Therapeutics in Radiation-induced Proctopathy: A Systematic Review

Nathália Nascentes Coelho dos Santos Omer<sup>1</sup>  Ivana Duval de Araujo<sup>2</sup>  
Geraldo Magela Gomes da Cruz<sup>3</sup> Fábio Gontijo Rodrigues<sup>3</sup>

<sup>1</sup> Postgraduate Department in Sciences Applied to Surgery and Ophthalmology, Universidade Federal de Minas Gerais (UFMG), Minas Gerais, Brazil

<sup>2</sup> Doctor and Associate Professor IV, Department of Surgery, Universidade Federal de Minas Gerais, Brazil

<sup>3</sup> Coloproctologist in charge, Sociedade Brasileira de Coloproctologia, Brazil

Address for correspondence Nathália Nascentes Coelho dos Santos Omer, Rua Desembargador Drumond, 113/402, Serra, CEP 30220-030 Belo Horizonte, Minas Gerais, Brazil  
(e-mail: nathy\_nascentes@hotmail.com).

J Coloproctol 2022;42(1):85–98.

## Abstract

Malignant neoplasms are increasingly prevalent in the daily clinical practice. Up to 61% of patients with pelvic malignancies undergo pelvic radiotherapy in different doses, which may cause intestinal damage, and the rectum is the segment most frequently affected due to its fixed position in the pelvis. Currently, there are several strategies to minimize the effects of radiation on the tissues surrounding the neoplastic site; despite those strategies, radiotherapy can still result in serious damage to organs and structures, and these injuries accompany patients throughout their lives. One of the most common damages resulting from pelvic radiotherapy is acute proctitis. The diagnosis is confirmed by visualizing the rectal mucosa through rigid or flexible rectosigmoidoscopy and colonoscopy. The objective of the present study was to review the forms of radiation-induced proctopathy therapy, and to evaluate the results of each method to propose a standardization for the treatment of this pathology. Despite the prevalence of radiation-induced proctopathy, there is no definitive standardized treatment strategy so far. The first approach can be tried with local agents, such as mesalazine and formalin. For refractory cases, control can usually be achieved with argon plasma coagulation, hyperbaric oxygen, and radiofrequency ablation therapies. Regarding the study of radiation-induced proctopathy, there is a lack of robust studies with large samples and standardized therapies to be compared. There is a lack of double-blinded, randomized controlled studies to determine a definitive standard treatment algorithm.

## Keywords

- ▶ actinic
- ▶ proctitis
- ▶ radiation proctopathy
- ▶ induced radiation

received  
August 3, 2021  
accepted after revision  
October 25, 2021

DOI <https://doi.org/10.1055/s-0041-1742258>.  
ISSN 2237-9363.

© 2022. Sociedade Brasileira de Coloproctologia. All rights reserved.

This is an open access article published by Thieme under the terms of the Creative Commons Attribution-NonDerivative-NonCommercial-License, permitting copying and reproduction so long as the original work is given appropriate credit. Contents may not be used for commercial purposes, or adapted, remixed, transformed or built upon. (<https://creativecommons.org/licenses/by-nc-nd/4.0/>)

Thieme Revinter Publicações Ltda., Rua do Matoso 170, Rio de Janeiro, RJ, CEP 20270-135, Brazil

## Introduction

Malignant neoplasms are increasingly prevalent in the daily clinical practice. According to data from the Brazilian National Cancer Institute (Instituto Nacional do Câncer, INCA, in Portuguese)<sup>1</sup> on the estimated incidence of tumors by gender in 2020, the most common sites for malignant neoplasms among men would be the prostate, the colon/rectum, and the respiratory system. Among women, the most common neoplasms would affect the breasts, the colon/rectum, and the cervix.

Considering these estimates, more than 65 thousand men were expected to be diagnosed with prostate cancer, and more than 16 thousand women were expected to be diagnosed with cervix cancer in Brazil in 2020.<sup>1</sup> Both of these neoplasms, of pelvic location, have radiotherapy as an important therapeutic strategy, as well as other urological, gynecological and gastrointestinal neoplasms (of the bladder, uterus, rectum, and anus).<sup>2</sup> Up to 61% of patients with pelvic malignancies undergo pelvic radiotherapy in different doses, which may cause intestinal damage, and the rectum is the segment most frequently affected due to its fixed position in the pelvis.<sup>3-6</sup>

Pelvic radiotherapy can be delivered mainly by two routes: brachytherapy or an external beam. In external beam radiation, a linear accelerator is used to apply the radiation from outside the body through a two- or three-dimensional plane.<sup>5</sup> In brachytherapy, radiation is generated by implants placed on the patient, and it has the advantage of providing a more localized action with a lower incidence of injuries to adjacent tissues. Currently, there are several strategies to minimize the effects of radiation on tissues surrounding the neoplastic site, such as better patient positioning and containment devices, in addition to increasingly better technology for radiation generators.<sup>5</sup> Despite those strategies, radiotherapy can still result in serious damage to organs and structures, and these injuries accompany patients throughout their lives.

It is estimated that 1.5 to 2 million patients who have survived cancer suffer from dysfunctions of the gastrointestinal tract due to radiation-induced injuries.<sup>5</sup> One of the most common damages resulting from pelvic radiotherapy is acute proctitis. Late complications of pelvic radiotherapy also include bleeding, anemia, strictures, fistulas, and anorectal dysfunction, and they occur in up to 20% of the cases.<sup>7</sup> Irradiation of the pelvic region, when in contact with the rectum and distal sigmoid colon, can induce mucosal or even transmural damage.<sup>5,8</sup>

The incidence of radiotherapy-induced proctitis varies from 5% to 20%,<sup>9,10</sup> and depends on many factors, such as the technique of application of the radiation and the dose used. Typically, the maximum dose of radiation that is well tolerated by the colon and rectum is around 60 Gy, but, in some cases, such as in cases of cervical cancer, the total dose can reach 85 Gy.<sup>5</sup> There is a relationship between the dose of radiation and the occurrence of proctitis. Doses lower than 45 Gy will rarely cause any permanent damage to the rectum, with the opposite being observed with doses higher than 70 Gy.<sup>11</sup> In addition to the total dose of radiation, the dose per session, the technique, and the number of treatment rounds are also essential to

assess the risk of complications associated with radiotherapy.<sup>12</sup> Other factors inherent to the patient or the proposed treatment are also responsible for the increase in the incidence of proctitis. The presence of previous vascular disease, diabetes, and inflammatory bowel disease,<sup>5,13</sup> and habits such as alcohol consumption and smoking,<sup>5,13,14</sup> as well as the combination of chemotherapy and radiotherapy are some factors associated with an increased risk of developing radiotherapy-induced proctitis.

Radiotherapy-induced proctitis results from the effect of radiation on the intestinal wall, with the mucosa and submucosa being the most affected layers.<sup>16</sup> The pathogenesis of radiotherapy-induced proctitis has not been fully elucidated yet.<sup>5</sup> Pathological changes after irradiation begin within hours.<sup>15</sup> The radiation acts leading to cell death and apoptosis due to damage to cell DNA, lipids, and proteins.

The result is the occurrence of vascular sclerosis, obliterating arteritis, submucosal fibrosis, mucosal damage, and cellular infiltrate.<sup>6,16</sup> The initial acute reaction occurs in the first weeks of treatment, and late complications such as bleeding, pain, diarrhea, and stenosis can occur years later.<sup>17</sup> The average time until the onset of symptoms is usually 8 to 12 months.<sup>6,18</sup>

The injury caused by radiation in the rectum can be acute or chronic.<sup>8</sup> Radiotherapy-induced proctitis can be acute when it occurs within 3 months after the beginning of the radiotherapy, in which case it is usually self-limited (up to 6 months) and results from damage to the rectal mucosa.<sup>5,8,18,19</sup> This phase is characterized microscopically by the presence of erosion of the lining epithelium and inflammatory infiltrate in the mucosal and submucosal layers. In ~35% of patients, the symptoms are mild and cease spontaneously without the need for any treatment.<sup>19</sup> Chronic proctitis (which, by definition, occurs 3 months after the beginning of the radiotherapy) can take up to years to occur, with an average of 8 to 12 months after the radiotherapy.<sup>8,20</sup> In the case of chronic proctitis, the pathophysiology involves an alteration in the vascular supply of the rectal wall, leading to fibrosis, transmural thickening, ulceration, and progressive obliterating enteritis.<sup>4</sup> In the chronic phase, there is no associated inflammatory process, and the histopathological findings result from small-vessel vasculopathy. The acute phase usually progresses to the chronic phase, but sometimes it can be less symptomatic, which creates a false impression of complete healing of the lesion. On the other hand, the chronic phase can manifest itself as a latent and less symptomatic acute phase, which can also generate an erroneous feeling that there was no initial inflammatory process. The transition between the acute and chronic phases occurs gradually, and there is no fixed period of time to determine this progression (about two to three months, often).

Some pathological changes can be found during this progression regarding inflammation and fibrosis.<sup>21</sup> After the end of the radiation sessions, the cells of the intestinal crypt regenerate and the superficial mucosa is restored; however, for reasons still unknown, the response may be exaggerated, causing ulceration and progressive fibrosis – which characterize the chronic phase.<sup>5</sup> Between 5% and 20% of the patients will develop the chronic form.<sup>5</sup>

**Table 1** Conditions that should be considered in the differential diagnosis of radiotherapy-induced proctitis

Infectious colitis
Inflammatory bowel diseases
Exclusion colitis
Ischemic colitis
Colitis due to diverticular disease
Malignancy

It is important to carry out the correct diagnosis of radiotherapy-induced proctopathy, since the radiation itself, with the involvement of other intestinal segments, as well as psychological changes in the irradiated patient, can also cause gastrointestinal symptoms.<sup>20</sup> The diagnosis of radiotherapy-induced proctopathy is based on the clinical history of exposure to radiation due to pelvic neoplasia associated with symptoms and confirmed with imaging exams.<sup>2,8</sup> The diagnosis is confirmed by visualizing the rectal mucosa through rigid or flexible rectosigmoidoscopy and colonoscopy. In these, examinations the mucosa appears as friable, with edema, the presence of telangiectasias and, in more severe cases, extensive fibrosis with stenosis and the formation of fistulas can be observed.<sup>16</sup> The endoscopic diagnosis is important for the exclusion of other diseases that present with proctitis (► **Table 1**), and can also guide the proper indication of biopsies.<sup>2,12</sup> According to Vanneste et al.,<sup>2</sup> biopsies should only be performed in cases of suspected malignancy and, whenever possible, should be avoided on the wall corresponding to the irradiated organ.

Other findings such as rectal spasm, mucosal edema, and adynamic ileum can also be suggested by imaging exams during the acute phase.

The initial symptoms generally occur one to three weeks after radiotherapy, and they include vomiting, diarrhea, nausea, tenesmus, and rectal bleeding. Secondary symptoms, such as abdominal pain, nausea, vomiting, malabsorption,

tenesmus, hematochezia, and constipation, occur after three months.<sup>22</sup> Rectal bleeding is the most common symptom, and refractory bleeding is a common problem that sometimes requires transfusion.<sup>9,23</sup>

Based on the severity of the symptoms, proctitis can be graded from 0 to 4 according to the classifications of the Radiation Therapy Oncology Group (RTOG) and the European Organization for Research and Treatment of Cancer (EORTC)<sup>5</sup> (► **Table 2**).

Currently, there are no measures for the prevention of radiotherapy-induced proctopathy,<sup>5</sup> so early detection and treatment are important to mitigate the effects on the patient's quality of life. The best strategy to prevent its occurrence is by reducing the radiation dose and the irradiated area. Still, some studies support measures that could contribute to the reduction in the frequency and severity of radiotherapy-induced proctopathy:<sup>22</sup>

1. Use of anti-inflammatories and agents that promote the renewal of colonies such as probiotics, which produce short chain fatty acids (SCFAs). Butyrate-containing enemas may be used for this purpose;
2. Use of low-dose laxatives, fiber supplementation, and improved water intake to reduce the risk of mechanical injury;
3. Follow-up and early assessment of the patient exposed to radiotherapy; and
4. Treatment of chronic radiotherapy-induced proctopathy.

## Objective

The objective of the present study was to review the forms of radiation-induced proctopathy therapy, and to evaluate the results of each method to propose a standardization for the treatment of this pathology.

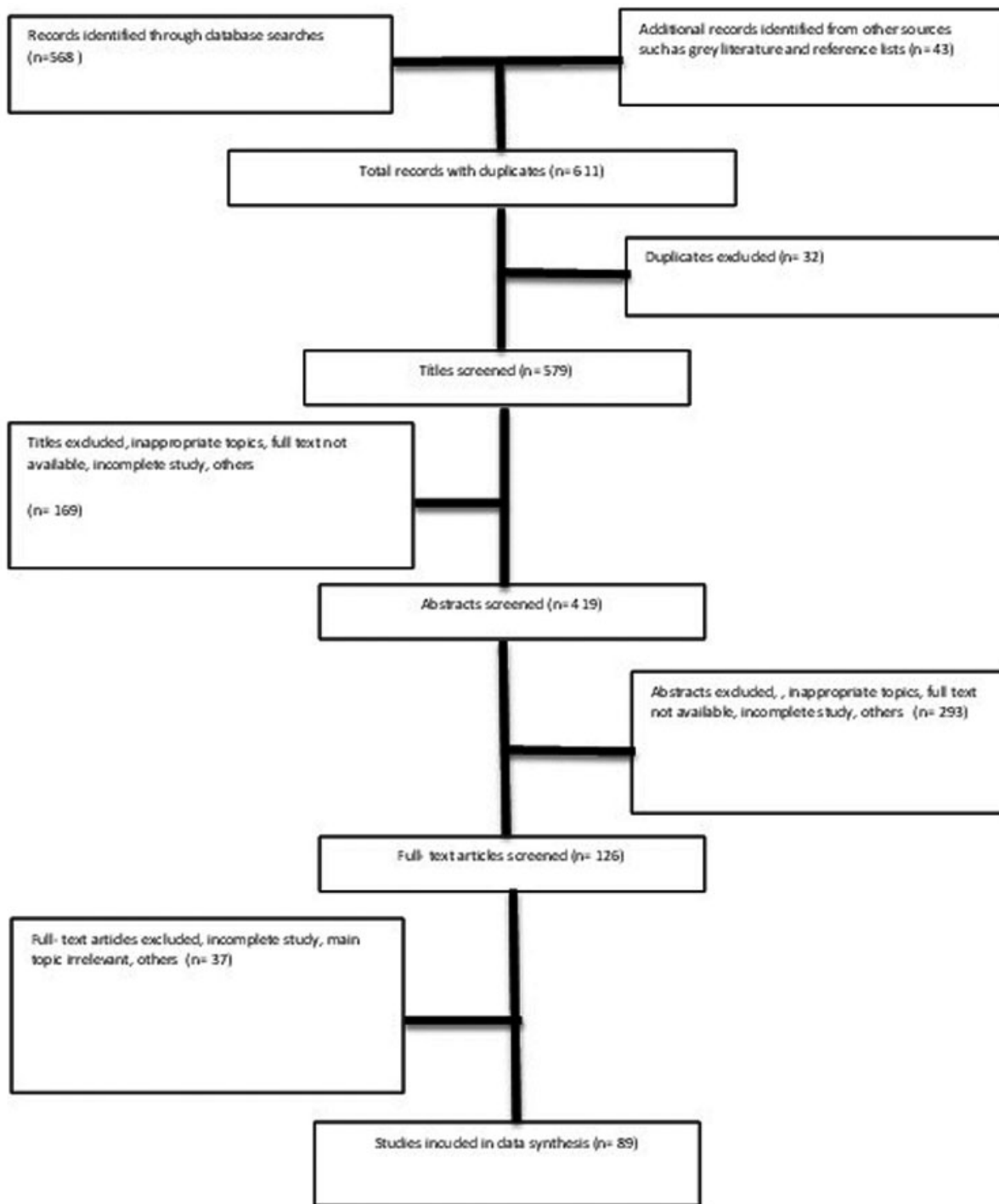
## Materials and Methods

A search was performed on the MEDLINE and CAPES databases in September 2018. The following terms were used: *radiation*, *radiation induced*, *radiotherapy induced*, *actinic*, *proctitis*, and

**Table 2** Acute and chronic radiation proctitis according to the RTOG/EORTC grading system

	Grade 0	Grade 1	Grade 2	Grade 3	Grade 4
Acute	Without changes	Increased frequency, change in bowel habits, or rectal discomfort that does not require painkillers	Diarrhea in need of parasympatholytic medication, mucorrhea that does not require an intimate protector, abdominal or rectal pain in need of analgesics	Diarrhea in need of parenteral support, mucorrhea and bleeding in need of the use of intimate protection, abdominal distention	Acute or subacute obstruction, fistula or perforation, bleeding from the gastrointestinal tract requiring transfusion, abdominal pain and tenesmus requiring decompression sounding, or colostomy
Chronic	Without changes	Mild diarrhea, bowel movement 5 times a day, mild anal bleeding, or mucorrhea	Diarrhea or moderate colic, more than 5 bowel movements a day, intermittent bleeding, or excessive mucorrhea	Obstruction or bleeding requiring surgery	Necrosis, perforation, or fistula

Abbreviations: EORTC, European Organization for Research and Treatment of Cancer; RTOG, Radiation Therapy Oncology Group.



**Fig. 1** Flowchart referring to how the research for articles was carried out.

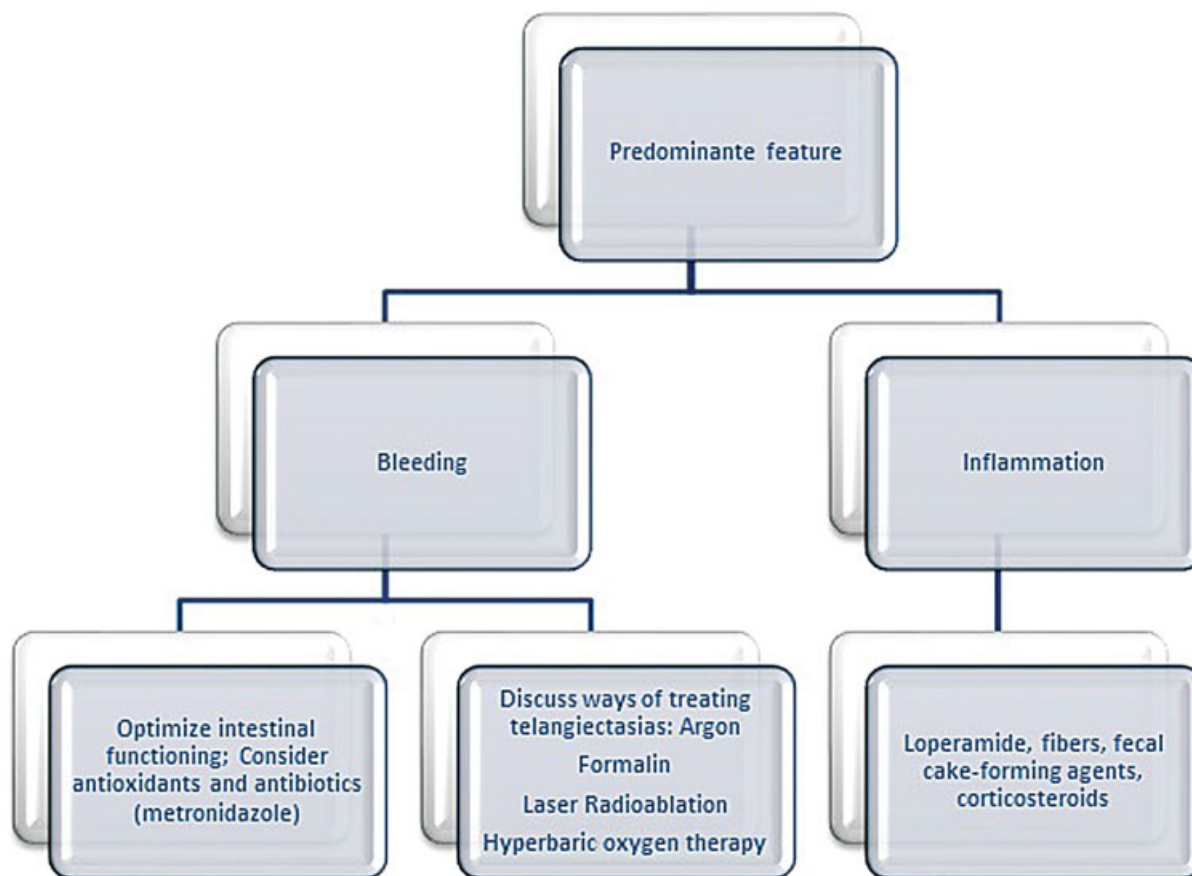
proctopathy. Initially, 611 articles were found, and all of them were analyzed. The searches were performed by two different researchers, both of whom found the same articles.

**Results**

The treatment for radiotherapy-induced proctopathy is still unsatisfactory, and there is only limited evidence supporting the current approaches.<sup>10</sup>

Of the 611 articles found, 89 were selected. Citations and articles with no scientific relevance were excluded, in addition to those whose results were inconclusive. Of all the articles evaluated, 67 addressed therapeutic options with response rates and possible complications. The remaining 22 articles were reviews on the topic (► Fig. 1).

The therapeutic options are medication (topical or oral), endoscopy and surgery.<sup>8</sup> In 5% to 10% of the cases, the disease



**Fig. 2** Treatment algorithm proposed by Vanneste et al.<sup>2</sup> (2015).

can become severe and refractory to the topical medication and endoscopic treatments.<sup>24</sup>

The initial management consists of dietary measures, and the use of fecal-bolus-forming agents, antispasmodics, and antidiarrheals.<sup>4</sup> The treatment should be based on the pattern of the radiotherapy-induced proctopathy, the severity of the symptoms and the experience of treatment.<sup>2</sup>

In 2015, Vanneste et al.<sup>2</sup> proposed an algorithm for the treatment of radiotherapy-induced proctopathy (► **Fig. 2**):

Regarding drug therapy, the arsenal is vast, and includes sucralfate, SCFAs, 5-aminosalicylic acid (5-ASA) derivatives, antibiotics, and corticosteroids.<sup>3,9,16,25</sup> Most patients have improved clinical status with topical treatments.<sup>24</sup> Another therapeutic option is endoscopy, which enables the administration of formalin, and the performance of cauterization with electrocautery, argon plasma coagulation, laser and radiofrequency ablation. No endoscopic treatment method has been evaluated by randomized studies that provided a standardized guide for its use.<sup>2</sup> Radiofrequency ablation of the rectal mucosa containing abnormal vascularization with microvessels and re-epithelialization is currently considered the treatment of choice by some authors.<sup>26</sup> The therapeutic methods that are indicated for this purpose, according to Vanneste et al.,<sup>2</sup> are formalin, argon plasma, radioablation, and hyperbaric oxygen (HO) therapy. The choice method should take into account several factors, especially local

availability. Another promising form of therapy is the use of 100% oxygen in a hyperbaric chamber.

Most studies cite argon plasma coagulation as the first line of treatment; however, due to its high cost, it still has some limitations regarding use in the daily clinical practice. In addition, it can result in rectal ulceration, stenosis, and even perforation.<sup>9</sup> Most of the time, combination therapies, such as local therapy with anti-inflammatory therapy<sup>9</sup> are beneficial for the patient, and should be an option in the treatment of refractory cases. Due to their greater availability, their effects on inflammatory bowel diseases, and their cost, the most used methods in the clinical practice are the administration of oral and topical anti-inflammatories and formalin.

The anti-inflammatory drugs used are those derived from 5-ASA, and they work by reducing the amount of free radicals, inhibiting prostaglandin biosynthesis, and altering the bacterial flora. The increase in inflammatory markers such as interleukins (ILs) 2, 6 and 8 occurs both in inflammatory bowel diseases and in radiotherapy-induced proctopathy, which would explain the similarity of the treatment of both diseases.<sup>27</sup> Despite being widely used for the treatment of inflammatory bowel diseases, there is still a lack of scientific data that support their use in radiotherapy-induced proctopathy. These agents can be used in the form of tablets administered orally or rectally, through enemas and suppositories.



Corticosteroids are also widely used, in the form of enemas, especially in more severe cases. Takemoto et al.<sup>21</sup> (2012) reported an efficacy of 62%, with no complications, with the use of steroid enemas. Corticosteroid enemas have been shown to have a limited long-term effect on chronic rectitis. They inhibit the cascades of arachidonic acid and cytokine, blocking the release of histamine and stabilizing the cell membrane.<sup>21</sup>

In relation to the most used endoscopic treatments, formalin is an aldehyde that induces coagulative necrosis after contact. It can provide good results even after a single application, but it also has side effects such as anal pain. Argon plasma coagulation is a thermal method of non-contact coagulation. It is safe because it has a maximum penetration of 3 mm in the rectal wall. It is more effective in mild cases, but it can also work in more severe cases.<sup>19</sup>

The supply of 100% oxygen via hyperbaric chamber is a method that is still not widely available in the clinical practice; it acts by inducing the growth of the vascular endothelium and reducing the amount of circulating free radicals. In 2008, Clarke et al.<sup>27</sup> reported a rate of 88.9% patients treated with 100% oxygen at 2 atm with no complications. Radiotherapy-induced proctopathy represents a challenge in the clinical practice, and, when bleeding persists despite all the measures, there are surgical procedures, such as diversion of intestinal transit by the creation of stomas, or resection of the affected organ.<sup>4</sup>

## Mesalazine

Mesalazine, or 5-ASA, is the the first-line therapy in the treatment of ulcerative colitis, either in its active or remission stage.<sup>28,29</sup> The excellent response of patients with colitis undergoing treatment with 5-ASA derivatives led to the attempt of also prescribing the therapy for patients with radiotherapy-induced proctopathy.<sup>24,30,31</sup> The use of 5-ASA derivatives is based on the increase in IL-2, IL-6 and IL-8, both in cases of inflammatory bowel diseases and radiotherapy-induced proctopathy.<sup>26</sup>

The most commonly used mesalazine compound has a formulation that dissolves when the pH  $\geq$  7, thereby acting from the ileum.<sup>29</sup> Another formulation is time-dependent, and begins its action in the stomach due to the presence of ethyl cellulose.<sup>29</sup> In 2010, Ito et al.<sup>29</sup> published a randomized, double-blinded study to compare the -pH-dependent and the time-dependent formulations. The study focused on the treatment of ulcerative colitis, and the authors reported a better effectiveness of the pH-dependent formulation.

In 1989, Baum et al.<sup>30</sup> described 4 patients who underwent pelvic radiotherapy with hematochezia. The treatment used was 4 g of 5-ASA via enema, once a day, for periods varying from 8 weeks to 7 months. The authors concluded that the treatment was ineffective in all patients. The effectiveness of mesalazine suppositories was proven in a multi-center, randomized, double-blinded study<sup>32</sup> in patients with ulcerative rectocolitis and active rectal inflammation. Still, an experimental study<sup>15</sup> performed with irradiated rats showed a satisfactory result of the use of topical mesalazine on the

histopathological analysis. The combination of oral and topical therapies with these compounds could lead to a satisfactory response in the treatment of radiation-induced proctopathy.<sup>8</sup>

Wu et al.<sup>31</sup> treated patients with rectal ulceration due to radiation-induced proctopathy who did not respond to other clinical treatments with a suppository containing 0.5 g of mesalazine, twice daily, for 6 months, with improvement of the symptoms of bleeding, tenesmus, evacuation frequency, and rectal pain. With this study, the authors<sup>31</sup> showed that the mesalazine suppository can be a viable option in the treatment of refractory cases of acute radiation proctitis (ARP), with the need for further studies.

Seo et al.<sup>28</sup> (2011) performed a retrospective study with the objective of evaluating the effectiveness of the oral and topical combination of 5-ASA for the treatment of mild and moderate colitis. A total of 23 patients were evaluated before and after 4 weeks of treatment with the combined therapy (3 g of oral mesalazine and 1 g of topical mesalazine). Of the most prevalent symptoms, which included bleeding, pain, tenesmus, and evacuation frequency, there was only a significant improvement in anal bleeding.<sup>28</sup>

Sanguineti et al.<sup>33</sup> (2003), in an attempt to carry out preventive measures during the course of radiotherapy, performed a study with patients undergoing radiotherapy treatment for prostate cancer. However, the study was interrupted by the occurrence of seven cases of acute kidney injury by mesalazine, contraindicating its use during radiotherapy.<sup>33</sup>

Due to the anti-inflammatory properties of 5-ASA derivatives in the intestinal mucosa, in 2005, Jahraus et al.<sup>34</sup> performed a study to evaluate the prevention of the effects of radiotherapy on the rectal mucosa with balsalazide. Balsalazide contains the active metabolite 5-ASA and is metabolized by the intestinal microflora, with better tolerance by the patient and fewer side effects. The study<sup>4,35</sup> concluded that balsalazide has a low incidence of side effects, with a statistically significant improvement of all the symptoms of radiation-induced proctopathy. Further studies are needed to confirm its benefit in improving the quality of life of patients undergoing pelvic radiotherapy.

The vast majority of studies<sup>8,35,36</sup> related to compounds derived from 5-ASA are performed for the treatment of inflammatory bowel diseases. A new formulation of mesalazine conjugated to chondroitin sulfate has recently been patched, and appears to induce a delayed response with greater effectiveness of the drug, enabling the administration of lower doses and, consequently, with fewer side effects.<sup>37,38</sup>

## Formalin

When applied to the mucosa, formalin causes chemical cauterization and thereby stops bleeding, sealing telangiectasias and ulcers.<sup>16,18</sup> Formalin as a treatment for radiation-induced hemorrhage was first used by Brown<sup>39</sup> in 1969, who demonstrated its effectiveness in cystitis. When considered for the treatment of radiation-induced proctopathy, it must be applied selectively to rectal lesions to avoid the formation

of fibrosis.<sup>16</sup> The success rate after a single application of formalin is reported to be between 34% and 100%.<sup>23</sup>

Formalin can be applied with or without sedation, as well as under direct visualization with cotton soaked in a 4% formalin solution, or by instilling a solution containing 4% formalin in the entire distal rectum.<sup>4,17,23</sup> When the application is made under direct visualization, contact from 30 seconds to 3 minutes is recommended (until the mucosa turns white and the bleeding stops).<sup>17,40</sup> In 2007, Lee et al.<sup>23</sup> described satisfactory results with a combined technique that consisted of instillation followed by application under direct visualization of areas with remaining telangiectasias.

In 1995, Biswal et al.<sup>16</sup> published an analysis of 16 cases of radiation-induced grade-III proctopathy in which the application of formalin 4% obtained a complete response in 81% of patients. In 2003, to assess the effectiveness and possible histological effects of the application of 4% formalin, Chau-tems et al.<sup>17</sup> performed a study with 13 patients, who had their symptoms resolved in a maximum of 4 sessions. To assess local toxicity, biopsies of the affected recta were performed before and after the treatment. The authors<sup>17</sup> found multiple recent thrombosis in areas of neovascularization in the early biopsies, and fibrosis of the lamina propria, hyalinized vascular wall, and degeneration of the muscularis mucosa in the long-term (after 12 months). Formalin would then act only on the superficial mucosa, with rapid deterioration of the blood flow and coagulative superficial necrosis.<sup>9</sup> In 2006, it was proposed that the best method of applying formalin would be under direct visualization, in which the compound would be in contact only with the affected mucosa long enough to stop the bleeding, reducing the possibility of side effects.<sup>41</sup>

Tsujinaka et al.<sup>3</sup> performed a retrospective study to define if the best technique for the application of formalin is under direct visualization (without anesthesia) or through instillation of a solution (under sedation). Both in the study and in the review performed by the authors,<sup>3</sup> instillation of the formalin solution showed a higher rate of side effects such as anal and rectal stenosis, anorectal pain, incontinence, colitis, and perforation. However, both techniques were effective in controlling the bleeding.<sup>3</sup> Ma et al.<sup>9</sup> (2015) modified the irrigation procedure, making it better tolerated and safer. They suggested that the procedure should be performed under epidural anesthesia, with protection of the anal sphincter and of the normal proximal colonic mucosa. To achieve that, they recommend total anal dilation through proper patient positioning and the placement of a Foley catheter in the proximal sigmoid colon to prevent formalin reflux, directing the flow to the affected area with controlled irrigation volume and adequate time.<sup>9</sup>

The most common side effect is pain, which is usually self-limited and occurs in up to 33% of the patients. Other common effects are diarrhea, abdominal pain, and tenesmus.<sup>13,42</sup> In a study by Raman<sup>13</sup> (2007), 23.5% of the patients developed diarrhea, 8.8%, abdominal pain, 8.8%, tenesmus, and 2.9%, fever and vomiting. Another possible side effect described in the literature<sup>43</sup> is imalignant transformation secondary to the use of formalin. Stern and Steinhagen<sup>43</sup> described the occurrence

of two cases of anorectal cancer in a study published in 2007. It is difficult to prove a clear association between formalin and anorectal neoplasia, since there is an already increased risk of malignancies after radiotherapy itself.<sup>43</sup>

In an attempt to reduce the side effects of formalin 4%, Raman<sup>13</sup> used enema with a lower concentration of formalin (2%); the result was still satisfactory, and patients had fewer side effects. Korkut et al.<sup>15</sup> (2006) conducted an experimental study in rats that showed that formalin causes an inflammatory effect and should be avoided.

The application of formalin is a relative safe, effective and economically viable option for the treatment of radiation-induced proctopathy; both for the first line of treatment and for refractory cases.<sup>18</sup> It should be considered preferably in severe and refractory cases.<sup>19</sup> However, it should not be used as a means of prevention due to its toxic effects on the mucosa<sup>15</sup> (► **Table 3**).

### Elastic Bandage

The management of rectal bleeding in patients with radiation-induced proctopathy and hemorrhoidal disease is a challenge.<sup>42</sup> In 2020 De Robles MS and Young CJ mention the treatment of hemorrhoidal bleeding in patients with radiation-induced proctopathy. It has been observed<sup>42</sup> that half of the patients with radiation-induced proctopathy present internal hemorrhoids concomitantly, so it is necessary to treat the hemorrhoidal disease regardless of the technique used in the treatment of radiation-induced proctopathy. Often, the refractory nature of anal bleeding is due to hemorrhoidal disease, not to the radiation. The prolapse of the irradiated mucosa seems to exacerbate the bleeding.<sup>42</sup>

Elastic bandage (EB) is the technique of choice for internal second-degree hemorrhoids.<sup>44</sup> It acts by causing ischemia of the strangulated tissue, which results in a healing process.<sup>44</sup> De Robles et al.<sup>42</sup> performed a retrospective study that evaluated 52 patients between September 1999 and October 2017. Patients with bleeding of grades II and III and internal hemorrhoids were submitted to EB before the application of 4% formalin or argon plasma coagulation for the treatment of ARP. In total, 27 (52%) patients had internal hemorrhoids, 56% of whom underwent EB. The authors<sup>42</sup> suggest that further studies should be performed to standardize the treatment of symptomatic hemorrhoidal disease in patients with radiation-induced proctopathy.

Despite being a simple procedure, EB should be performed with caution in patients with irradiated pelvis. In 2018, Pita et al.<sup>45</sup> described the report of a patient who evolved with ulceration and a rectourethral fistula after EB was performed. Thus, the procedure must be properly indicated, and the patient, followed up after it.

### Hyperbaric Oxygen Therapy

Hyperbaric oxygen therapy has been used to treat late complications of radiotherapy.<sup>46</sup> It started as a therapeutic modality in the treatment of chronic wounds of various etiologies.<sup>6</sup> The technique consists of the intermittent inhalation of 100% oxygen while the patient is in a chamber with a pressure higher than the atmospheric pressure.<sup>4,6</sup> Under these conditions, the

**Table 3** Studies and their results related to the use of formalin

FORMALIN				
Author	Year	N	Response	Complications
Seow-Choen et al. <sup>40</sup>	1993	8	100%	None
Biswal et al. <sup>16</sup>	1995	16	81%	None
Mathai and Choen <sup>49</sup>	1995	29	76%	None
Saclarides et al. <sup>4</sup>	1996	16	75%	Pain, tenesmus, reduced fecal capacity
Roche et al. <sup>50</sup>	1996	6	100%	None
Counter et al. <sup>51</sup>	1999	11	100%	Fecal incontinence, stenosis, rectal ulcer
Ismail and Qureshi <sup>52</sup>	2002	20	90%	None
Luna-Perez and Rodrigues-Ramirez <sup>53</sup>	2002	20	90%	necrosis, anal pain, rectovaginal fistule
Parikh et al. <sup>54</sup>	2003	36	88%	None
Ysujinaka et al. <sup>55</sup>	2005	21	88%	Anal stenosis, anal pain, fecal incontinence, anal fissure, rectal ulcer, colitis, abdominal pain, perforation
Parades et al. <sup>56</sup>	2005	33	70%	Stenosis
Cullen et al. <sup>41</sup>	2006	20	65%	None
Ma et al. <sup>9</sup>	2015	24	79%	None
Stern and Steinhagen <sup>43</sup>	2007	49	78%	Fecal urgency
Lee et al. <sup>23</sup>	2007	5	100%	None
Eriksen et al. <sup>57</sup>	2013	11	100%	Anal pain
Pironi et al. <sup>58</sup>	2013	15	87%	None
Dziki et al. <sup>59</sup>	2015	20	100%	None
Sharma et al. <sup>60</sup>	2019	28	62%	None

lungs can capture more oxygen than at usual pressures.<sup>2</sup> The sessions normally last from 60 to 120 minutes, are held twice a day, and their number varies from 30 to 60, depending on the response of the patient.<sup>47</sup> The radiation injury alters the physiology and anatomy of normal tissue, leading to hypocellularity, hypovascularity, and hypoxia due to occlusive endarteritis.<sup>48</sup> The result of the administration of HO is neovascularization due to the increased pO<sub>2</sub> of the damaged tissue, promoting mucosal healing.<sup>4</sup>

Girnius et al.<sup>46</sup> published their experience through a retrospective study that evaluated nine patients with radiation-induced proctopathy treated with HO. All patients had a satisfactory response after an average of 58 sessions, with 2 of them having a partial response, with intermittent bleeding. Most patients had good tolerance to HO sessions, with only two adverse events; one patient had a seizure, and another one had an episode of anxiety.

Clarke et al.<sup>27</sup> performed a randomized, controlled, double-blinded study to assess the effectiveness of HO for the treatment of refractory radiation-induced proctopathy. They evaluated 120 patients, who were divided into 2 groups submitted either to HO at 2 atm or air at 1.1 atm. The HO group showed better improvement in clinical symptoms and mucosal healing.<sup>27</sup>

In a systematic review, Hoggan and Cameron<sup>47</sup> (2014) assessed the safety and effectiveness of HO. Serious and potentially-fatal complications were rare, while the most

common ones were self-limited. Of 29 studies reviewed, which involved 700 patients, fatal side effects associated with HO were not reported, and only 1.7% of the patients had manifestations of the central nervous system.<sup>47</sup> The most common side effects were ear barotrauma and visual changes induced by oxygen, which are usually transient and resolve without the need for intervention.<sup>5</sup> Unfortunately, HO therapy is still little available, with a high cost (► **Table 4**).<sup>2</sup>

## Radiofrequency Ablation

Radiofrequency ablation (RA) is another endoscopic therapeutic modality that enables the treatment of the superficial mucosa and prevents lesions to the deeper layers, minimizing the risks of ulceration and stenosis.<sup>61</sup> Endoscopic therapy for the treatment of radiation-induced proctopathy is currently the preferred modality.<sup>62</sup> However, according to Zhou et al.,<sup>62</sup> these methods can increase the risk of developing rectal pain,

**Table 4** Studies and their results related to the use of hyperbaric oxygen therapy

HYPERBARIC OXYGEN THERAPY				
Author	Year	N	Response	Complications
Girnius et al. <sup>46</sup>	2006	7	100%	Seizure, anxiety
Clarke et al. <sup>27</sup>	2008	120	88.90%	None



**Table 5** Studies and their results related to the use of ablation by radiofrequency

ABLATION BY RADIOFREQUENCY				
Author	Year	N	Response	Complications
Zhou et al. <sup>62</sup>	2009	3	100%	None
Dray et al. <sup>25</sup>	2014	17	94%	None
Markos et al. <sup>64</sup>	2017	15	80%	None
McCarty et al. <sup>63</sup>	2019	71	100%	None

diarrhea, tenesmus, ulcer, fistula or rectal stenosis, depending on how deep the energy source reaches the rectal wall.

Since RA is an effective therapeutic option in hemorrhagic lesions of the esophagus, its use in diseases of the rectum has also been hypothesized,<sup>62</sup> and was first used in 2009.<sup>63</sup> The procedure is safe as long as the applied energy acts strictly on the superficial mucosa.<sup>62</sup> It is a contact-coagulation technique with homogeneous energy distribution and penetration.<sup>64</sup> It is still a new procedure, with little data in the literature.<sup>26,64</sup> Most studies<sup>64</sup> are concerned with the treatment of patients with diseases refractory to other methods of treatment.

The procedure is performed through a single catheter that passes through the working channel of the flexible endoscope: 300 W of energy are applied per session, and 10 J per cubic centimeter are supplied to the bleeding areas.<sup>62</sup> Usually, 2 sessions lasting an average of 30 minutes are required to resolve the bleeding.<sup>25</sup> Radiofrequency ablation has several benefits in the treatment of radiation-induced proctopathy, such as low risk of ischemia and the possibility for wider cauterization. However, the equipment is quite expensive (► **Table 5**).<sup>25</sup>

## Argon Plasma Coagulation

Argon plasma coagulation (APC) was developed by ERBE Medical in Germany,<sup>65</sup> and its use was first described in 1986.<sup>66</sup> Taking into account that argon has the greatest effectiveness in the treatment of telangiectasias, APC could be effective for the treatment of radiation-induced proctopathy.<sup>67</sup> It is still successfully used to treat lesions of the

**Table 6** Benefits and limitations of argon plasma coagulation

BENEFITS	LIMITATIONS
<ul style="list-style-type: none"> <li>- Mobile unit, compact, easy maintenance</li> <li>- Can handle larger, contactless areas</li> <li>- Quick method – reaches surface layers</li> </ul>	<ul style="list-style-type: none"> <li>- Requires multiple applications</li> <li>- Need for endoscopic follow-up</li> <li>- Risk of colonic explosion</li> <li>- Risk of perforation</li> <li>- Requires experience for use</li> <li>- Distension and pain after application</li> <li>- Cost per application</li> </ul>

Note: Extracted from Rosenfeld and Enns.<sup>65</sup>

gastrointestinal tract,<sup>68</sup> and consists of a non-contact coagulation method<sup>69</sup> that uses argon gas to transmit a high-frequency current that results in homogeneous and superficial necrosis, reaching between 0.5 mm and 3 mm in depth.<sup>68,70</sup> Deeper coagulation is possible with greater applied power, continuous treatment, or contact between the monofilament and the mucosa (► **Table 6**).<sup>65</sup>

The purpose of using APC is the ablation of all visible telangiectasias during a single endoscopic session, and, if necessary, it can be applied at the level of the toothed line.<sup>71</sup>

In addition to its important role in the treatment of anal bleeding, APC has also been shown to promote a significant improvement in symptoms associated with anorectal dysfunction, such as urgency, fecal incontinence, and changes in evacuation frequency.<sup>72</sup> It has also been shown to be effective for the treatment of actinic colitis, and it can even be used in the sigmoid colon, with a low risk of complications.<sup>73,74</sup> Particular attention should be paid to those patients with symptomatic radio. Radiation-induced proctopathy who are using brachytherapy – it seems to increase the chance of exacerbating the disease after APC.<sup>75</sup> Radiation-induced proctopathy is characterized by the progressive formation of lesions resulting from neovascularization, so more than one session of APC may be necessary in case of recurrent bleeding.<sup>76</sup> The greater the severity of the radiation-induced proctopathy, the greater the number of APC sessions required.<sup>77</sup>

Some side effects and complications are described in the literature. A relatively common complication of this method is abdominal distension due to argon insufflation.<sup>68,69</sup> It is worth mentioning that cases of colonic explosion with the use of APC have already been described due to inappropriate colon preparation.<sup>19,78</sup> Moreover, as with any method that uses coagulation, perforation may occur.<sup>11</sup> The parameters used, such as the wattage, have an influence on the likelihood of developing side effects.<sup>79</sup> Another possible complication after APC is bacteremia.<sup>80</sup> In 2011, Lenz et al.<sup>80</sup> found a rate of bacteremia of 7% in a small sample of patients undergoing APC.

It is important to highlight that APC can result in ischemia of the treated region and, consequently, worsen the vascular condition already altered by radiation, leading to the formation of chronic ulcers and causing greater damage to the patient.<sup>81,82</sup> Thus, the ideal indication for the use of APC would be in mild to moderate cases of the disease.<sup>19,82</sup> Another factor that influences the formation of ulcers and the risk of complications are the parameters: the flow and power used.<sup>83</sup>

The use of APC is inexpensive (in comparison to other laser therapies), it is easy to apply, and effective for the treatment of patients with radiation-induced proctopathy and bleeding.<sup>84–87</sup> There is no additional benefit from the use of associated oral sucralfate.<sup>88</sup> The use of anticoagulants and aspirin seems to be a risk factor for rebleeding.<sup>19,86</sup> The use of nonsteroidal anti-inflammatory drugs (NSAIDs) should also be discouraged by the increased risk of forming rectal ulcers when associated with APC.<sup>89</sup>

Due to the low number of well-controlled, double-blinded, randomized studies,<sup>69,90</sup> it is not possible to access the real effectiveness of using APC in radiation-induced

**Table 7** Studies and their results related to the use of argon plasma coagulation

ARGON PLASMA COAGULATION				
Author	Year	N	Response	Complications
Buchi and Dixon <sup>85</sup>	1987	3	100%	Abdominal distension
Taylor et al. <sup>76</sup>	1993	14	100%	None
Silva et al. <sup>74</sup>	1999	28	100%	None
Fantini et al. <sup>87</sup>	1999	7	100%	None
Tam et al. <sup>72</sup>	2000	15	100%	Anal stenosis
Kaassis et al. <sup>91</sup>	2000	16	100%	None
Venkatesh and Ramanujam <sup>94</sup>	2001	40	98%	Urinaryretention, fever
Tijandra et al. <sup>97</sup>	2001	12	83%	None
Smith et al. <sup>75</sup>	2001	7	100%	None
Sebastian et al. <sup>70</sup>	2004	25	81%	Anal fistula, anal stenosis
Sebastian et al. <sup>98</sup>	2004	25	81%	None
Ben Soussan et al. <sup>78</sup>	2003	27	92%	Explosion, vagal symptoms, anal pain
Dees et al. <sup>86</sup>	2006	50	98%	None
Karamanolis et al. <sup>19</sup>	2009	56	90%	None
Tormo et al. <sup>84</sup>	2009	22	100%	None
Swan et al. <sup>71</sup>	2010	50	96%	Anal pain
Takemoto et al. <sup>21</sup>	2012	12	42%	None
Hortelano et al. <sup>11</sup>	2014	30	77%	Colonic perforation, ulcer, stenosis, mucorrea
Slow et al. <sup>99</sup>	2016	91	79%	Anal pain, bleeding, mucorrea, anal stenosis
Sudha e Kadambari <sup>95</sup>	2017	7	100%	Mucorrea
Sultania et al. <sup>77</sup>	2019	70	86%	Rectalulcer, mucorrea, anal pain
Megias et al. <sup>100</sup>	2019	82	100%	Rebleeding, anal pain

**Table 8** Types of laser therapy that can be use for the treatment of proctopathy

Neodymium-doped yttrium aluminum garnet (Nd:YAG) laser	Ideal for deep tissues after being absorbed by tissue proteins; Rate of complications of 5% to 15% including stenosis, necrosis, and fistulas; High cost and difficult application; Direct and precise application over telangiectasis.
Potassium titanyl phosphate (KTP) laser	It has a more superficial action than the Nd:YAG laser; Benefit in the treatment of superficial vascular lesions.
Argon plasma	Like the KTP laser, it has a more superficial action, and has the same indications with slightly higher effectiveness.

Note: Extracted from Tabaja and Sidani, 2018.<sup>61</sup>

proctopathy. Even so, some studies<sup>11,87,91,92</sup> suggest that APC is the first line of treatment for radiation-induced proctopathy; with it, remission rates of 90%<sup>19,93</sup> can be achieved, and its use is simple when compared with other ablation techniques.<sup>94</sup> The APC treatment should also be considered in cases of bleeding refractory to other therapeutic modalities (► **Table 7**).<sup>71,72,95</sup>

## Laser Therapy

Laser therapy is an effective endoscopic option in the treatment of chronic radiation-induced proctopathy. The three

most used options are neodymium-doped yttrium aluminum garnet (Nd:YAG) laser, potassium titanyl phosphate (KTP) laser, and argon laser (► **Table 8**).

## Other Therapies

Corticosteroids exert an anti-inflammatory effect by stabilizing the mast cell membrane and inhibiting the release of histamine, among other actions.<sup>21</sup> They are effective, according to Takemoto et al.<sup>21</sup> (2012), to relieve acute symptoms, but there is no evidence to support their use in chronic cases. Corticosteroids must be used with caution and monitoring

**Table 9** Studies and their results related to the use of other therapies options

OTHER THERAPIES					
Author	Method	Year	N	Response	Complications
Takemoto et al. <sup>21</sup>	Corticosteroid enema	2012	29	62%	None
Ramakrishnaiah et al. <sup>102</sup>	Sucralfate	2012	51	74.50%	None
Wu et al. <sup>31</sup>	Mesalazine suppository	2018	10	5%	None

due to the large amount of possible side effects with their prolonged use.

A randomized controlled study conducted in 2012 by Sahakitrungruang et al.<sup>96</sup> proposed the use of colonic irrigation with clean water and the use of oral antibiotics (ciprofloxacin and metronidazole) for the treatment of radiation-induced proctopathy. The authors<sup>96</sup> compared this treatment proposal with the application of 4% formalin. Both treatments were effective, with greater satisfaction reported by the patients in the irrigation and oral antibiotic group.<sup>96</sup> Further studies are needed to confirm the validity of this therapeutic modality.

A promising therapy modality is the use of mesenchymal cells.<sup>38</sup> Due to their capacity for remodeling, angiogenesis, and inflammatory modulation, they could be used in the treatment of patients with refractory symptoms (→ **Table 9**).<sup>61</sup>

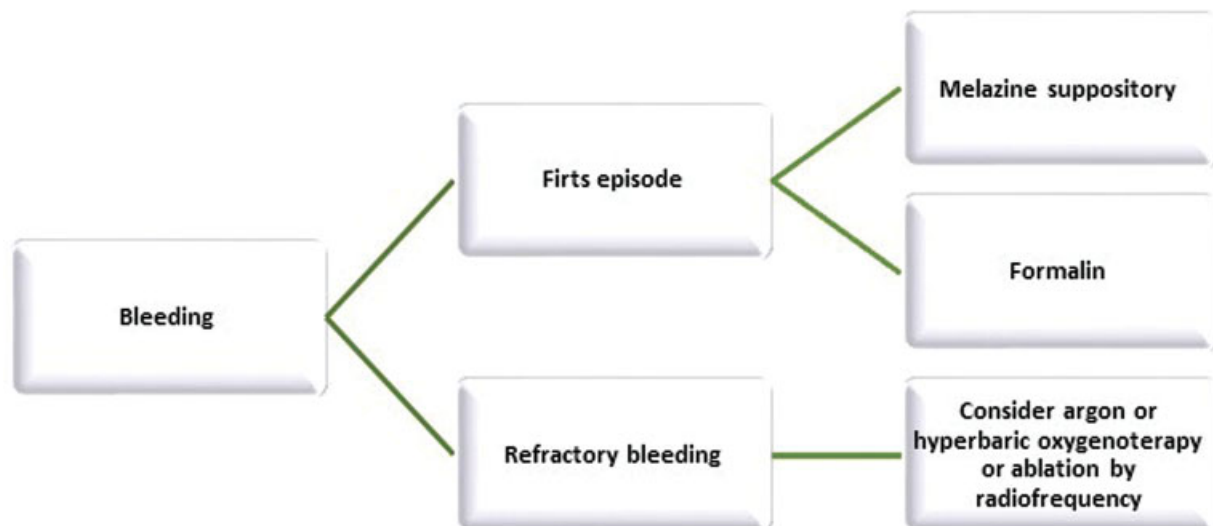
### Surgery

Radiation-induced proctopathy surgery can be performed either to remove the affected segment (proctectomy), or for diversion of the intestinal transit (creation of stoma), or even for repair in case of fistulas. Surgery should be considered as the last resort for patients with radiation-induced proctopathy; it should be reserved for cases of stenosis, refractory bleeding, perforation, and fistulas unresponsive to the clinical and endoscopic treatments.<sup>2,61</sup> When well indicated, it must offer an effective solution.<sup>61</sup>

The surgeon must be cautious and keep in mind that radiation results in chronic inflammatory changes, fibrosis, and impaired wound healing, which can increase the risk of iatrogenic injuries during the surgical procedure.<sup>6</sup> Thus, according to Ali and Hu<sup>6</sup> (2020), diversion of the intestinal transit is the most common and safest surgery for symptom control. The patients with severe disease and with sphincter involvement are the ones who benefit the most from a stoma.<sup>61</sup> Special attention must be paid in the case of fistulas. Flap mobilization is a simple procedure, but with a low success rate because of the low vascularization due to irradiation of the tissue.<sup>61</sup> Regardless of the surgical treatment chosen, rate of complications among irradiated patients can vary from 30% to 65%.<sup>101</sup>

### Discussion

Radiation-induced proctopathy is a very relevant topic that is presently increasingly prevalent. However, the vast majority of the studies face severe limitations. Most studies on colitis and rectitis focus on inflammatory bowel disease, not on radiation-induced disease. Most studies that have radiation-induced proctopathy as their main topic, aim to analyze refractory cases. There is a lack of robust studies on radiation-induced proctopathy with a significant number of patients and standardized therapies to be compared. There is also a lack of

**Fig. 3** Treatment algorithm proposed by the authors.

double-blinded, randomized controlled studies that can determine a definitive standard treatment algorithm.

Based on the evaluated studies and the clinical practice, the initial treatment should be performed with mesalazine suppository, to which the patients normally have a good response, without major side effects. The response is usually satisfactory, and the treatment can be performed whenever there is rebleeding, without repercussions. For more severe cases, formalin, which is widely available and has a low cost, can be added to the therapy to cauterize the mucosa. Refractory and difficult-to-control cases can be addressed with higher-cost but highly-effective therapies such as APC RA, and HO therapy. When it comes to the reality of the public health system in Brazil, resources are limited, and less expensive therapies, such as mesalazine and formalin, are more available.

After the present review, an algorithm to manage cases of radiation-induced proctopathy was suggested for further study and validation (→Fig. 3).

## Conclusion

Despite the prevalence of radiation-induced proctopathy, there is no definitive standardized treatment strategy so far. A first approach can be tried with local agents such as mesalazine and formalin. For refractory cases, control can usually be achieved with APC, HO, and RA therapies.

## References

- MS / INCA / Estimativa de Câncer no Brasil. 2020
- Vanneste BGL, Van De Voorde L, de Ridder RJ, Van Limbergen EJ, Lambin P, van Lin EN. Chronic radiation proctitis: tricks to prevent and treat. *Int J Colorectal Dis* 2015;30(10):1293–1303
- Tsujinaka S, Baig MK, Gornev R, et al. Formalin instillation for hemorrhagic radiation proctitis. *Surg Innov* 2005;12(02):123–128
- Saclarides TJ, King DG, Franklin JL, Doolas A. Formalin Instillation for Refractory Hemorrhagic Proctitis Report of 16 Patients. *Dis Colon Rectum* 1996;39(02):196–199
- Grodsky MB, Sidani SM. Radiation proctopathy. *Clin Colon Rectal Surg* 2015;28(02):103–111
- Ali F, Hu KY. Evaluation and Management of Chronic Radiation Proctitis. *Dis Colon Rectum* 2020;63(03):285–287
- Leiper K, Morris AIL LKMA. Treatment of radiation proctitis. *Clin Oncol (R Coll Radiol)* 2007;19(09):724–729
- Wu XR, Liu XL, Katz S, Shen B. Pathogenesis, diagnosis, and management of ulcerative proctitis, chronic radiation proctopathy, and diversion proctitis. *Inflamm Bowel Dis* 2015;21(03):703–715
- Ma TH, Yuan ZX, Zhong QH, et al. Formalin irrigation for hemorrhagic chronic radiation proctitis. *World J Gastroenterol* 2015;21(12):3593–3598
- Rustagi T, Mashimo H. Endoscopic management of chronic radiation proctitis. *World J Gastroenterol* 2011;17(41):4554–4562
- Hortelano E, Gómez-Iturriga A, Ortiz-de-Zárate R, et al. Is argon plasma coagulation an effective and safe treatment option for patients with chronic radiation proctitis after high doses of radiotherapy? *Rev Esp Enferm Dig* 2014;106(03):165–170
- Mendenhall WM, McKibben BT, Hoppe BS, Nichols RC, Henderson RH, Mendenhall NP. Management of radiation proctitis. *Am J Clin Oncol* 2014;37(05):517–523
- Raman RR. Two percent formalin retention enemas for hemorrhagic radiation proctitis: a preliminary report. *Dis Colon Rectum* 2007;50(07):1032–1039
- Price JG, Stone NN, Stock RG. Predictive factors and management of rectal bleeding side effects following prostate cancer brachytherapy. *Int J Radiat Oncol Biol Phys* 2013;86(05):842–847. Doi: 10.1016/j.ijrobp.2013.04.033
- Korkut C, Asoglu O, Aksoy M, et al. Histopathological comparison of topical therapy modalities for acute radiation proctitis in an experimental rat model. *World J Gastroenterol* 2006;12(30):4879–4883
- Biswal BM, Lal P, Rath GK, Shukla NK, Mohanti BK, Deo S. Intrarectal formalin application, an effective treatment for grade III haemorrhagic radiation proctitis. *Radiother Oncol* 1995;35(03):212–215
- Chautems RC, Delgadillo X, Rubbia-Brandt L, Deleaval JP, Marti MC, Roche B. Formaldehyde application for haemorrhagic radiation-induced proctitis: a clinical and histological study. *Colorectal Dis* 2003;5(01):24–28
- Sharma B, Gupta M, Sharma R, et al. Four percent formalin application for the management of radiation proctitis in carcinoma cervix patients: An effective, safe, and economical practice. *J Cancer Res Ther* 2019;15(01):92–95
- Karamanolis G, Triantafyllou K, Tsiamoulos Z, et al. Argon plasma coagulation has a long-lasting therapeutic effect in patients with chronic radiation proctitis. *Endoscopy* 2009;41(06):529–531
- Denton AS, Andreyev HJN, Forbes A, Maher EJ. Systematic review for non-surgical interventions for the management of late radiation proctitis. *Br J Cancer* 2002;87(02):134–143
- Takemoto S, Shibamoto Y, Ayakawa S, Nagai A, Hayashi A, Ogino H, Baba F, Yanagi T, Sugie C, Kataoka H, Mimura M. Treatment and prognosis of patients with late rectal bleeding after intensity-modulated radiation therapy for prostate cancer. *Radiat Oncol* 2012 Jun 12(07):87. Doi: 10.1186/1748-717X-7-87. PMID: 22691293; PMCID: PMC3403958
- Stojcev Z, Krokowicz Ł, Krokowicz P, et al. Early treatment and prevention of the radiation proctitis–composite enemas containing sodium butyrate. *Int J Colorectal Dis* 2013;28(12):1731–1732
- Lee SI, Park YA, Sohn SK. Formalin application for the treatment of radiation-induced hemorrhagic proctitis. *Yonsei Med J* 2007;48(01):97–100
- Sarin A, Safar B. Management of radiation proctitis. *Gastroenterol Clin North Am* 2013;42(04):913–925. Doi: 10.1016/j.gtc.2013.08.004
- Dray X, Battaglia G, Wengrower D, et al. Radiofrequency ablation for the treatment of radiation proctitis. *Endoscopy* 2014;46(11):970–976
- Indaram AVK, Visvalingam V, Locke M, Bank S. Mucosal cytokine production in radiation-induced proctosigmoiditis compared with inflammatory bowel disease. *Am J Gastroenterol* 2000;95(05):1221–1225
- Clarke RE, Tenorio LMC, Hussey JR, et al. Hyperbaric oxygen treatment of chronic refractory radiation proctitis: a randomized and controlled double-blind crossover trial with long-term follow-up. *Int J Radiat Oncol Biol Phys* 2008;72(01):134–143
- Seo EH, Kim TO, Kim TG, et al. The efficacy of the combination therapy with oral and topical mesalazine for patients with the first episode of radiation proctitis. *Dig Dis Sci* 2011;56(09):2672–2677
- Ito H, Iida M, Matsumoto T, et al. Direct comparison of two different mesalamine formulations for the induction of remission in patients with ulcerative colitis: a double-blind, randomized study. *Inflamm Bowel Dis* 2010;16(09):1567–1574
- Baum CA, Biddle WL, Miner PB Jr. Failure of 5-aminosalicylic acid enemas to improve chronic radiation proctitis. *Dig Dis Sci* 1989;34(05):758–760
- Wu C, Guan L, Yao L, Huang J. Mesalazine suppository for the treatment of refractory ulcerative chronic radiation proctitis. *Exp Ther Med* 2018;16(03):2319–2324

- 32 Watanabe M, Nishino H, Sameshima Y, Ota A, Nakamura S, Hibi T. Alimentary Pharmacology and Therapeutics Randomised clinical trial: evaluation of the efficacy of mesalazine (mesalamine) suppositories in patients with ulcerative colitis and active rectal inflammation – a placebo-controlled study. *2013*;264–273
- 33 Sanguineti G, Franzone P, Marcenaro M, Foppiano F, Vitale V. Sucralfate versus mesalazine versus hydrocortisone in the prevention of acute radiation proctitis during conformal radiotherapy for prostate carcinoma. A randomized study. *Strahlenther Onkol* 2003;179(07):464–470
- 34 Jahraus CD, Bettenhausen D, Malik U, Sellitti M, St Clair WH, Lair WIHSTC. Prevention of acute radiation-induced proctosigmoiditis by balsalazide: a randomized, double-blind, placebo controlled trial in prostate cancer patients. *Int J Radiat Oncol Biol Phys* 2005 Dec 1;63(05):1483–7. Doi: 10.1016/j.ijrobp.2005.04.032. Epub 2005 Aug 15. PMID: 16099600
- 35 Kruis W, Neshta V, Pesegova M, et al. Budesonide Suppositories Are Effective and Safe for Treating Acute Ulcerative Proctitis. *Clin Gastroenterol Hepatol* 2019;17(01):98–106.e4. Doi: 10.1016/j.cgh.2018.04.027 [Internet]
- 36 Sandborn WJ, Bosworth B, Zakko S, et al. Budesonide foam induces remission in patients with mild to moderate ulcerative proctitis and ulcerative proctosigmoiditis. *Gastroenterology* 2015;148(04):740–750.e2. Doi: 10.1053/j.gastro.2015.01.037 [Internet]
- 37 Nunes VRT. Avaliação da mesalazina incorporada a polímero biodegradável no tratamento da retite actínica em ratos por meio de modelo alternativo de irradiação gama. *J Coloproct* 2018
- 38 Bansal N, et al. Exploring the management of radiation proctitis in current clinical practice. *Journal of clinical and diagnostic research: JCDR* 2016;10(06):XE01
- 39 Brown RB. A method of management of inoperable carcinoma of the bladder. *Med J Aust* 1969;1(01):23–24
- 40 Seow-Choen F, Goh HS, Eu KW, Ho YH, Tay SK. A simple and effective treatment for hemorrhagic radiation proctitis using formalin. *Dis Colon Rectum* 1993;36(02):135–138
- 41 Cullen SN, Frenz M, Mee A. Treatment of haemorrhagic radiation-induced proctopathy using small volume topical formalin instillation. *Aliment Pharmacol Ther* 2006;23(11):1575–1579
- 42 De Robles MS, Young CJ. Rubber Band Ligation of Hemorrhoids is often a Necessary Complement in the Management of Hemorrhagic Radiation Proctitis. *Scand J Surg* 2020 Jun;109(2):108–114. Doi: 10.1177/1457496918822619. Epub 2019 Jan 11. PMID: 30632450
- 43 Stern DR, Steinhagen RM. Anorectal cancer following topical formalin application for haemorrhagic radiation proctitis. *Colorectal Dis* 2007;9(03):275–278
- 44 Ng KS, Holzgang M, Young C. Still a Case of “No Pain, No Gain”? An Updated and Critical Review of the Pathogenesis, Diagnosis, and Management Options for Hemorrhoids in 2020. *Ann Coloproctol* 2020;36(03):133–147
- 45 Pita I, Bastos P, Dinis-Ribeiro M. Pelvic Catastrophe after Elastic Band Ligation in an Irradiated Rectum. *GE Port J Gastroenterol* 2018;25(01):42–46
- 46 Girnus S, Cersonsky N, Gesell L, Cico S, Barrett W. Treatment of refractory radiation-induced hemorrhagic proctitis with hyperbaric oxygen therapy. *Am J Clin Oncol* 2006;29(06):588–592
- 47 Hoggan BL, Cameron AL. Systematic review of hyperbaric oxygen therapy for the treatment of non-neurological soft tissue radiation-related injuries. *Support Care Cancer* 2014;22(06):1715–1726
- 48 Bhutani S, Vishwanath G. Hyperbaric oxygen and wound healing. *Indian J Plast Surg* 2012;45(02):316–324
- 49 Mathai V, Seow-Choen F. Endoluminal formalin therapy for hemorrhagic radiation proctitis. *British Journal of Surgery* 1995;82(02):190. <https://doi.org/10.1002/bjs.1800820216>
- 50 Roche B, Chautems R, Marti M. Application of Formaldehyde for Treatment of Hemorrhagic Radiation-Induced Proctitis. *World J Surg* 1996;20:1092–1095. <https://doi.org/10.1007/s002689900166>
- 51 Counter SF, Froese DP, Hart MJ. Prospective evaluation of formalin therapy for radiation proctitis. *The American Journal of Surgery* 1999;177(05):396–398. ISSN 0002-9610. [https://doi.org/10.1016/S0002-9610\(99\)00072-0](https://doi.org/10.1016/S0002-9610(99)00072-0)
- 52 Ismail MA, Qureshi MA. Formalin dab for haemorrhagic radiation proctitis. *Annals of the Royal College of Surgeons of England* 2002;84(04):263
- 53 Luna-Pérez P, Rodríguez-Ramírez SE. Formalin instillation for refractory radiation-induced hemorrhagic proctitis. *J Surg Oncol* 2002 May;80(01):41–4. Doi: 10.1002/jso.10095. PMID: 11967906
- 54 Parikh S, Hughes C, Salvati EP, Eisenstat T, Oliver G, Chinn B, Notaro J. Treatment of hemorrhagic radiation proctitis with 4 percent formalin. *Dis Colon Rectum* 2003 May;46(05):596–600. Doi: 10.1007/s10350-004-6614-1. PMID: 12792434
- 55 Tsujinaka S, Baig MK, Gornev R, De la Garza C, Hwang JK, Sands D, Wexner SD. Formalin instillation for hemorrhagic radiation proctitis. *Surgical innovation* 2005;12(02):123–128
- 56 de Parades V, et al. Formalin application in the treatment of chronic radiation-induced hemorrhagic proctitis – an effective but not risk-free procedure: a prospective study of 33 patients. *Diseases of the Colon & Rectum* 2005;48(08):1535–1541
- 57 Eriksen PL, Tougaard RS, Tøttrup A. Clinical and proctoscopic evaluation of topical formalin application in the treatment of chronic radiation proctitis. *Scandinavian Journal of Surgery* 2013;102(02):96–100
- 58 Pironi D, et al. Chronic radiation-induced proctitis: the 4% formalin application as non-surgical treatment. *International Journal of Colorectal Disease* 2013;28(02):261–266
- 59 Dzikli Ł, et al. Formalin therapy for hemorrhagic radiation proctitis. *Pharmacological Reports* 2015;67(05):896–900
- 60 Sharma B, et al. Four percent formalin application for the management of radiation proctitis in carcinoma cervix patients: An effective, safe, and economical practice. *Journal of Cancer Research and Therapeutics* 2019;15(01):92
- 61 Tabaja L, Sidani SM. Management of Radiation Proctitis. *Dig Dis Sci* 2018;63(09):2180–2188. Doi: 10.1007/s10620-018-5163-8 [Internet]
- 62 Zhou C, Adler DC, Becker L, et al. Effective treatment of chronic radiation proctitis using radiofrequency ablation. *Therap Adv Gastroenterol* 2009;2(03):149–156
- 63 McCarty TR, Garg R, Rustagi T. Efficacy and safety of radiofrequency ablation for treatment of chronic radiation proctitis: A systematic review and meta-analysis. *J Gastroenterol Hepatol* 2019;34(09):1479–1485
- 64 Markos P, Bilic B, Ivekovic H, Rustemovic N. Radiofrequency ablation for gastric antral vascular ectasia and radiation proctitis. *Indian J Gastroenterol* 2017;36(02):145–148
- 65 Rosenfeld Greg, Enns Robert. Argon photocoagulation in the treatment of gastric antral vascular ectasia and radiation proctitis. *Canadian Journal of Gastroenterology* 2009;23(12):801–804
- 66 Sakai E, Takahashi H, Inamori M, Endo H, Akiyama T, Akimoto K, Mawatari H, Nozaki Y, Fujita K, Yoneda M, Goto A, Abe Y, Kobayashi N, Kubota K, Ueno N, Nakajima A. Utility of endoscopic argon plasma coagulation in the treatment of radiation proctitis. *Digestion* 2007;75(04):180. Doi: 10.1159/000106976. Epub 2007 Aug 8. PMID: 17687188
- 67 O'Connor John J. Argon laser treatment of radiation proctitis. *Archives of Surgery* 1989;124(06):749–749
- 68 Taieb S, Rolachon A, Cenni JC, et al. Effective use of argon plasma coagulation in the treatment of severe radiation proctitis. *Dis Colon Rectum* 2001;44(12):1766–1771
- 69 Tjandra JJ, Sengupta S. Argon plasma coagulation is an effective treatment for refractory hemorrhagic radiation proctitis. *Dis Colon Rectum* 2001;44(12):1759–1765, discussion 1771
- 70 Sebastian S, O'Connor H, O'Morain C, Buckley M. Argon plasma coagulation as first-line treatment for chronic radiation proctopathy. *J Gastroenterol Hepatol* 2004;19(10):1169–1173



- 71 Swan MP, Moore GTC, Sievert W, Devonshire DA. Efficacy and safety of single-session argon plasma coagulation in the management of chronic radiation proctitis. *Gastrointest Endosc* 2010;72(01):150–154. Doi: 10.1016/j.gie.2010.01.065
- 72 Tam W, Moore J, Schoeman M. Treatment of Radiation Proctitis with Argon Plasma Coagulation. *Endoscopy* 2000;32(09):667–672
- 73 Lam MCW, Parliament M, Wong CKW. Argon plasma coagulation for the treatment of hemorrhagic radiation colitis. *Case Rep Gastroenterol* 2012;6(02):446–451
- 74 Silva RA, Correia AJ, Dias LM, Viana HL, Viana RL. Argon plasma coagulation therapy for hemorrhagic radiation proctosigmoiditis. *Gastrointest Endosc* 1999;50(02):221–224
- 75 Smith S, Wallner K, Dominitz JA, et al. Argon plasma coagulation for rectal bleeding after prostate brachytherapy. *Int J Radiat Oncol Biol Phys* 2001;51(03):636–642
- 76 Taylor JG, DiSario JA, Buchi KN. Argon laser therapy for hemorrhagic radiation proctitis: long-term results. *Gastrointest Endosc* 1993;39(05):641–644
- 77 Sultania S, Sarkar R, Das K, Dhali GK. Argon plasma coagulation is an effective treatment for chronic radiation proctitis in gynaecological malignancy: an observational study. *Colorectal Dis* 2019;21(04):465–471
- 78 Ben Soussan E, Mathieu N, Roque I, Antonietti M. Bowel explosion with colonic perforation during argon plasma coagulation for hemorrhagic radiation-induced proctitis. *Gastrointest Endosc* 2003;57(03):412–413
- 79 Lam MC, Parliament M, Wong CK. Argon plasma coagulation for the treatment of hemorrhagic radiation colitis. *Case Rep Gastroenterol* 2012;6(02):446–451. Doi: 10.1159/000339462
- 80 Lenz L, Tafarel J, Correia L, et al. The incidence of bacteraemia after argon plasma coagulation in patients with chronic radiation proctocolitis. *Colorectal Dis* 2011;13(07):823–825
- 81 Postgate A, Saunders B, Tjandra J, Vargo J. Argon plasma coagulation in chronic radiation proctitis. *Endoscopy* 2007;39:361–365
- 82 Parejo S, Vázquez-Sequeiros E. Argon gas in the management of radiation proctitis—effective and safe for everyone? *Rev Esp Enferm Dig* 2014;106(03):155–158
- 83 Cunha TR, Colaiacovo W, Oliveira CZ, Almodova EC, Fava G, Guimarães DP. Comparison between two different parameters of argon plasma coagulation in the treatment of chronic radiation proctopathy. *Int J Colorectal Dis* 2016;31(09):1657–1658. Doi: 10.1007/s00384-016-2594-6 [Internet]
- 84 Tormo V, Wikman Jorgensen P, García del Castillo G, Ruiz F, Martínez Egea A. Effectiveness of argon plasma coagulation in the treatment of chronic actinic proc. *Rev Esp Enferm Dig* 2009;101(02):91–93, 94–96
- 85 Buchi KN, Dixon JA. Argon laser treatment of hemorrhagic radiation proctitis. *Gastrointest Endosc* 1987;33(01):27–30. Doi: 10.1016/S0016-5107(87)71481-3 [Internet]
- 86 Dees J, Meijssen MAC, Kuipers EJ. Argon plasma coagulation for radiation proctitis. *Scand J Gastroenterol Suppl* 2006;32(243):175–178
- 87 Fantin AC, Binek J, Suter WR, Meyenberger C. Argon beam coagulation for treatment of symptomatic radiation-induced proctitis. *Gastrointest Endosc* 1999 Apr;49(4 Pt 1):515–8. Doi: 10.1016/S0016-5107(99)70054-4. PMID: 10202070
- 88 Chrusciewska-Kiliszek J, Regula J, Polkowski M, Rupinski M, Kraszewska E, Pachlewski J, Czackowska-Kurek E, Butruk E. Sucralfate or placebo following argon plasma coagulation for chronic radiation proctitis: a randomized double blind trial. *Colorectal Dis* 2013 Jan;15(1):e48–55. Doi: 10.1111/codi.12035. PMID: 23006660
- 89 Koessler T, Servois V, Mariani P, Aubert E, Cacheux W. Rectal ulcer: Due to ketoprofen, argon plasma coagulation and prostatic brachytherapy. *World J Gastroenterol* 2014;20(45):17244–17246
- 90 Hanson B, MacDonald R, Shaikat A. Endoscopic and medical therapy for chronic radiation proctopathy: a systematic review. *Dis Colon Rectum* 2012;55(10):1081–1095
- 91 Kaassis M, Oberti E, Burtin P, Boyer J. Argon plasma coagulation for the treatment of hemorrhagic radiation proctitis. *Endoscopy* 2000;32(09):673–676
- 92 Mello FSFFGBOAT. Eficácia da formalina comparada à coagulação por plasma de argônio no tratamento da retite actínica hemorrágica – Ensaio clínico controlado. 2019
- 93 Postgate A, Saunders B, Tjandra J, Vargo J. Argon plasma coagulation in chronic radiation proctitis. *Endoscopy* 2007;39(04):361–365
- 94 Venkatesh KS, Ramanujam P. Endoscopic therapy for radiation proctitis-induced hemorrhage in patients with prostatic carcinoma using argon plasma coagulator application. *Surg Endosc* 2002;16(04):707–710
- 95 Sudha SP, Kadambari D. Efficacy and safety of argon plasma coagulation in the management of extensive chronic radiation proctitis after pelvic radiotherapy for cervical carcinoma. *Int J Colorectal Dis* 2017;32(09):1285–1288
- 96 Sahakitrungruang C, Pati Wongpaisarn A, Kanjanasilp P, Malakorn S, Atittharnsakul P. A randomized controlled trial comparing colonic irrigation and oral antibiotics administration versus 4% formalin application for treatment of hemorrhagic radiation proctitis. *Dis Colon Rectum* 2012;55(10):1053–1058
- 97 Tjandra JJ, Shomik S. Argon plasma coagulation is an effective treatment for refractory hemorrhagic radiation proctitis. *Diseases of the Colon & Rectum* 2001;44(12):1759–1765
- 98 Sebastian S, et al. Argon plasma coagulation as first-line treatment for chronic radiation proctopathy. *Journal of Gastroenterology and Hepatology* 2004;19(10):1169–1173
- 99 Siow SL, Mahendran HA, Seo CJ. Complication and remission rates after endoscopic argon plasma coagulation in the treatment of haemorrhagic radiation proctitis. *International Journal of Colorectal Disease* 2017;32(01):131–134
- 100 de Oca Megias EM, et al. Short and long term response to argon plasma therapy for hemorrhagic radiation proctitis. *Revista Española de Enfermedades Digestivas (REED)* 2019;111(11):852–858
- 101 Kennedy GD, Heise CPCPKGH. Radiation colitis and proctitis. *Clin Colon Rectal Surg* 2007;20(01):64–72
- 102 Nelamangala Ramakrishnaiah VP, et al. Formalin dab, the effective way of treating haemorrhagic radiation proctitis: a randomized trial from a tertiary care hospital in South India. *Colorectal Disease* 2012;14(07):876–882