



## Technical Note

# Robotic transanal resection for rectal tumor: A description of the technique



Marcus Valadão, Eduardo Rodrigues Zarco Câmara \*, Eduardo Linhares, José Paulo De Jesus, Rodrigo Araújo

Instituto Nacional do Câncer (INCA), Rio de Janeiro, RJ, Brasil

## ARTICLE INFO

## Article history:

Received 29 June 2020

Accepted 26 July 2020

Available online 11 September 2020

## Keywords:

Robotic surgery

Transanal resection

Rectal tumor

TAMIS

Minimally invasive

## ABSTRACT

**Introduction:** Robotic transanal surgery (RTS) is the analog of TAMIS and represents a new focus for the advancement of transanal platforms robotic transanal surgery is sometimes referred to as robotic TAMIS. Though limited to only a few centers world-wide, experience with robotic transanal surgery has been encouraging. Most research with robotic transanal surgery has concentrated on local excision of rectal neoplasia, although more complex procedures such as transanal proctectomy are possible using the robotic approach. This article reports the surgical technique of R-TAMIS performed in the Brazilian National Cancer Institute (INCA, Rio de Janeiro).

**Methods:** 71-year-old, female with cardiologic disease (heart failure), with a 1.5 cm rectal neoplasm at 4 cm from the anal verge in the right anterolateral position. Biopsy revealed neuroendocrine tumor. A complete colonoscopy revealed no evidence of synchronous lesions. Work-up included 3D endorectal ultrasonography and magnetic resonance imaging, which demonstrated the lesion to be uT1uN0. The patient was counseled about surgical options – local excision versus low anterior resection. Due to the cardiologic condition, the patient was elected to proceed with local excision with robotic transanal surgery.

**Conclusion:** Robotic TAMIS is a safe and effective operative procedure for high selected cases of rectal neoplasm. It enhances surgeon ergonomics and facilitates tumor removal and suture in the transanal approach.

© 2020 Sociedade Brasileira de Coloproctologia. Published by Elsevier Editora Ltda. This is an open access article under the CC BY-NC-ND license (<http://creativecommons.org/licenses/by-nc-nd/4.0/>).

## Ressecção transanal robótica para tumor retal: uma descrição da técnica

## RESUMO

**Introdução:** A cirurgia transanal robótica (RTS, Robotic Transanal Surgery) é análoga da TAMIS (cirurgia minimamente invasiva transanal) e representa um novo foco para o avanço das plataformas transanais. A cirurgia transanal robótica é algumas vezes chamada de TAMIS

## Palavras-chave:

Cirurgia robótica

Ressecção transanal

\* Corresponding author.

E-mail: [dreduardocamara@gmail.com](mailto:dreduardocamara@gmail.com) (E.R. Câmara).

<https://doi.org/10.1016/j.jcol.2020.07.001>

2237-9363/© 2020 Sociedade Brasileira de Coloproctologia. Published by Elsevier Editora Ltda. This is an open access article under the CC BY-NC-ND license (<http://creativecommons.org/licenses/by-nc-nd/4.0/>).

Tumor retal  
TAMIS  
Minimamente invasivo

robótica. Embora limitada a apenas alguns centros em todo o mundo, a experiência com a cirurgia transanal robótica tem sido encorajadora. A maioria das pesquisas com cirurgia transanal robótica tem se concentrado na excisão local da neoplasia retal, embora procedimentos mais complexos, como a proctectomia transanal, sejam possíveis utilizando a abordagem robótica. Este artigo relata a técnica cirúrgica de R-TAMIS realizada no Instituto Nacional do Câncer (INCA, Rio de Janeiro).

**Métodos:** paciente de 71 anos, sexo feminino, com doença cardíaca (insuficiência cardíaca), com neoplasia retal de 1,5 cm a 4 cm da borda anal em posição anterolateral direita. A biópsia revelou tumor neuroendócrino. Uma colonoscopia completa não revelou evidências de lesões sincrônicas. A investigação incluiu ultrassonografia endorretal em 3D e ressonância magnética, que demonstrou que a lesão era uT1uN0. A paciente foi aconselhada sobre as opções cirúrgicas – excisão local versus ressecção anterior baixa. Devido à condição cardíaca, optou-se por proceder à excisão local com cirurgia transanal robótica.

**Conclusão:** A TAMIS robótica é um procedimento cirúrgico seguro e eficaz para casos altamente selecionados de neoplasia retal. Ela melhora a ergonomia do cirurgião e facilita a remoção do tumor e a sutura na abordagem transanal.

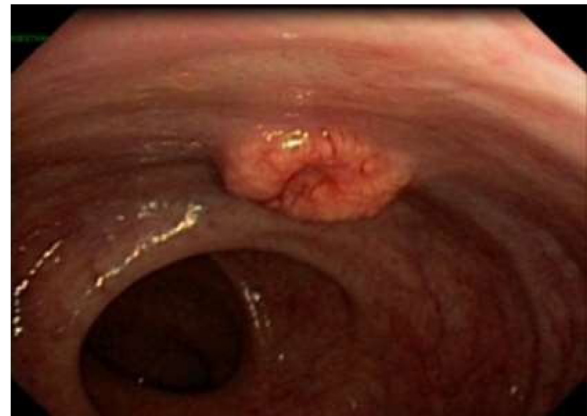
© 2020 Sociedade Brasileira de Coloproctologia. Publicado por Elsevier Editora Ltda. Este é um artigo Open Access sob uma licença CC BY-NC-ND (<http://creativecommons.org/licenses/by-nc-nd/4.0/>).

## Introduction

The approach to local excision of benign and early-stage, well-selected neoplasms of the rectum is evolving. In the mid-1980s, Buess et al. introduced Transanal Endoscopic Microsurgery (TEM).<sup>1,2</sup> In long-term follow-up, TEM excision of rectal lesions has been shown to have favorable oncologic outcomes as well as low morbidity and mortality.<sup>3</sup> However, general adoption of TEM has been limited in clinical practice.<sup>4</sup> Several reasons contributed to this. One of which was the difficult learning curve associated with this technique. Another factor was the limited availability of training, which tended to be at selective centers. A third barrier was the availability of the specialized instruments. And finally, the TEM approach may be unsuitable for lesions closer to the anal verge.<sup>4,5</sup>

To tackle these problems, in 2009, Atallah et al. has pioneered the newer technique of Transanal Minimally Invasive Surgery (TAMIS). This approach used traditional laparoscopic instruments placed through the anus to perform local excision.<sup>3,4</sup> This allowed advanced transanal surgery to be performed at a relatively low cost by using ordinary laparoscopic instruments and devices together with a single-use disposable multi-channel port (TAMIS port). However, laparoscopic instruments were limited by their rigid design and inability to fully articulate. This loss of operative freedom was a great drawback, especially when performing procedures in small space. Nowhere was this more pronounced when operating in the confines of the rectal lumen.<sup>6,7</sup>

In 2010, the Da Vinci Robotic Surgical System (Intuitive Surgical, Inc., Sunnyvale, CA) caught the interest of several surgeons as a possible platform for TAMIS. This was eventually termed Robotic TAMIS (R-TAMIS). Prior to this, robotic surgery had been successfully adopted in many areas of surgery with limited operative space, such as the mediastinum, pelvis and transoral access.<sup>4</sup> The transanal application has been previously tested and potential feasibility validated on a cadaver model.<sup>6</sup> Atallah et al., demonstrated that local excision of a



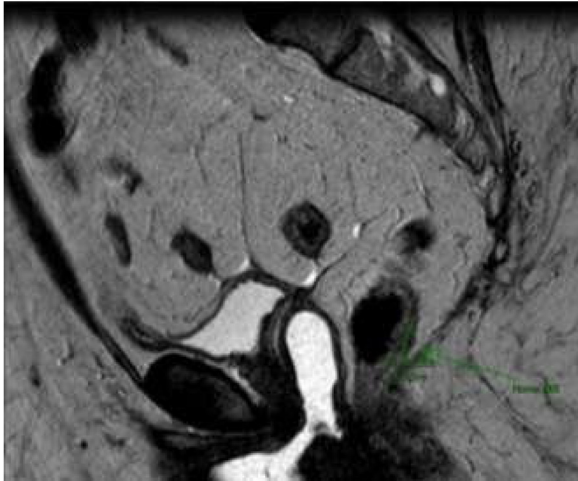
**Fig. 1 – Proctoscope view of the rectal tumor.**

rectal neoplasm using robotic system is indeed feasible in a live patient. Robotic Transanal Surgery (RTS) is the analog of TAMIS and represents a new focus for the advancement of transanal platforms.<sup>8</sup> RTS is sometimes referred to as robotic TAMIS. Though limited to only a few centers world-wide, experience with RTS has been encouraging. Most research with RTS has concentrated on local excision of rectal neoplasia, although more complex procedures such as transanal proctectomy are possible using the robotic approach.<sup>8,9</sup>

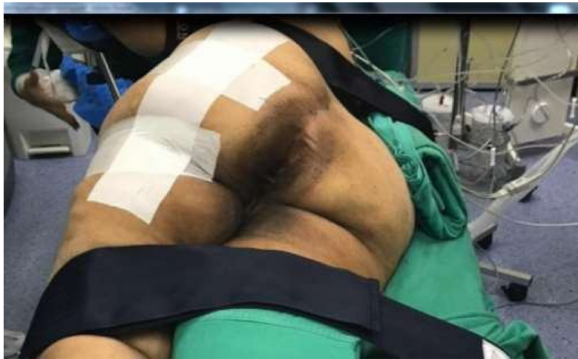This article reports the surgical technique of R-TAMIS performed in the Brazilian National Cancer Institute (INCA, Rio de Janeiro).

## Patient selection

The patient was a 71-year-old female with cardiologic disease (heart failure), with a 1.5 cm rectal neoplasm (Fig. 1) at 4 cm from the anal verge in the right anterolateral position (Fig. 2). Biopsy revealed neuroendocrine tumor. A complete colonoscopy revealed no evidence of synchronous lesions.



**Fig. 2 – MRI view of the tumor (T1N0) 4 cm from the anal verge.**



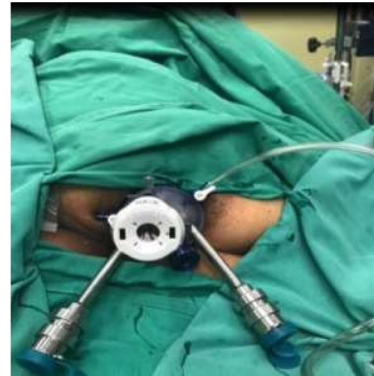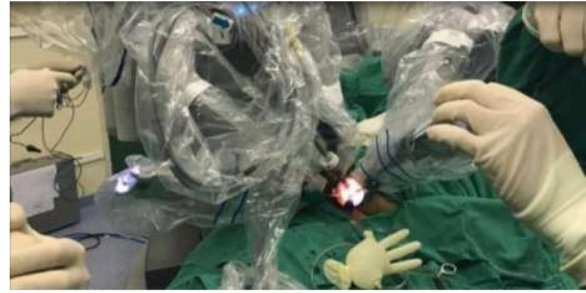**Fig. 3 – Patient positioning in the right-side decubitus, almost in the prone position.**

Work-up included 3D endorectal ultrasonography and magnetic resonance imaging, which demonstrated the lesion to be uT1uN0. The patient was counseled about surgical options – local excision versus low anterior resection. Due to the cardiologic condition, the patient was elected to proceed with local excision with robotic transanal surgery.

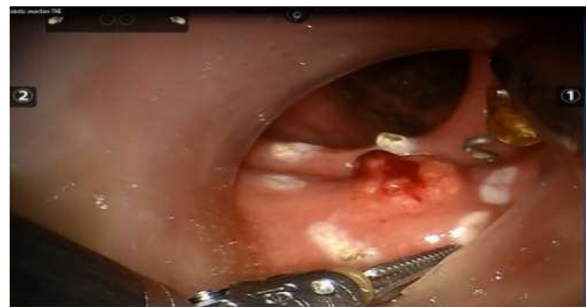### Material and methods

Informed consent was obtained from the patient after a full discussion of the risks, benefits, and alternatives of robotic TAMIS and other excisional procedures. Patient was prescribed rectal enema the day before the surgery and bowel rest after midnight.

Due to a right anterolateral location of the lesion in the rectum, the patient was placed in the right lateral decubitus, almost in the prone position (Fig. 3). A transanal access device (GelPoint Path Transanal Access Platform; Applied Medical Inc. Rancho Santa Margarita, CA, USA) with one 12-mm trocar, two 8-mm robotic trocars and a 5-mm laparoscopic trocar were placed in the anal canal. Pneumorectum of 15mmHg was obtained with standard laparoscopic carbon dioxide insuff-



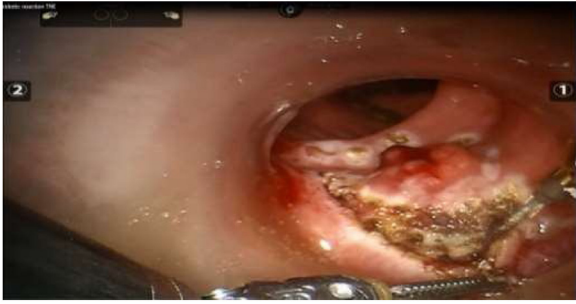**Fig. 4 – Robotic docking and port placement.**



**Fig. 5 – Circumferential marking for adequate excision of the tumor.**

flation. Subsequently, a 12-mm laparoscopic trocar with the robotic camera was placed in the superior midline, two 8-mm robotic working ports in the left inferior and right inferior posterior position and one 5-mm laparoscopic trocar in the inferior midline position (Fig. 4). The robot was then docked from the right side of the patient with the base of the robot positioned at a 45° angle with the bed (Fig. 4). Na 12-mm robotic camera with 30° upward positioning was introduced in the superior middle trocar, a robotic hook with monopolar energy followed by a needle holder in the right working port, a robotic Maryland dissector with bipolar energy followed by a fenestrated grasper in the left working port, and a standard laparoscopic suction device in the inferior midline position.

The lesion was initially marked circumferentially for adequate margins and a full-thickness excision accomplished using the above-mentioned instruments (Fig. 5). The defect was 3 × 3 cm inside. Na 10-cm 3–0 Vicryl was introduced through the 12-mm laparoscopic trocar and the defect was



**Fig. 6 – Tumor removal.**

closed using the Vicryl running suture technique with the robotic arms.

The patient had an uneventful recovery and was discharged 2 days after surgery. Pathologic report revealed a well differentiated neuroendocrine tumor with 1.5 cm, invading mucosa, and submucosa with negative resection margins. Ki-67 of 13%.

## Discussion

Laparoscopic TAMIS is a challenging technique due to the limitation of the instrument manipulation in and out of the trocar and instrument crossing. Utilization of robotic systems has been progressively expanded, and is particularly successful in areas of confined anatomy such as the deep pelvis and transorally.<sup>1,3</sup> The use of the 360° movement of an EndoWrist feature in the rectal lumen is the key advantage of the robotic system. The use of the robotic approach improves surgical ergonomics (operating at the robot console instead of between the legs of the patient is much more comfortable for the surgeon) and facilitates tumor removal and suture closure of the final defect when compared with laparoscopic TAMIS due to the articulated instruments and the capability to work in narrow space, which leads to more efficient operations (Fig. 6).<sup>3,5,8</sup> The ability to rotate the robotic operative field allows the surgeon to work on all walls of the rectum rather than a single quadrant. In our case, we decided to position the patient in a way that the tumor would be placed in the bottom. We think this position would improve the ability to remove the tumor and suture close the defect.<sup>6,7</sup> In that way, using the camera in the 30° upward position preclude robotic arms collisions. The drawback of this patient position is that the access to the abdomen is not possible if an urgent conversion is needed, although the chance to require a conversion to an abdominal approach is low.<sup>1,4,5</sup>

The GelPoint Path Transanal Access Platform (Applied Medical Inc. Rancho Santa Margarita, CA, USA) is a useful tool to perform the robotic TAMIS because this device can provide a satisfactory port placement in order to prevent robotic arm collisions and improve surgical efficiency.<sup>1</sup>

There is no doubt that the robotic platform may possibly expand the use of transanal access surgery by allowing even more complex procedures. In the other hand, the main limitation of this technique is its high cost.<sup>1,9</sup>

## Conclusion

Robotic TAMIS is a safe and effective operative procedure for high selected cases of rectal neoplasm. It enhances surgeon ergonomics and facilitates tumor removal and suture in the transanal approach.

## Conflicts of interest

The authors declare no conflicts of interest.

## REFERENCES

1. Atallah S, Parra-Davila E, deBeche-Adams T, Albert M, Larach S. Excision of a rectal neoplasm using Robotic Transanal Surgery (RTS): a description of the technique. *Tech. Coloproctol.* 2012;6:389-92.
2. Buess R, Theiss G, Guenther M, Hutterer F, Pichlmaier. Transanal endoscopic microsurgery. *Leber. Magen. Darm.* 1985;15:271-9.
3. Atallah S, Albert M, Larach S. Transanal minimally invasive surgery: a giant leap forward. *Surg. Endosc.* 2010;24:2200-5.
4. Liu S, Suzuki T, Murray BW, Parry L, Johnson CS, Horgan S, et al. Robotic Transanal Minimally Invasive Surgery (TAMIS) with the newest robotic surgical platform: a multi-institutional North American experience. *Surg. Endosc.* 2019;33:543.
5. Atalla SB, Albert MR, deBeche-Adams TH, Larach SW. Robotic transanal minimally invasive surgery in a cadaveric model. *Tech. Coloproctol.* 2011;15:461-4.
6. Bardakcioglu O. Robotic transanal access surgery. *Surg. Endosc.* 2012;27:1407-9.
7. Van den Boezem PB, Kruyt PM, Stommel MW, Morales RT, Cuesta MA, Sietes C. Transanal single-port surgery for the resection of large polyps. *Dig. Surg.* 2011;28:412-6.
8. Atallah S, Quinteros F, Martin-Perez B, Larach S. Robotic transanal surgery for local excision of rectal neoplasms. *J. Robot. Surg.* 2014;8:193-4.
9. Tomassi MJ, Taller J, Yuhan R, Ruan JH. Robotic transanal minimally invasive surgery or the excision of rectal neoplasia: clinical experience with 58 consecutive patients. *Dis. Colon. Rectum.* 2019;62:279-85.