


Tailgut Cyst – A Case Report

Bruno Lorenzo Scolaro¹ Gustavo Becker Pereira¹ Fangio Ferrari¹ Letícia Dall'Agnol¹
Lívia de Aragon Arias¹ Anísio de Souza Neto¹

¹UNIVALI (Universidade do Vale do Itajaí), Itajaí, SC, Brazil

J Coloproctol 2022;42(2):190–192.

Address for correspondence Letícia Dall'Agnol, Genésio Vieira St, n. 100, Bairro Espinheiros, Itajaí-SC, 88317-390, Brazil (e-mail: leticiadallagnol2@gmail.com).

Abstract

Retrorectal hamartoma, also called tailgut cyst, is a congenital lesion resulting from the non-regression of embryo remnants of the hindgut. We describe in this work the case report of a 68-year-old man, previously healthy, complaining of rectal bulging for 4 months, which was diagnosed by nuclear magnetic resonance imaging as a multiloculated and mucinous lesion, suggestive of tailgut cyst. In view of the finding, the lesion was surgically resected, due to the potential for future complications, and, through the anatomopathological analysis, there were no findings of malignancy in the specimen.

Keywords

- ▶ pelvic neoplasms
- ▶ cysts
- ▶ congenital abnormalities

Introduction

Retrorectal hamartoma, or tailgut cyst, is a rare congenital tumor with an estimated incidence of 1/40,000, from the non-regression of the secretory embryonic remnants of mucus of the posterior intestine.¹

The lesions preferentially affect female patients, aged between 30 and 60 years, being mostly asymptomatic, benign, and found in the retrorectal space through imaging.²

Case Report

A male patient, 68 years old, of Japanese descent, previously healthy, complained of perianal bulging for 4 months. During the proctological consultation, through the digital examination of the anal canal, a bulging of approximately 6 cm was verified, with fibroelastic consistency. Anemia, organic dysfunctions, or hydroelectrolytic disorders were not evidenced at laboratory tests.

Through magnetic resonance imaging (MRI) of the pelvis, a multiloculated cyst with hyperprotein, hemotic, mucinous content was observed. It was located after the anal canal,

apparently transfixing some fibers of the right puborectal muscle, and insinuating itself into the right ischioanal fossa. Among the diagnostic possibilities, it was advisable to consider the hypothesis of retrorectal hamartoma (tailgut cyst) (► **Figure 1**).

The patient underwent surgical intervention using a Parks incision for the excision of the lesion (► **Figures 2 and 3**) and evolved without complications in the postoperative period. The anatomopathological analysis of the surgical specimen showed multiloculated cystic lesion coated with squamous, mucoproducing and ciliate epithelium, without atypia, favoring the diagnosis of tailgut cyst. The patient presented good postoperative evolution and remains under clinical follow-up, with no signs of recurrence.

Discussion

The retrorectal space is first surrounded by the rectum, and then by the sacrum and coccyx, superiorly by the phemonium, inferiorly by the elevator muscles of the anus and coccygeal, and laterally by the ureter and iliac vessels.

received
December 9, 2021
accepted
April 11, 2022

DOI <https://doi.org/10.1055/s-0042-1749085>.
ISSN 2237-9363.

© 2022. Sociedade Brasileira de Coloproctologia. All rights reserved.

This is an open access article published by Thieme under the terms of the Creative Commons Attribution-NonDerivative-NonCommercial-License, permitting copying and reproduction so long as the original work is given appropriate credit. Contents may not be used for commercial purposes, or adapted, remixed, transformed or built upon. (<https://creativecommons.org/licenses/by-nc-nd/4.0/>)

Thieme Revinter Publicações Ltda., Rua do Matoso 170, Rio de Janeiro, RJ, CEP 20270-135, Brazil

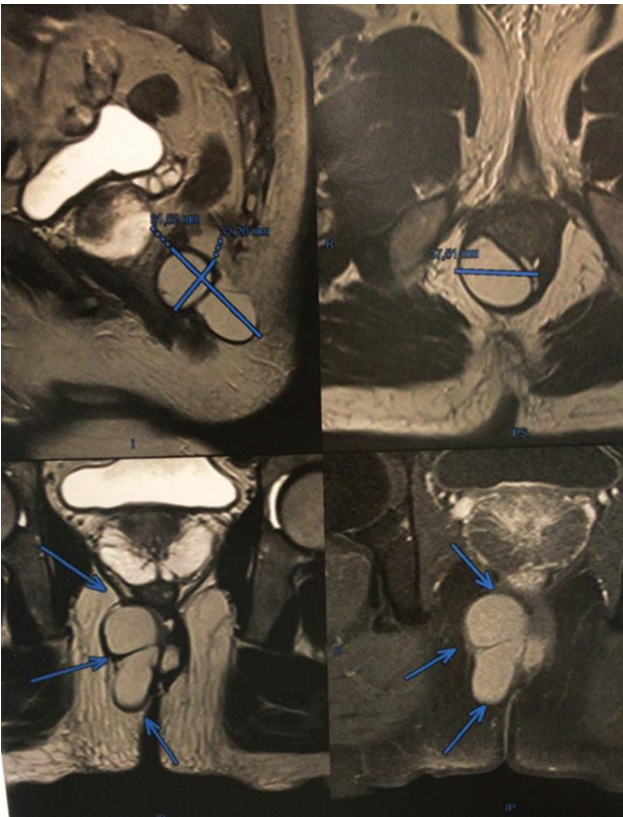


Fig. 1 Magnetic resonance imaging of the pelvis (perianal), with cystic lesion.

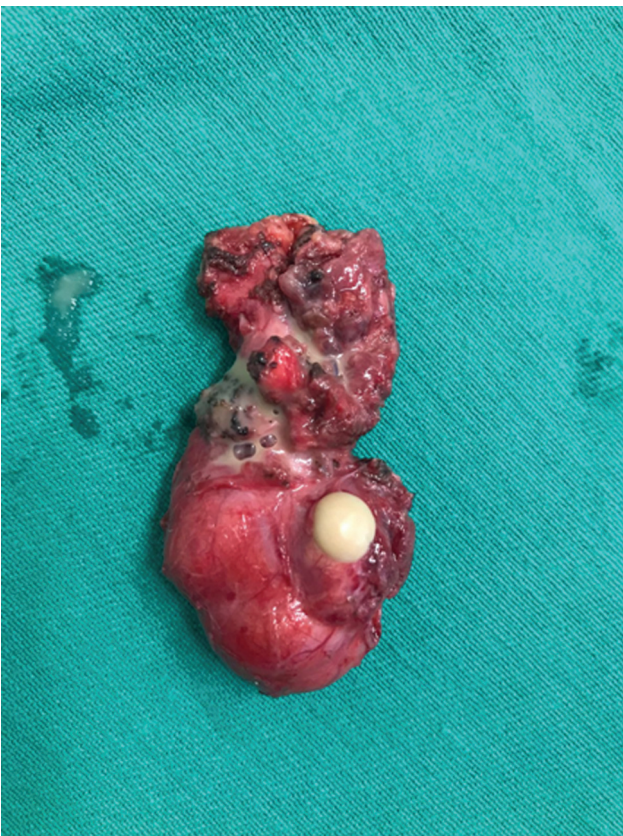

Fig. 2 Cystic lesion – incidence 1.

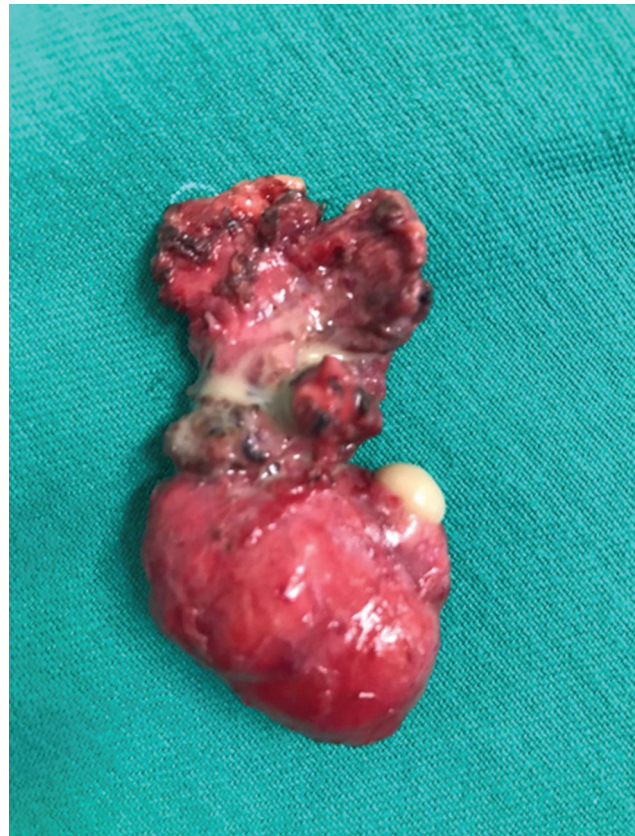

Fig. 3 Cystic lesion – incidence 2.

Although cases of tailgut cyst are mostly asymptomatic, due to contact with different structures located in the retrorectal space, their clinical manifestations can mimic those of different urological, neurological, or gastrointestinal pathologies.³

Acute urinary retention and intestinal obstruction have already been reported in the presence of large cysts.⁴ There are also reports of cysts prolapsed through the anus, mistakenly diagnosed as hemorrhoids.⁵ On the other hand, typical signs and symptoms of perianal abscesses were identified in the presence of infection of the lesion; furthermore, with the natural development of the disease, perianal fistulas may arise.⁶ Although rare, overlapping malignancy may exist and, in this case, the most frequent histological types are adenocarcinomas and carcinoid tumors.²

Contrast-based pelvic MRI is the gold standard for the evaluation of the lesion by imaging, due to the better resolution for soft tissues, which provides an adequate design of the anatomical extension of the tumor and characterization of tissues. Retrorectal mass biopsy is controversial, since although they allow definitive diagnosis and surgical planning, they can lead to contamination or dissemination of a malignant tumor.³

Excision of these lesions is recommended for the treatment of symptomatic and asymptomatic patients, since it allows to rule out underlying malignancy and prevent future malignant transformations, infections, defecation difficulties or potential dystocia in pregnant women. A wide range of surgical approaches is described in the literature, such as

transabdominal, by laparotomy or laparoscopy, transsacral, intersphincteric or transsphincter.²

Conclusion

Due to its low incidence in the population and assumed variation in clinical practice according to the size and extent within the retrorectal space, the tailgut cyst becomes an entity of lower suspicion among the diagnostic possibilities, regardless of clinical manifestations, being often an imaging or pathological finding after surgical intervention.

Also, due to the low occurrence, studies evaluating the risk of malignancy, as well as associated risk and protective factors are controversial or little known. Therefore, currently, the conduct before an image suggestive of the lesion remains surgical.

It is important to highlight that the tailgut cyst can be manifested through different common complaints from the office of the coloproctologist, gastroenterologist, or general practitioner, and it is important to include the lesion in differential diagnoses, especially in the presence of anal

prolapse, anal fistulas, urinary retention, intestinal obstruction, and perianal abscesses.⁴⁻⁶

Conflict of Interests

The authors have no conflict of interests to declare.

References

- 1 Pontes JM, Pimenta MBF, Leite CRC, et al. Hamartoma cístico retrorretal (tailgut cyst): relato de caso. *J Coloproctol (Rio J)* 2019
- 2 Haydar M, Griepentrog K. Tailgut cyst: A case report and literature review. *Int J Surg Case Rep* 2015;10:166–168
- 3 Martins P, Canotilho R, Peyroteo M, Afonso M, Moreira A, De Sousa A. Tailgut cyst adenocarcinoma Article. *Clin Case Rep* 2020
- 4 Abraham VJ, Peacock M, Mammen KJ. Acute urinary retention and obstipation: a rare cause.... *Indian J Surg* 2013;75(01):71–72
- 5 Leo JM, O'Connor KM, Pezim M, Nagy A, Schaeffer DF. Benign tailgut cyst masquerading as a hemorrhoid. *Can J Gastroenterol Hepatol* 2014;28(04):183
- 6 Johnson KN, Young-Fadok TM, Carpentieri D, Acosta JM, Notrica DM. Case report: misdiagnosis of tailgut cyst presenting as recurrent perianal fistula with pelvic abscess. *J Pediatr Surg* 2013;48(02):e33–e36