

Infliximab for Anoperineal Lesions in Crohn's Disease: Remission Appears to be Based on Rapid Combination Therapy at High Doses

Nadia Fathallah¹ Cosmin Cristea¹ Hélène Beaussier² Sonia Khirani³ Vincent de Parades¹

¹Groupe Hospitalier Paris Saint-Joseph, MedicoSurgical Proctology Department, Paris, France

²Groupe Hospitalier Paris Saint-Joseph, Clinical Research Center, Paris, France

³Assistance Publique-Hôpitaux de Paris, Hôpital Necker, Clinical Investigation Center, Paris, France

Address for correspondence Nadia Fathallah, MD, Groupe Hospitalier Paris Saint-Joseph, Medico Surgical Proctology Department, 185, rue Raymond Losserand, 75014 Paris, France
(e-mail: nfathallah@ghpsj.fr).

J Coloproctol 2022;42(2):126–130.

Abstract

Study Aim The aim of the present study was to compare in real life the characteristics of treatment with infliximab according to the presence or absence of anoperineal involvement in Crohn's disease.

Methods We performed a single-center, prospective, non-interventional study, on patients with Crohn's disease in remission who had been treated with infliximab for at least 1 year. Patients with poor treatment compliance, on antibiotics, or those with a stoma were excluded.

Results We included 52 patients in this study: 34 with anoperineal lesions with or without luminal lesions, and 18 with luminal lesions only. Patients with anoperineal lesions were more likely to have undergone surgery (70.6% versus 38.9%, $p = 0.027$), had a shorter median time to infliximab treatment initiation (0.5 versus 5.5 years, $p = 0.005$), a higher mean dose of infliximab (6.6 versus 5.1 mg/kg, $p = 0.015$), and were more likely to receive combination treatments including infliximab (52.9% versus 11.1%, $p = 0.008$) than patients with luminal involvement only.

Conclusions In our study, infliximab treatment was initiated more quickly, at higher doses, and more in combination therapy for anoperineal Crohn's disease than for luminal damage alone. Additional studies are required to confirm this finding and to assess the tolerance of this treatment throughout patient management.

Keywords

- Crohn's disease
- infliximab
- anal fistula
- anoperineal disease

Introduction

Anoperineal lesions are frequent in Crohn's disease, with a cumulative probability, after 20 years of disease, of 43%, and a probability of fistulas of 28%.¹ These lesions significantly

affect quality of life² and are associated with a poor prognosis of the disease.³ The latest recommendations emphasize the importance of early medical and surgical management.^{4–7} Surgical management should be rapid, and it should consist of the drainage of abscesses and fistulas. Drug treatment

received
September 4, 2021
accepted after revision
October 25, 2021
published online
December 10, 2021

DOI <https://doi.org/10.1055/s-0041-1739549>.
ISSN 2237-9363.

© 2021. Sociedade Brasileira de Coloproctologia. All rights reserved.

This is an open access article published by Thieme under the terms of the Creative Commons Attribution-NonDerivative-NonCommercial-License, permitting copying and reproduction so long as the original work is given appropriate credit. Contents may not be used for commercial purposes, or adapted, remixed, transformed or built upon. (<https://creativecommons.org/licenses/by-nc-nd/4.0/>)

Thieme Revinter Publicações Ltda., Rua do Matoso 170, Rio de Janeiro, RJ, CEP 20270-135, Brazil

should be based on the combination of an anti-TNF- α therapy and an immunosuppressor, particularly in cases of complex lesions.^{4,8} The anti-TNF- α drug with the highest level of evidence in this context is infliximab. Indeed, this drug has been tested in a dedicated randomized controlled trial,⁹ whereas the efficacy of other anti-TNF- α drugs has been evaluated only in post-hoc studies not dedicated to anoperineal lesions.¹⁰ These recommendations for optimal treatment from the start are less formal for severe luminal damage.^{4,8}

The aim of the present study was to compare, in real life, the characteristics of infliximab treatment between patients with anoperineal lesions (with or without luminal lesions) and patients with luminal lesions only, among patients considered to be in remission for Crohn's disease followed at our center.

Patients and Methods

Inclusion and Exclusion Criteria

All patients followed at Paris Saint-Joseph Hospital for Crohn's disease in remission who had been on infliximab treatment for at least 1 year were included. Patients who were not in remission, had poor treatment compliance, were on antibiotic treatment, had a stoma, or refused to participate in the study were excluded.

Antibiotic use and/or the presence of a stoma have been considered to be factors that may affect the rate of remission outside of treatment with infliximab.

Remission had to be confirmed clinically (perineal disease activity index [PDAI] and Harvey-Bradshaw scores < 4 at inclusion), biologically (C-reactive protein [CRP] level < 6 mg/l), endoscopically (colonoscopy in the 6 months preceding inclusion), and radiologically (entero-magnetic resonance imaging [MRI] and anoperineal MRI in the 6 months preceding inclusion). The MRI criteria for anoperineal remission were based on an absence of collection of more than 1 cm and on the disappearance of hyperintensity on T2 sequences.

Course of the Study

We performed a single-center, prospective, non-interventional study. All patients meeting the inclusion criteria and presenting at the day hospital for infliximab infusion between January 1, 2018 and March 1, 2018 were included. In accordance with French and European recommendations,^{4,6,7} infliximab treatment was initiated immediately in cases of severe, or serious disease, as well as in cases of classical treatment failure and of prior bioterapy treatment failure or escape.

On the day of inclusion, just before the scheduled perfusion of infliximab, a blood sample was collected to determine the residual levels of infliximab and to test for anti-infliximab antibodies in an enzyme-linked immunosorbent assay (ELISA).¹¹ The patients were then examined by a doctor from the department, and a data collection form was completed, including demographic data, the site and classification of the disease according to the Montreal scale, a description of fistulous anoperineal lesions according to the UFS classifica-

tion (Ulceration/Fistula/Stenosis classification also called CARDIFF classification)¹² and American Gastroenterological Association (AGA)¹³ classification, surgical history, previous and concomitant treatments.

Ethics

The study was approved by the institutional review board (no. 289). In accordance with French law, all patients received an information form and declared their non-opposition, which was recorded in their medical files. The authors attest to the exhaustivity and exactness of the data and analyses, and the conformity of the trial to the protocol.

Statistical Analysis

Quantitative data are presented as means (\pm standard deviation) or medians (interquartile range [IQR]). Qualitative data are presented as absolute numbers and proportions. Comparisons between two groups were performed with Student *t* tests, or with Mann-Whitney *U* tests if the data did not follow a normal distribution. For qualitative data, comparisons were performed with χ^2 tests, or Fisher exact tests if the conditions for the χ^2 test were not respected (at least five members of each group). A *p* value < 0.05 was considered significant. Statistical analyses were performed with SigmaPlot v.13.0 software.

Results

Description of the Study Population

We included 52 patients in the study, and another 53 patients were excluded (\rightarrow Fig. 1).

The characteristics of the 52 patients included are summarized in \rightarrow Table 1. Anoperineal lesions were identified in 34 patients, including 4 in whom these lesions were isolated (no luminal lesions). According to the UFS classification, the lesions were primary isolated lesions (deep canal ulcerations with extension to the anal margin) in 9 cases, and secondary lesions (fistulas/abscesses) with or without primary lesions in 25 cases. According to the AGA classification, the fistulas were complex in all cases, following a single high path in 10 patients, 2 paths in 9 patients, and more than 3 paths in 6 patients.

Thirty-one patients had undergone surgery for Crohn's disease: 24 in the anoperineal \pm luminal lesions group (70.6%

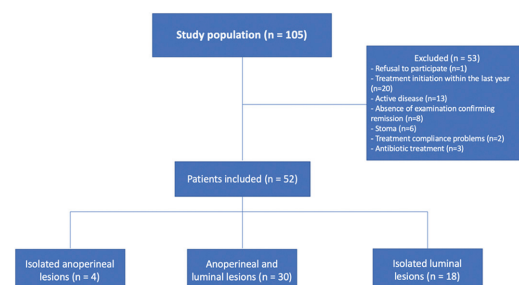


Fig. 1 Flow chart.

Table 1 Characteristics of the study population

N = 52	
Number of women: n (%)	24 (46)
Mean age (years)	38 (\pm 14)
Type of lesions:	
Exclusively luminal: n (%)	18 (35)
Mixed, luminal and anoperineal: n (%)	30 (58)
Exclusively anoperineal: n (%)	4 (7)
Montreal classification	
A1: n	8
A2: n	30
A3: n	14
L1: n	9
L2: n	17
L3: n	22
L4: n	0
B1: n	31
B2: n	9
B3: n	12
P: n	34
Surgical history: n (%)	31 (60.0)
Anoperineal surgery only: n (%)	20 (38.5)
Luminal surgery only: n (%)	7 (13.5)
Anoperineal and luminal surgery: n (%)	4 (8.0)

of the total number of patients in this group), and 7 (38.9%) in the group of patients with luminal lesions only. In all 24 patients in the anoperineal \pm luminal lesions group who underwent surgery, interventions were anoperineal, with 4 of these patients also undergoing luminal interventions. In the anoperineal area, 1 surgical procedure was performed in 11 patients, 2 procedures were performed in 5 patients, and 3 or more procedures were performed in 8 patients. These procedures consisted of the drainage of abscesses and fistulas in 38 cases, and sphincter-saving techniques in 10 cases: fistula laser closure ($n=6$) or endorectal advancement flap ($n=4$). No interventions were performed on any of the primary ulcerated anoperineal lesions. Only one patient did not undergo surgery due to a single fistula path associated with few symptoms and not linked to abscesses, which closed rapidly on infliximab treatment. For luminal surgery ($n=4$), 3 patients underwent ileocecal resection, and 1 patient underwent 2 segmental small intestine resections.

A single surgical procedure was performed in 6 of the 7 patients with exclusively luminal lesions who underwent surgery, and 3 procedures were performed in the remaining patient. The procedures performed were ileocecal resection ($n=5$) and segmental small intestine resection ($n=4$)

No significant infectious or oncological complications were reported in the study population at the time of data analysis.

Table 2 Characteristics of infliximab treatment

N = 52	
Median time to treatment initiation (years)	1.0 (0.0–6.0)
Combination treatment: n (%)	20 (38.5)
- Azathioprine: n (%)	19 (36.5)
- Methotrexate: n (%)	1 (1.9)
Optimization of infliximab treatment: n (%)	28 (53.8)
Mean dose of infliximab (mg/kg)	6.1 \pm 2.0
Mean time interval between perfusions (weeks)	7.3 \pm 1.3
Median residual concentration of infliximab (μ g/ml)	5.4 (2.4–9.1)
Positive for anti-infliximab antibodies: n (%)	7 (13)

Characteristics of Infliximab Treatment

The characteristics of infliximab treatment in the study population are summarized in ►Table 2.

The treatment was optimized in 28 patients (53.8%), by increasing the dose in 6 patients, by decreasing the interval between perfusions in 15 patients, and by both methods in 7 patients. Fourteen patients (26.9%) had already received a first-line biological treatment before infliximab. This treatment was adalimumab in all cases. The median residual concentration of infliximab was 5.2 (2.4–9.1) μ g/ml, and residual infliximab concentration exceeded 15 μ g/ml in 8 patients.

Characteristics of Infliximab Treatment as a Function of Disease Site

The characteristics of infliximab treatment as a function of lesion type (anoperineal \pm luminal versus exclusively luminal) are summarized in ►Table 3.

Infliximab treatment was optimized in 21 patients with anoperineal lesions (61.8%), by an increase in dose in 6 patients, a decrease in the interval between perfusions in 9 patients, and by both approaches in 6 patients. Infliximab treatment was optimized in 7 patients with exclusively luminal lesions (38.9%), by a decrease in the interval between perfusions in 6 patients and by both a decrease in the interval between perfusions and an increase in dose in 1 patient.

Discussion

Our results show that the median time to the initiation of infliximab treatment was shorter (0.5 versus 5.5 years, $p=0.005$), the mean dose was higher (6.6 versus 5.1 mg/kg, $p=0.015$), and combination treatment was more frequent (52.9% versus 11.1%, $p=0.008$) in patients with anoperineal Crohn's disease lesions than in patients with exclusively luminal lesions.

In recent years, the conventional *step-up* strategy for treating Crohn's disease has been increasingly challenged by proponents of the *top-down* strategy. Indeed, the top-down strategy seems to act more effectively on tissue

Table 3 Characteristics of infliximab treatment by disease site

	Anoperineal ± luminal lesions (n = 34)	Luminal lesions only (n = 18)	P
Median age at time of disease diagnosis (years)	28.0 (21.0–40.7)	25.0 (19.7–36.3)	0.430
Median time from diagnosis to the initiation of infliximab treatment (years)	0.5 (0.0–3.0)	5.5 (1.2–8.5)	0.005
Prior treatment with adalimumab: n (%)	7 (20.6)	7 (39.0)	0.289
Combination treatment: n (%)	18 (52.9)	2 (11.1)	0.008
Mean dose of infliximab (mg/kg)	6.6 ± 2.3	5.1 ± 0.6	0.015
Mean interval between perfusions (weeks)	7.3 ± 1.4	7.4 ± 1.2	0.613
Mean residual infliximab concentration (µg/ml)	5.7 [2.4 - 12.8]	4.6 [2.4 - 6.1]	0.252
Positive for anti-infliximab antibodies: n (%)	6 (17.7)	1 (5.6)	0.441
History of surgery: n (%)	24 (70.6)	7 (38.9)	0.027

destruction index and the natural course of Crohn's disease.¹⁴ However, in clinical practice, this aggressive strategy has yet to impose itself as the approach of choice, particularly for anoperineal lesions. The possible reasons for this include the difficulty diagnosing and classifying these lesions, the possible dissociation of the severity of luminal and anoperineal lesions, the additional cost, and fears about the potential adverse effects of treatments.¹⁴ Nevertheless, this *top-down* strategy makes sense because we know that anoperineal lesions are associated with a poor prognosis of the disease³ and that these lesions have a significant impact on the quality of life of the patients, with a non-negligible risk of anal incontinence.² In our series, anoperineal lesions were associated with a higher likelihood of surgical management ($p = 0.027$). In addition, 23.5% of patients with anoperineal lesions had undergone surgery at least 3 times. This finding confirms the disabling nature of these lesions, in terms of the frequent suppurative complications and recurrences, requiring frequent drainage procedures.

The most recent French clinical practice recommendations⁴ suggest that, in cases of anoperineal lesions, an anti-TNF- α drug, preferably infliximab, should be introduced rapidly, together with an immunosuppressor. The preference of infliximab over the other types of biotherapies available reflects the higher level of evidence obtained for this molecule. Indeed, infliximab is the only anti-TNF- α treatment shown to be effective against fistulas in a randomized placebo-controlled trial.⁹ The use of a combination of infliximab and azathioprine seems to increase the rate of anal fistula closure over that achieved with infliximab alone: 84.6% versus 76.6% in the study by Bouguen et al.¹⁵ and 66.7% versus 34.7% in the study by Rasul et al.¹⁶ This positive effect is thought to be due to both the direct effects of azathioprine itself on the lesions,¹⁷ but also to the ability of this drug to decrease the immunogenicity of infliximab.¹⁸

In addition, recent studies have suggested that anoperineal lesions require a higher dose of infliximab than luminal lesions, for remission to be achieved. These studies were based on the determination of residual concentrations of infliximab.^{19,20} This need for a higher dose may be explained

by the high inflammatory burden of anoperineal lesions and by the probable difficulty achieving adequate tissue concentrations of the anti-TNF- α drug in these deep and fibrous lesions.^{19,21} In our study, the mean dose of infliximab was significantly higher in cases of anoperineal lesions (6.6 versus 5.1 mg/kg). Similarly, the median residual concentration of infliximab was higher in cases of anoperineal lesions (5.7 versus 4.6 µg/l). However, this last finding was not statistically significant, probably due to the small size of our study population.

The small number of patients included in the study, due partly to the very strict inclusion criteria applied, is one of the limitations of our study. There is also a probable tertiary center effect associated with the proctological surgical department, resulting in the selection of patients with the most severe anoperineal lesions. Finally, the follow-up period of this study is too short to conclude that more aggressive medical management is innocuous.

In conclusion, at our center, the treatment with infliximab was more aggressive (early administration, high dose, and combination therapy) in patients with anoperineal involvement compared with those with luminal involvement only. This therapeutic attitude is in line with French and European recommendations.^{4,8} Additional studies are required to confirm this finding and to assess the tolerance of this treatment throughout patient management.

Funding
None.

References

- Eglinton TW, Barclay ML, Gearry RB, Frizelle FA. The spectrum of perianal Crohn's disease in a population-based cohort. *Dis Colon Rectum* 2012;55(07):773–777
- Mahadev S, Young JM, Selby W, Solomon MJ. Quality of life in perianal Crohn's disease: what do patients consider important? *Dis Colon Rectum* 2011;54(05):579–585
- Beaugerie L, Seksik P, Nion-Larmurier I, Gendre JP, Cosnes J. Predictors of Crohn's disease. *Gastroenterology* 2006;130(03):650–656

- 4 Bouchard D, Abramowitz L, Bouguen G, et al. Anoperineal lesions in Crohn's disease: French recommendations for clinical practice. *Tech Coloproctol* 2017;21(09):683–691
- 5 Tandon P, Rhee GG, Schwartz D, McCurdy JD. Strategies to Optimize Anti-tumor Necrosis Factor Therapy for Perianal Fistulizing Crohn's Disease: A Systematic Review. *Dig Dis Sci* 2019;64(11):3066–3077
- 6 Torres J, Bonovas S, Doherty G, et al. ECCO Guidelines on Therapeutics in Crohn's Disease: Medical Treatment. *J Crohn's Colitis* 2020;14(01):4–22
- 7 Adamina M, Bonovas S, Raine T, et al. ECCO Guidelines on Therapeutics in Crohn's Disease: Surgical Treatment. *J Crohn's Colitis* 2020;14(02):155–168
- 8 Gionchetti P, Dignass A, Danese S, et al; ECCO. 3rd European evidence-based consensus on the diagnosis and management of Crohn's disease 2016: part 2: surgical management and special situations. *J Crohn's Colitis* 2017;11(02):135–149
- 9 Present DH, Rutgeerts P, Targan S, et al. Infliximab for the treatment of fistulas in patients with Crohn's disease. *N Engl J Med* 1999;340(18):1398–1405
- 10 Thomassin L, Armengol-Debeir L, Charpentier C, et al. Magnetic resonance imaging may predict deep remission in patients with perianal fistulizing Crohn's disease. *World J Gastroenterol* 2017;23(23):4285–4292
- 11 Ben-Horin S, Chowers Y. Review article: loss of response to anti-TNF treatments in Crohn's disease. *Aliment Pharmacol Ther* 2011;33(09):987–995
- 12 Hughes LE. Clinical classification of perianal Crohn's disease. *Dis Colon Rectum* 1992;35(10):928–932
- 13 Sandborn WJ, Fazio VW, Feagan BG, Hanauer SB American Gastroenterological Association Clinical Practice Committee. AGA technical review on perianal Crohn's disease. *Gastroenterology* 2003;125(05):1508–1530
- 14 Berg DR, Colombel JF, Ungaro R. The Role of Early Biologic Therapy in Inflammatory Bowel Disease. *Inflamm Bowel Dis* 2019;25(12):1896–1905
- 15 Bouguen G, Siproudhis L, Gizard E, et al. Long-term outcome of perianal fistulizing Crohn's disease treated with infliximab. *Clin Gastroenterol Hepatol* 2013;11(08):975–81.e1, 4
- 16 Rasul I, Wilson SR, MacRae H, Irwin S, Greenberg GR. Clinical and radiological responses after infliximab treatment for perianal fistulizing Crohn's disease. *Am J Gastroenterol* 2004;99(01):82–88
- 17 Lecomte T, Contou J-F, Beaugerie L, et al. Predictive factors of response of perianal Crohn's disease to azathioprine or 6-mercaptopurine. *Dis Colon Rectum* 2003;46(11):1469–1475
- 18 Colombel JF, Adedokun OJ, Gasink C, et al. Combination Therapy with Infliximab and Azathioprine Improves Infliximab Pharmacokinetic Features and Efficacy: A Post Hoc Analysis. *Clin Gastroenterol Hepatol* 2019;17(08):1525–1532.e1
- 19 Yarur AJ, Kanagala V, Stein DJ, et al. Higher infliximab trough levels are associated with perianal fistula healing in patients with Crohn's disease. *Aliment Pharmacol Ther* 2017;45(07):933–940
- 20 Davidov Y, Ungar B, Bar-Yoseph H, et al. Association of Induction Infliximab Levels With Clinical Response in Perianal Crohn's Disease. *J Crohn's Colitis* 2017;11(05):549–555
- 21 Ungar B, Levy I, Yavne Y, et al. Optimizing anti-TNF-alpha therapy: serum levels of infliximab and adalimumab are associated with mucosal healing in patients with inflammatory bowel diseases. *Clin Gastroenterol Hepatol* 2016;14(04):550–557.e2