



# Journal of Coloproctology

www.jcol.org.br



## Technical Note

# Resection of ischiorectal fossa tumors – surgical technique



Eduardo Fonseca Alves Filho<sup>a,\*</sup>, Alexandre Lopes de Carvalho<sup>a</sup>,  
Paulo Frederico de Oliveira Costa<sup>a</sup>, Antonio Carlos de Carvalho<sup>b</sup>

<sup>a</sup> Hospital Português da Bahia, Salvador, BA, Brazil

<sup>b</sup> Hospital Geral Roberto Santos, Salvador, BA, Brazil

### ARTICLE INFO

#### Article history:

Received 3 April 2015

Accepted 13 April 2016

Available online 9 May 2016

#### Keywords:

Ischiorectal fossa tumors

Neoplasms

Solitary fibrous tumors

### ABSTRACT

Primary tumors of the ischiorectal fossa are rare, they can be congenital, acquired or neoplastic. Accurate diagnosis often cannot be done preoperatively and imaging studies such as computed tomography and especially magnetic resonance imaging can define the size and anatomical relationships of the lesions. Surgical treatment is challenging because of difficult access of the region which is preferably performed by posterior approach. We describe the etiology, diagnosis and operative technique of tumors of the ischiorectal fossa.

© 2016 Sociedade Brasileira de Coloproctologia. Published by Elsevier Editora Ltda. This is an open access article under the CC BY-NC-ND license (<http://creativecommons.org/licenses/by-nc-nd/4.0/>).

### Ressecção de tumores da fossa isquiorretal – técnica cirúrgica

#### RESUMO

Tumores primários da fossa isquiorretal são raros, e podem ser congênitos, adquiridos, ou neoplásicos. Com frequência não é possível o estabelecimento de um diagnóstico preciso no pré-operatório, e estudos imaginológicos, como a tomografia computadorizada e, em especial, as imagens por ressonância magnética, podem definir as dimensões e relações anatômicas das lesões. O tratamento cirúrgico é tarefa desafiadora, em decorrência do difícil acesso à região, que, de preferência, se faz por uma abordagem posterior. Descrevemos a etiologia, diagnóstico e técnica operatória de tumores da fossa isquiorretal.

© 2016 Sociedade Brasileira de Coloproctologia. Publicado por Elsevier Editora Ltda. Este é um artigo Open Access sob uma licença CC BY-NC-ND (<http://creativecommons.org/licenses/by-nc-nd/4.0/>).

#### Palavras-chave:

Tumores da fossa isquiorretal

Neoplasias

Tumores fibrosos solitários

\* Corresponding author.

E-mails: [eduardoalvesfh@hotmail.com](mailto:eduardoalvesfh@hotmail.com), [contato@coloproctologiahp.com.br](mailto:contato@coloproctologiahp.com.br) (E.F.A. Filho).

<http://dx.doi.org/10.1016/j.jcol.2016.04.006>

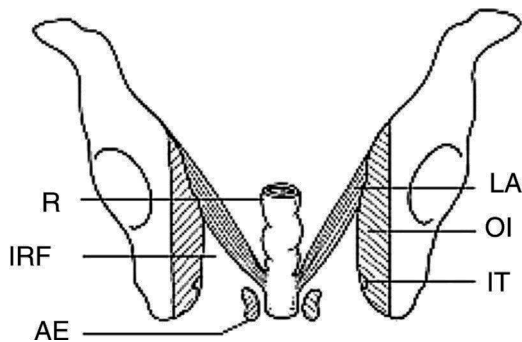
2237-9363/© 2016 Sociedade Brasileira de Coloproctologia. Published by Elsevier Editora Ltda. This is an open access article under the CC BY-NC-ND license (<http://creativecommons.org/licenses/by-nc-nd/4.0/>).

**Introduction**

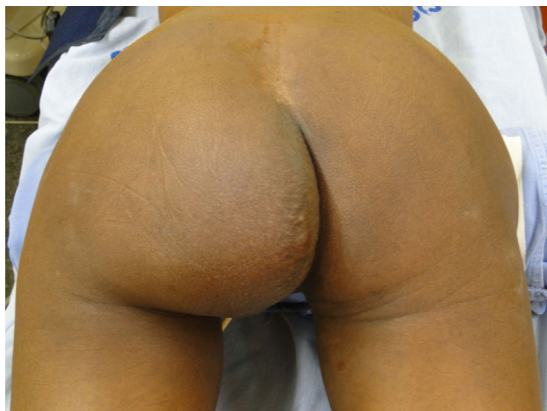
Primary neoplasms of the ischiorectal fossa (IRF) are uncommon and tumors of this region usually result from invasion of adjacent tumors as prostate, anus, rectum, or pelvic bone tumors. Imaging studies such as computed tomography (CT) and magnetic resonance imaging (MRI) can evaluate the size, location and relationship of the tumor and adjacent structures, but not always is possible to suggest precisely the nature of the lesion.<sup>1</sup> The treatment is the surgical excision of the tumor.<sup>2</sup>

The ischiorectal fossa (IRF) is the largest space of the anorectal region (Fig. 1), it has a pyramidal shape and both communicate posteriorly through the post anal deep space, between the levator ani and the anococcygeus ligament. The IRF relates medially with the rectum, the levator ani and the external anal sphincter and anteriorly with the superficial and deep transverse perineal muscle. The obturator internus define the lateral margin; the IRF is bounded inferiorly by the perineal skin. Cranially the levator ani separate IRF of the superelevator space. The IRF contains adipose tissue, nerves, vessels and lymph from the vessels and the pudendal nerves.<sup>1</sup>

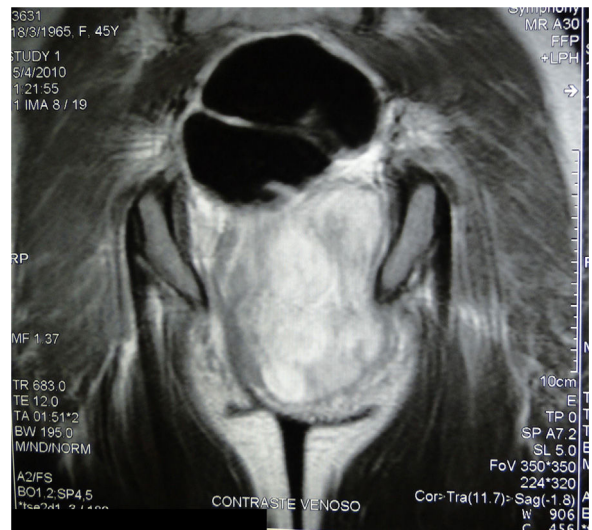Tumors in this region are presented as a perineal, gluteal (Fig. 2), or labial mass. Large lesions that compress the rectum and uro-genital organs can cause symptoms such as



**Fig. 1 – Anatomy of the ischiorectal fossa.**  
**R, rectum; IRF, ischiorectal fossa; AE, anal esphincter; LA, levator ani muscle; OI, obturator internus muscle; IT, ischial tuberosity.**



**Fig. 2 – Bulging left buttock.**

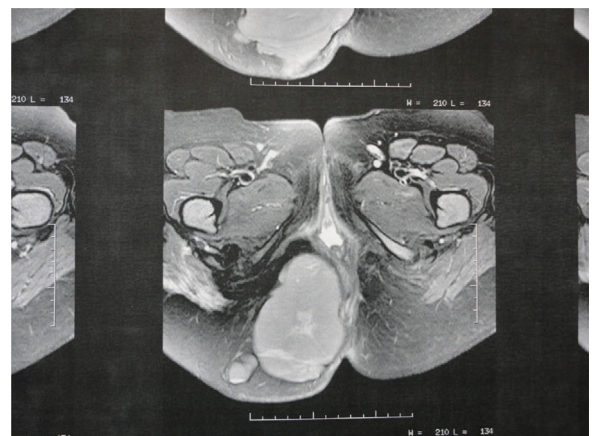

**Fig. 3 – MRI of the pelvis showing a large mass in IRF, compressing the rectum, vagina and the levator ani.**

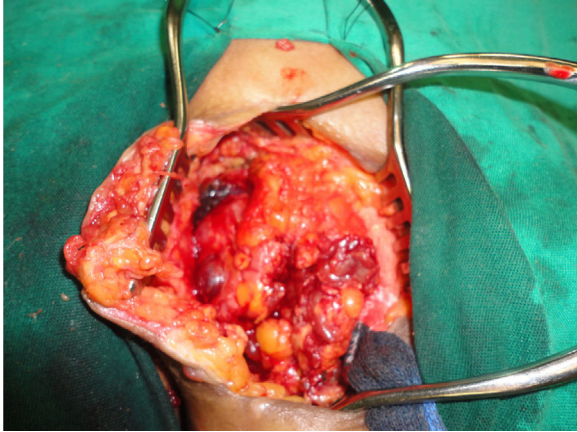
constipation, dispaurenia, dysuria and perineal pain.<sup>3</sup> Infection, rupture and malignant transformation can occur as complications.<sup>3,4</sup>

Primary tumors of the IRF are rare. The clinical diagnosis cannot be done alone because of the depth of the lesions. Imaging exams, particularly MRI can determine the presence of expansive lesions in the region and its anatomical relationships, but the diagnosis can only be done with percutaneous needle biopsies, incisional or excisional biopsy. Results negative for malignancy by needle or incisional biopsy does not rule out the possibility of malignancy. MRI (Fig. 3) is superior to CT (Fig. 4) because it has better resolution with contrast infusion.<sup>1</sup>

The resection of tumors of the IRF is particularly challenging because of the difficulty in accessing through an anterior approach. A posterior approach combined or not with an anterior access is used. Part of the sacrum may have to be removed, especially if the tumor is large and extend to the other IRF.<sup>2</sup> Amputation of the rectum is required when there is invasion of the rectum.<sup>2</sup>



**Fig. 4 – CT of the pelvis showing a tumor occupying the IRF.**



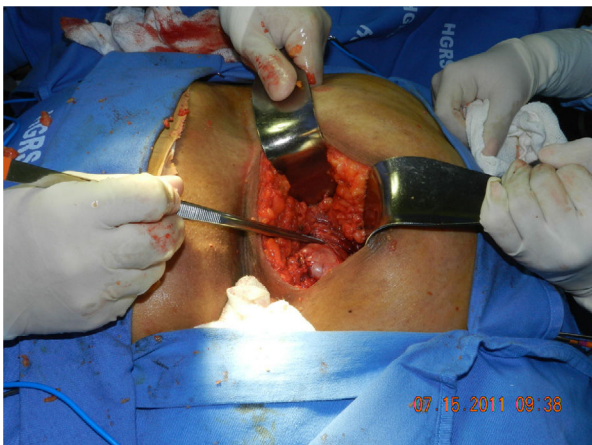**Fig. 5 – Dissection from the subcutaneous tissue to the level of the gluteal muscles.**

The histological diagnosis of tumors of the IRF depends on their embryological origin. They can be congenital, acquired or neoplastic.

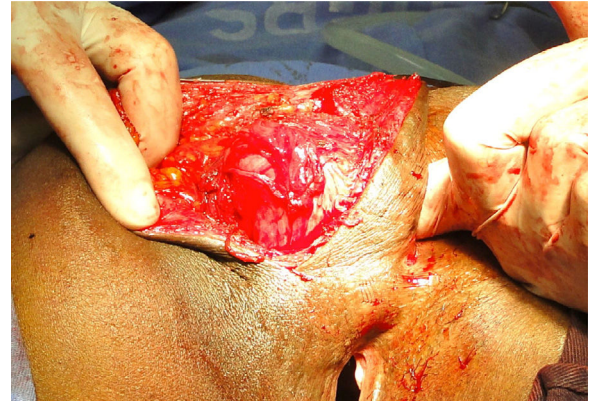The purpose of this study describes the surgical technique of resections of tumors of the IRF and their etiology.

## Material

Operative technique: “jack knife” prone position, stretch of buttocks: (1) vertical para-sacral incision and dissection from the subcutaneous tissue to the level of the gluteal muscles (Fig. 5); (2) identification of the bottom edge of the tumor and the ischial tuberosity, section of the sacrotuberous ligament and release of the tumor from the gluteus maximus (Fig. 6) or its resection if there is invasion of the muscle; (3) if necessary the lower part of sacrum can be resected but only below S3 level to preserve the root of pudendal nerve; (4) medial and cranial dissection with release of the rectum (Fig. 7), the anal sphincter and the levator ani from the tumor; (5) closing the wound by plans and drainage of the region with suctor drain (Fig. 8).



**Fig. 6 – Release of the tumor from gluteus maximus.**



**Fig. 7 – Release of the rectum.**

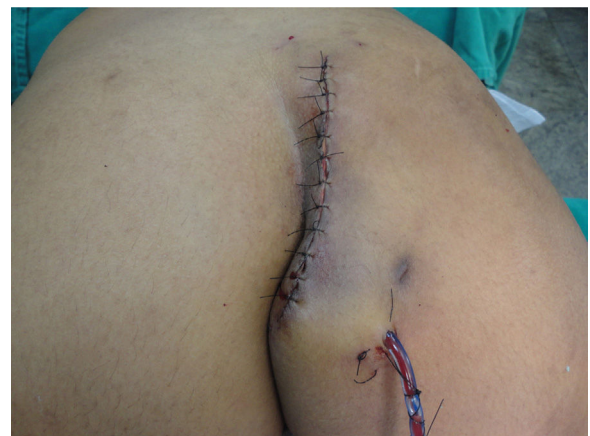## Discussion

### Congenital tumors

Gardner’s duct cysts are common in vagina, resulting from incomplete regression of Wolffian ducts. Large cysts can extend to the IRF. Histologically they have coated or cuboidal columnar epithelium. On MRI the lesion shows high signal intensity and CT attenuation of a signal similar to water.<sup>1</sup>

Giant epidermal cyst is characterized from the radiological point of view by homogeneous, unilocular cystic lesion, well demarcated, histologically are composed of keratin squamous epithelial cells. The characteristics of the cysts on MRI are similar to epidermal cysts of Gardner’s duct. It has no malignant potential described.<sup>1,3</sup>

Tailgut cyst is an hamartoma, due to the incomplete regression of embryonic structures of the anus. It usually occurs in the retro-rectal space but can extend to the IRF. Usually there is a history of diagnosis and treatment of anorectal abscesses and fistulas. CT scan shows a well-defined solid or liquid mass in the retro-rectal space, without invasion of adjacent structures. Differential diagnosis is made with chordomas, teratomas, rectal duplication and meningomyelocele. There is potential for malignancy.<sup>1</sup>



**Fig. 8 – Closure and drainage of the wound.**

Rectal duplication cysts are also unilocular on MRI, but are attached to the digestive tract, as well as the Tailgut cysts they also have malignant potential.<sup>1</sup> These tumors must be differentiated from giant epidermal cysts. Extramucosal anal adenocarcinoma is extremely rare, its origin is unknown and may derive from anal glands, sebaceous cells or aberrant sudoripids glands.

### Neoplasms

Solitary fibrous tumors (SFT) are rare mesenchymal neoplasms in adults. They are more common in the pleura, but also were diagnosed in the lung, retroperitoneum, peritoneum, pelvis, presacral region and liver.<sup>4</sup> There is little literature on the SFT and only one report of involvement of the IRF.<sup>2</sup> Case reports of SFT in other regions, which followed patients for up to 41 months showed less aggressive behavior, even when there are histological features of malignancy (EMA, S 100 protein, desmin, epithelial membrane antigen and neurofilament) showed no recurrences or metastasis.<sup>3,4</sup> The importance of recognizing these tumors should be in its differentiation from more aggressive tumors as liposarcoma.<sup>4</sup>

Lipomas on CT appear as lesions with signal similar to subcutaneous tissue. Large septated tumors are indistinguishable from low-grade liposarcomas.<sup>1</sup>

Aggressive angiomyxoma occurs most commonly in young women, affecting soft tissues such as the pelvis, perineum, buttocks, vulva, retroperitoneum and inguinal regions, secondary involvement of the IRF is common. On CT there is a hypo or isoattenuating sign.<sup>1</sup> They have a gelatinous appearance and are locally invasive.<sup>5</sup>

Malignant peripheral nerve sheath often exhibits areas of benign appearance indistinguishable from fibromatosis. One feature is that such tumors can also be focal, explaining the original diagnosis errors. They are highly aggressive and difficult to handle. Systemic spread is often the ultimate cause of death, although inoperable disease is also common.<sup>6</sup>

Trichilemmal proliferative tumor (TPT) is a tumor that develops from the outer sheath cells or follicular usually after trauma or inflammation. This tumor has a slow evolution and occurs in 90% of the time on the scalp, more rarely other sites have been reported (trunk, face, pubic area, vulva, members...). They can be large and malignant transformation is rare.<sup>7</sup> The immuno-histochemical study is an aid to diagnosis of malignancy of TPT and the differential diagnosis must be done with squamous cell carcinoma. CD34, a marker of differentiation of hair is weakly positive in malignant TPT and negative in squamous cell carcinoma.

Plexiform neurofibroma is pathognomonic of Von Recklinghausen syndrome, characterized by diffuse growth of Schwann cells along the nerves affected first. It is most commonly seen in the extremities, mediastinum, neck and pelvis. Involvement of the pudendal nerve can occur with multiple masses of variable size with low attenuation at CT.

Malignant histiocytoma can also occur in the IRF and depend on location can be accessed by other routes of

as vaginal access.<sup>8</sup> Immuno-histochemistry demonstrates that tumor cells are positive for vimentin and negative for cytokeratin, desmin, protein S-100, lobes, c-kit and CD34. Adjuvant treatment with radiotherapy may be necessary.<sup>8</sup>

Sarcomas that occur in the perineum can be classified as superficial and deep depending on their position in relation to the muscular fascia.<sup>9</sup> Tumors higher can invade the rectum and the sphincter.<sup>10</sup> They are very aggressive and recurrence and metastases are common, in these cases chemotherapy and radiotherapy may be used but with poor results. The prognosis is worse in tumors in the deep surface.<sup>9</sup>

### Other IRF masses

Abscesses are associated with signs of inflammation and generally arise from adjacent inflammatory and infectious processes, especially from anorectal diseases. In CT and MRI appears as fluid collections with enhancement of the capsule in contrast phase. Other signs include cellulitis and edema characterized by increased attenuation of ischiorectal fat, gas and obliteration of adjacent tissues. Hematomas are caused by local trauma, acute lesions show up on CT as hyper attenuating lesions with fluid levels and chronic lesions with low attenuation and can be mistaken for abscesses.<sup>1</sup>

### Conclusion

Neoplasms occurring in the IRF must be treated taking into account the anatomy of the region. The preferable route of access is posterior, and may require partial resection of the sacrum. The definitive diagnosis can only happen with complete resection of the tumor and its subsequent pathological study

### Conflicts of interest

The authors declare no conflicts of interest.

### REFERENCES

1. Llauger J, Palmer J, Pérez C, Monill J, Ribé J, Moreno A. Normal and pathologic ischiorectal fossa at CT and MR imaging. *Radiographics*. 1998;18:61-82.
2. Miller M, Kulaylat MN, Ferrario T, Karakousis CP. Resection of tumors of the ischiorectal fossa. *J Am Coll Surg*. 2003;196:328-32.
3. Ng SSM, Hon SSF, Wong JHM, Lee JFY. Radiology for the surgeon. Soft-tissue case 59. *Can J Surg*. 2006;49:435-6.
4. Yap T, Hamzah L, Oshowo A, Taylor I. Myxoid solitary fibrous tumour of the ischiorectal fossa. *Eur J Surg Oncol*. 2003;29:98-100.
5. Satheshkumar T, Saklani AP, Banerjee D, Jones DR. Angiomyofibrosarcoma: a rare ischiorectal fossa swelling. *Hosp Med*. 2003;64:244-5.
6. Teoh KH. Malignant peripheral nerve sheath tumour in the ischio-rectal fossa. *Colorectal Disease*. 2009;11:533.

- 
7. Makhoulf Z, Verola O, Senejoux A, Duval A, Terris B, Balaton A, et al. Tumeur trichilemmale proliférante de la région ischio-rectale. *Ann Pathol.* 2011;31:316-9.
  8. Stever MR, Hernandez E, Sakas EL. Malignant fibrous histiocytoma of the pelvis. *Gynecol Oncol.* 1988;30:285-90.
  9. Lima MA, Pozzobon BHZ, Fonseca MFM, Horta SHC, Formiga GJS. Leiomiossarcoma Perineal: Relato de Caso e Revisão da Literatura. *Rev Bras Coloproct.* 2010;30:352-5.
  10. Moraes SP, Quilici F, Reis Neto JAR, Resende GMLS, Carcinoni TM. Rbdomiossarcoma pararretal: relato de caso. *Rev Bras Coloproct.* 2002;22:33-5.