



Case Report

Colonic fibromatosis – a case report and review of the literature

Dimitrios Linardoutsos*, Neal Patel, Hitesh Patel

Barts Health NHS Trust, Newham University Hospital, Colorectal Department, London, United Kingdom

ARTICLE INFO

Article history:

Received 18 March 2018

Accepted 3 June 2018

Available online 17 July 2018

Keywords:

Desmoid

Tumour

Colon

ABSTRACT

Intra-abdominal desmoids tumours are very rare and usually occur in patients with familiar adenomatous polyposis and previous surgery. They represent fibroepithelial growths with varied biologic behavior and therefore different prognosis. We report a case of a 60-year-old patient with a large right colonic mass who underwent right hemicolectomy. Histology proved morphological and immuno-histochemical features indicating fibromatosis. This desmoid tumour appeared growing from the colonic wall rather than the mesocolon, confirming a true colonic wall fibromatosis, a deep isolated form of intra-abdominal fibromatosis. Surgical resection is the treatment of choice in isolated well confirmed lesions. Multidisciplinary team approach is crucial for treatment and prognosis.

Crown Copyright © 2018 Published by Elsevier Editora Ltda. on behalf of Sociedade Brasileira de Coloproctologia. This is an open access article under the CC BY-NC-ND license (<http://creativecommons.org/licenses/by-nc-nd/4.0/>).

Fibromatose colônica – relato de caso e revisão da literatura

RESUMO

Os tumores desmoides intra-abdominais são muito raros e geralmente ocorrem em pacientes com polipose adenomatosa familiar e cirurgia prévia. Eles representam crescimentos fibroepiteliais com comportamento biológico variado e, portanto, prognóstico diferente. Relatamos o caso de um paciente de 60 anos com grande massa colônica à direita, submetido a hemicolectomia direita. A histologia demonstrou características morfológicas e imuno-histoquímicas que indicavam fibromatose. Este tumor desmoide surgiu crescendo a partir da parede do cólon, e não do mesocólon, confirmando uma verdadeira fibromatose da parede do cólon, uma forma isolada profunda de fibromatose intra-abdominal. A ressecção cirúrgica é o tratamento de escolha em lesões isoladas bem confirmadas. A abordagem multidisciplinar é crucial para o tratamento e prognóstico.

Crown Copyright © 2018 Publicado por Elsevier Editora Ltda. em nome de Sociedade Brasileira de Coloproctologia. Este é um artigo Open Access sob uma licença CC BY-NC-ND (<http://creativecommons.org/licenses/by-nc-nd/4.0/>).

Palavras-chave:

Desmoide

Tumor

Cólon

* Corresponding author.

E-mail: dlinardoutsos@gmail.com (D. Linardoutsos).

<https://doi.org/10.1016/j.jcol.2018.06.002>

2237-9363/Crown Copyright © 2018 Published by Elsevier Editora Ltda. on behalf of Sociedade Brasileira de Coloproctologia. This is an open access article under the CC BY-NC-ND license (<http://creativecommons.org/licenses/by-nc-nd/4.0/>).

Introduction

A desmoid tumour (DT) is a locally infiltrating and aggressive fibroepithelial proliferation of musculoaponeurotic structures that can occur in any fascia. These types of tumours are quite rare. They account for 0.03% of all neoplasms and 3% of soft tissue tumours. There is a preponderance amongst young female adults aged between 25 and 35 years old.¹ Historically the first report of this type of tumour was in 1832 by McFarlane who reported the case of a mass on the abdominal wall of a young woman after delivery. The term desmoid was given to a similar tumour in 1838, by Muller, describing a growth of fibroepithelial origin.² Desmoid tumours have a highly variant biological behaviour, which determines also the clinical presentation and the prognosis. Lack of metastatic predisposition characterises them as benign tumours. However, aggressive, non-encapsulated and infiltrating tumours, with irregular margins, should be considered as malignant tumours, because of their subsequent behavior.^{1,3} Abdominal desmoid tumours are very common in Familial Adenomatous Fibromatosis (FAP) as part of Gardner's Syndrome, but rarely, they can also be found in isolated form, or sporadic type of the disease.⁴ Desmoid tumours may be classified based on the site of presentation. The most accepted classification defines the disease as (A) abdominal and intra-abdominal (subdivided as fibromatosis of mesenterium and pelvis) and (B) extra-abdominal.⁵

Case report

A 60-year-old male patient presented with a two month history of altered bowel habit and vague abdominal pain. A full colonoscopy was performed and showed a malignant looking polypoid tumour extending from distal ascending colon to the hepatic flexure. The rest of the colon was clear. Biopsies taken at colonoscopy showed fragments of colonic mucosa, with mild architectural distortion and cryptitis with no evidence of dysplasia or malignancy. The abdominal CT scan showed a firm, well-defined 6 cm × 8 cm rounded mass of soft tissue density (Fig. 1). Aside this mass the scan was unremarkable with no evidence of metastases. The tumour was thought to be originating from either the ascending colonic wall or its mesocolon, suggesting possibly a GIST type lesion. In light of the CT scan and findings at colonoscopy, an USS guided biopsy of the lesion was undertaken. Again there was no evidence of necrosis or inflammatory infiltration. Histology for the biopsy showed skeletal muscle fibres as well as fragments of fibro-adipose tissue. Immunohistology showed the cells were strongly positive for B-catenin but negative for DOG1, CD34, CD117, Desmin, AE1/AE3, S100, MNF 116, ALK-1 and BCL2. The above morphological and immuno-histochemically features were indicating fibromatosis, a desmoid type of tumour.

The patient underwent an open right hemi-colectomy with a side to side ileo-colonic anastomosis. A soft, well defined round mass originating from the adjacent mesocolon was

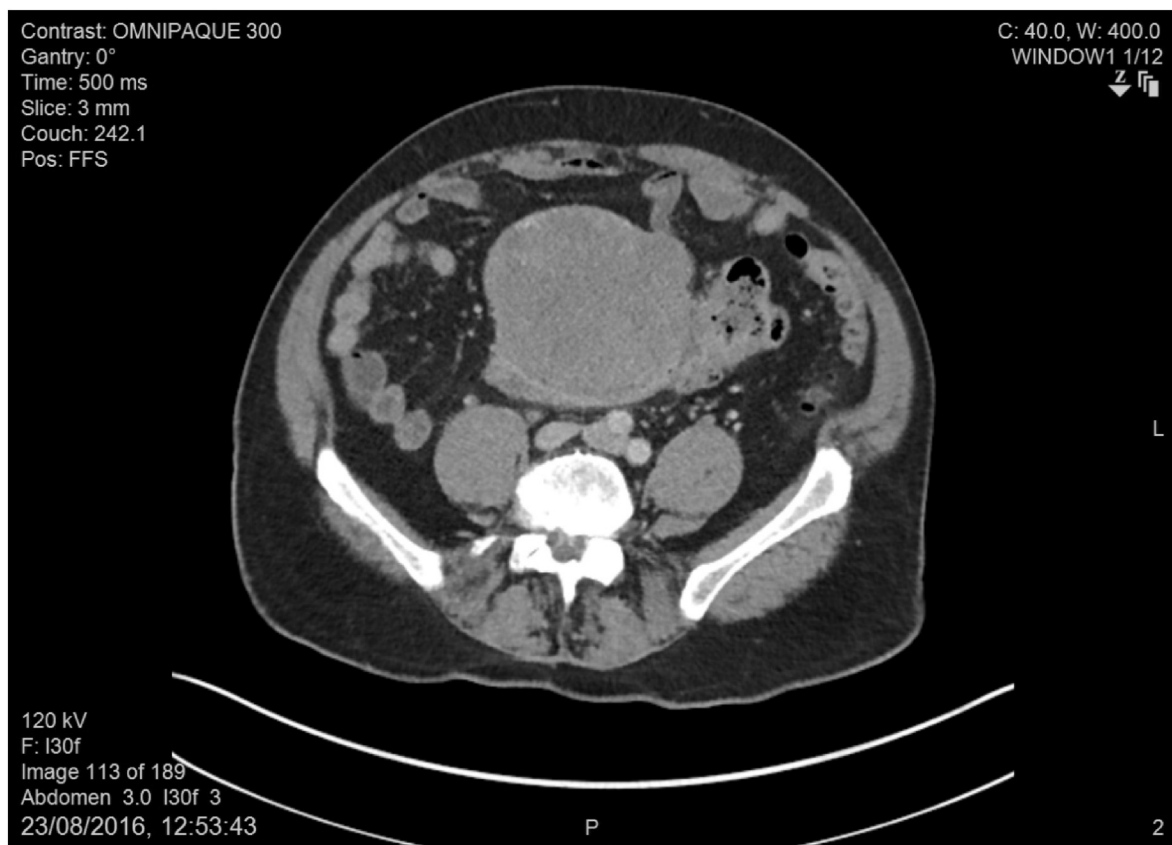


Fig. 1 – CT scan: fibroid tumour arising from colonic wall.

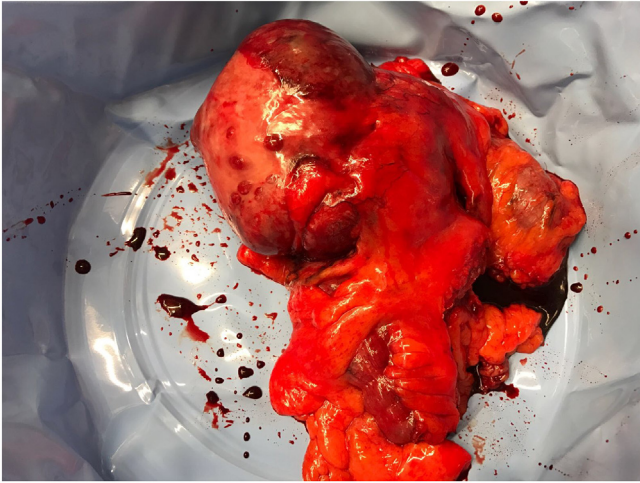

Fig. 2 – Surgical specimen: en block resection, right colon with fibroid tumour anterior view.

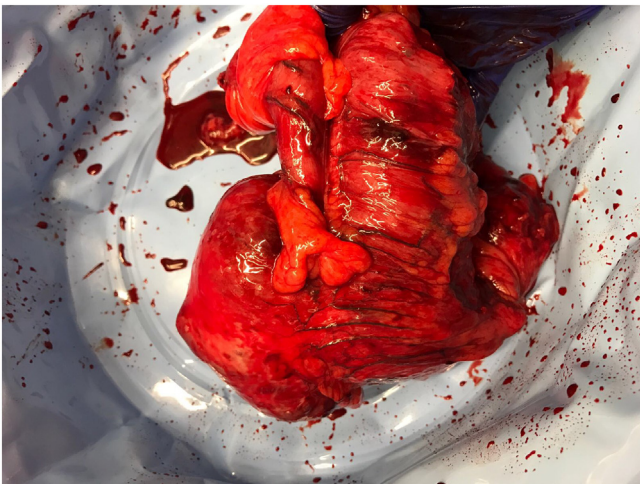


Fig. 3 – Surgical specimen: en block resection, right colon with fibroid tumour posterior view.

found intra-operatively, that was not attached to retroperitoneal or other structures (Figs. 2 and 3). The patient had an uneventful postoperative recovery and was discharged home on the 8th postoperative day. Histopathology of the removed specimen confirmed a spindle cell lesion, centered largely within the colonic muscular propria. The tumour appeared confined to the bowel wall with no obvious invasion through the muscular propria. The lesion bulged to the serosal surface without invading it. No ileal or colonic mucosal abnormality was identified. Focal extension into peri-colic fat was detected. The immuno-histochemical characteristics were similar to the previous specimen derived by USS guided biopsy. The pathology report confirmed a deep isolated form of intra-abdominal fibromatosis. As colonic location of an intra-abdominal fibromatosis is very rare, a second opinion was requested to confirm the diagnosis. Following a multidisciplinary team decision the patient remains under lifelong surgical surveillance. Thus far at 1 year postoperatively the patient remains asymptomatic with no evidence of recurrence.

Discussion

The pathogenesis of desmoid tumours is unknown. Multiple factors have been suggested as contributors to the genesis and growth of these tumours. Significant hormone level changes (e.g. during pregnancy), trauma and previous surgery are thought to be potential triggering factors of the disease.⁶ Genotype and phenotype factors determine the disease in FAP. Microscopically desmoid tumours are known to arise from fibroblasts, and the cells have small and regular nuclei with rare atypical mitosis.⁷⁻⁹ Telomerase length and activity is normal. Their histology pathway is not clear. Macroscopically they are usually encapsulated, varying in regularity of their borders and often, if they are aggressive in nature, infiltrating surrounding muscles. Our case was a form of well capsulated tumor, with no characteristics of local invasion to other organs. It is considered that desmoids are the mature forms of well-defined desmoids looking precursor lesions, as mesenteric fibrosis. The biological transforming factor is not known. The implication of beta catenin has been investigated. In FAP the loss of the APC gene allows the beta catenin to enter the nucleus increasing the cellular component. Beta catenin has been assigned as a histopathological marker of the tumour, distinguishing it from other similar types of lesions.^{7,10} Rhamm protein has also been found in higher expression in desmoid tumours. Rhamm protein has been shown to have a role in neoplastic transformation.¹¹ Immuno-histo-chemistry is also positive for cathepsin D, but negative for oestrogen receptor a, HER2 and progesterone receptor.¹² Immuno-histo-chemistry helps remarkably in distinguishing the nature of the tumor, particularly where there are concerns of mixed type lesions. In our case, endoscopic impression was different from the radiologic and because of the inconclusive endoscopic biopsies; we also proceed for a USS guided biopsy for further assessment of the lesion. Where CT is inconclusive an MRI should be requested urgently particularly in cases of extra-abdominal tumours.¹³⁻¹⁵

The natural history is unpredictable. Church categorised the progression and the prognosis of desmoid tumours in familial adenomatous polyposis into four categories. In his series, 10% of tumours resolved spontaneously, 30% characterised by cycles of progression and resolution, 50% remained stable in size after the diagnosis with an unfortunate 10% having rapid progression.¹⁶

The successful treatment of desmoids tumours requires a multi-disciplinary approach. Surgical excision is a key component. Wide local excision with adequate margins has been the mainstay of treatment for the last 100 years.¹⁷ Traditionally clear margins of 1 cm were attempted and thought to be adequate. The role of clear margins is crucial for reducing the rate of local recurrence of desmoids type fibromatosis.^{18,19} In a recent meta-analysis, for patients treated by surgical resection only, the risk of local recurrence was almost twice higher for those who had positive margins.²⁰ However, other studies have not shown statistic influence of surgical margins in local recurrence of fibromatosis.¹⁵ Tumour location, depth and age are identified as risk factors for local recurrence. Deep fascia tumors and those located in extrem-

ities are more aggressive than superficial tumors and those located in the trunk. However, gender is of not statistical importance.^{21,22}

The role of radiotherapy in desmoid tumours has been evaluated in different studies. For tumours with positive resection margins and those which are un-resectable, adjuvant radiotherapy provides improved recurrence rates in patients with primary and recurrent tumours.^{20,23} Adjuvant radiotherapy after achieving negative margins in surgery has no benefit in recurrence.²³

The relationship of desmoid tumours to hormone changes has led to the use of various medical and hormone therapies in attempt to control the disease. Multiple agents such as tamoxifen, non-steroidal or steroid based anti-inflammatory drugs such as colchicine, interferon and testolactone have been tried. Chemotherapy with doxorubicin, dacarbazine and carboplatin has been showed to offer partial or complete resolution in cases of un-resectable masses. Anthracycline based treatment and methotrexate combined with vinblastine/vinorelbine have been found effective to control the disease.^{24–29}

Novel treatments with targeted therapies have been tried as therapeutic options for progressive desmoid tumours. In a German study Imatinib was found to induce sustained progression arrest in progressive desmoid tumours. Furthermore Nilotinib was shown to have the potential to stabilise desmoid tumour growth after treatment failure with Imatinib.³⁰ The role of Imatinib in treatment and stabilisation of aggressive fibromatosis has been confirmed in multiple studies.^{31,32} Sunitinib, another anti-angiogenic agent has been tried for aggressive fibromatosis with an overall response rate of 26.3%. It has shown to be potentially useful in the management of non-mesenteric desmoid tumours.³³ Pazopanib has also been successfully tried in a case of aggressive fibromatosis, but further studies are needed for evaluation of its role.³⁴ In general, a treatment algorithm should include wide local resection for small isolated tumours, with adequate local margins. For larger abdominal tumours, wide resections with adequate margins are preferable. In case of local recurrence, if further excision is not possible, anti-hormone therapy can be tried first, followed by chemotherapy or radiotherapy for aggressive lesions. Closed follow-up is also needed for all cases.

Conclusion

Colonic fibromatosis is a very rare type of intra-abdominal type of aggressive fibromatosis. Clinical presentation varies and imaging with biopsy is essential to help confirm the diagnosis. As in all desmoid tumours, colonic fibromatosis does not have any metastatic risk; however, these lesions grow enough to cause symptoms. Surgical resection where possible offers the best chance of cure. However, there remains a significant risk of local recurrence. Radiotherapy has a definite role in unresectable or incomplete resections. Targeted therapy plays a role for the control of the disease. Ideally all such patients should be entered into a national registry to improve outcomes.

Conflicts of interest

The authors declare no conflicts of interest.

REFERENCES

1. Grignol VP, Pollock R, Howard JH. Management of desmoids. *Surg Clin N Am*. 2016;96:1015–30.
2. Rampone B, Pedrazzani C, Marrelli D, Pinto E, Roviello F. Updates on abdominal desmoid tumors. *World J Gastroenterol*. 2007;13:5985–8.
3. Kasper B, Ströbel P, Hohenberger P. Desmoid tumors: clinical features and treatment options for advanced disease. *Oncologist*. 2011;16:682–93.
4. Howard JH, Pollock RE. Intra-abdominal and abdominal wall desmoid fibromatosis. *Oncol Ther*. 2016;4:57–72.
5. Weiss SW, Goldblum JR. Benign tumors and tumor-like lesions of synovial tissue. In: Enzinger and Weiss's soft tissue tumors. 4th ed; 2001.
6. Bertario L, Russo A, Sala P, Eboli M, Giarola M, D'amico F, et al. Hereditary Colorectal Tumors Registry. Genotype and phenotype factors as determinants of desmoid tumors in patients with familial adenomatous polyposis. *Int J Cancer*. 2001;95:102–7.
7. Skubitz KM. Biology and treatment of aggressive fibromatosis or desmoid tumor. *Mayo Clin Proc*. 2017;92:947–64.
8. Skubitz KM, Skubitz AP. Gene expression in aggressive fibromatosis. *J Lab Clin Med*. 2004;143:89–98.
9. Mullen JT, DeLaney TF, Rosenberg AE, Le L, Iafrate AJ, Kobayashi W, et al. β -Catenin mutation status and outcomes in sporadic desmoid tumors. *Oncologist*. 2013;18:1043–9.
10. Saito T, Oda Y, Kawaguchi K, Tanaka K, Matsuda S, Tamiya S, et al. Possible association between higher beta-catenin mRNA expression and mutated beta-catenin in sporadic desmoid tumors: real-time semiquantitative assay by TaqMan polymerase chain reaction. *Lab Invest*. 2002;82:97–103.
11. Told C, Poon R. Genetic deletion of receptor for hyaluronan-mediadectin (Rhamm) attenuates the formation of aggressive fibromatosis (desmoid tumor). *Oncogene*. 2003;22:6873–82.
12. Leithner A, Gapp M, Radl R, Pascher A, Krippel P, Leithner K, et al. Immunohistochemical analysis of desmoid tumors. *J Clin Pathol*. 2005;58:1152–6.
13. Braschi-Amirfarzan M, Keraliya AR, Krajewski KM, Tirumani SH, Shinagare AB, Hornick JL, et al. Role of imaging in management of desmoid-type fibromatosis: a primer for radiologists. *Radiographics*. 2016;36:767–82.
14. Pham H, Fessell DP, Femino JE, Sharp S, Jacobson JA, Hayes CW. Sonography and MR imaging of selected benign masses in the ankle and foot. *Am J Roentgenology*. 2003;180:99–107.
15. Sheth PJ, Del Moral S, Wilky BA, Trent JC, Cohen J, Rosenberg AE, et al. Desmoid fibromatosis: MRI features of response to systemic therapy. *Skeletal Radiol*. 2016;45:1365–73.
16. Church JM. Desmoid tumors in patients with familial adenomatous polyposis. *Semi Colon Rectal Surg*. 1995;6:29–32.
17. Fiore M, MacNeill A, Gronchi A, Colombo C. Desmoid type fibromatosis: evolving treatment standards. *Surg Oncol Clin N Am*. 2016;25:803–26.
18. Howard JH, Pollock RE. Intra-abdominal and abdominal wall desmoid fibromatosis. *Oncol Ther*. 2016;4:57–72.
19. Yang F. Radical tumor excision and immediate abdominal wall reconstruction in patients with aggressive neoplasm compromised full thickness lower abdominal wall. *Am J Surg*. 2013;205:15–21.
20. Janssen ML, van Broekhoven DL, Cates JM, Bramer WM, Nuyttens JJ, Gronchi A, et al. Meta-analysis of the influence of

- surgical margin and adjuvant radiotherapy on local recurrence after resection of sporadic dermoid-type fibromatosis. *Br J Surg*. 2017;104:347–57.
21. Machado V, Troncoso S, Mejías L, Idoate MÁ, San-Julián M. Risk factors for local recurrence of fibromatosis. *Rev Esp Cir Ortop Traumatol*. 2017;61:82–7.
 22. Crago AM, Denton B, Salas S, Dufresne A, Mezhir JJ, Hameed M, et al. A prognostic nomogram for prediction of recurrence in desmoid fibromatosis. *Ann Surg*. 2013;258:347–53.
 23. Kriz J, Eich HT, Haverkamp U, Seegenschmiedt MH, Heide J, Bruns F, et al. Radiotherapy is effective for desmoid tumors (aggressive fibromatosis)-long term results of a German multicenter study. *Oncol Res Treat*. 2014;37:255–60.
 24. Hansmann A, Adolph C, Vogel T, Unger A, Moeslein G. High dose tamoxifen and sulindac as first-line treatment for desmoid tumors. *Cancer*. 2004;100:612–20.
 25. de Camargo VP, Keohan ML, D'Adamo DR, Antonescu CR, Brennan MF, Singer S, et al. Clinical outcomes of systemic therapy for patients with deep fibromatosis (desmoid tumor). *Cancer*. 2010;116:2258–65.
 26. Waddell WR, Kirsch WM. Testolactone, sulindac, warfarin and vitamin K for unresectable desmoid tumors. *Am J Surg*. 1991;161:416–21.
 27. Okuno SH, Edmonson JH. Combination chemotherapy for desmoid tumors. *Cancer*. 2003;97:1134–5.
 28. Palassini E, Frezza AM, Mariani L, Lalli L, Colombo C, Fiore M, et al. Long term efficacy of methotrexate plus vinlastine-vinorelbine in a large series of patients affected by desmoid-type fibromatosis. *Cancer J*. 2017;23:86–91.
 29. Garbay D, Le Cesne A, Penel N, Chevreau C, Marec-Berard P, Blay JY, et al. Chemotherapy in patients with desmoid tumors: a study from the French Sarcoma Group (FSG). *Ann Oncol*. 2012;23:182–6.
 30. Kasper B, Gruenwald V, Reichardt P, Bauer S, Rauch G, Limprecht R, et al. Imatinib induces sustained progression arrest in Recist progressive desmoid tumors: Final results of a phase II study of the German Interdisciplinary Sarcoma Group (GISG). *Eur J Cancer*. 2017;76:60–7.
 31. Penel N, LeCesne A. Imatinib for progressive and recurrent aggressive fibromatosis (desmoid tumors): an FNCLCC/French Sarcoma Group phase II trial with a long-term follow-up. *Ann Oncol*. 2011;22:452–7.
 32. Chugh R, Wathen JK, Patel SR, Maki RG, Meyers PA, Schuetze SM, et al. Sarcoma Alliance for Research through Collaboration (SARC). Efficacy of imatinib in aggressive fibromatosis: results of a phase II multicenter Sarcoma Alliance for Research through Collaboration (SARC) trial. *Clin Cancer Res*. 2010;16:4884–91.
 33. Jo JC, Honq YS. A prospective multicenter phase II study of sunitinib in patients with advanced aggressive fibromatosis. *Invest New Drugs*. 2014;32:369–76.
 34. Bulut G, Ozluk A, Erdogan AP, Uslu R, Elmas N, Karaca B. Pazopanib: a novel treatment option for aggressive fibromatosis. *Clin Sarcoma Res*. 2016;6:22.