



Journal of Coloproctology

www.jcol.org.br



Case Report

The use of local anesthesia and sedation in transanal hemorrhoidal dearterialization with Doppler[☆]



Fernanda Bellotti Formiga^{*}, João Carlos Magi, Bruna Fernandes dos Santos, Lucas Rodrigues Boarini, Pietro Dadalto Oliveira, Renata Bandini Vieira, Galdino José Sintonio Formiga

Hospital Heliópolis, Serviço de Coloproctologia, São Paulo, SP, Brazil

ARTICLE INFO

Article history:

Received 9 May 2016

Accepted 2 April 2017

Available online 11 May 2017

Keywords:

Hemorrhoids dearterialization

Local anesthesia

Hemorrhoid

Ambulatory surgery

ABSTRACT

The treatment of hemorrhoidal disease has never been as innovated as in recent decades. The transanal hemorrhoidal dearterialization with Doppler (THD) was described under general anesthesia or spinal blockage and there is no use of local anesthesia reports. This study aims to evaluate the safety of the use of local anesthesia with sedation in THD. For this purpose, two cases are reported describing the technical and safety analysis and results. Both patients were women with grade II and III hemorrhoidal disease. These patients underwent pre-anesthetic sedation with intravenous diazepam, then were positioned in lithotomy and sedated with midazolam and pethidine. The intersphincteric blockage was followed by THD with mucopexy. One patient made a small submucosal hematoma without expansion. The patients were stable and comfortable throughout the procedure. Both were discharged the next day, with regular analgesia. In the seventh postoperative day, both had mild annoyance at constant tenesmus, which was reduced gradually. The cases illustrate that THD is feasible when performed with local anesthesia and sedation, as it is safe and effective. This new technology can be incorporated into services that have a local anesthesia protocol as their standard.

© 2017 Published by Elsevier Editora Ltda. on behalf of Sociedade Brasileira de Coloproctologia. This is an open access article under the CC BY-NC-ND license (<http://creativecommons.org/licenses/by-nc-nd/4.0/>).

[☆] Paper presented as a poster at the III Congresso Paulista de Coloproctologia, São Paulo, April 1, 2016.

^{*} Corresponding author.

E-mail: drafernandaformiga@gmail.com (F.B. Formiga).

<https://doi.org/10.1016/j.jcol.2017.04.004>

2237-9363/© 2017 Published by Elsevier Editora Ltda. on behalf of Sociedade Brasileira de Coloproctologia. This is an open access article under the CC BY-NC-ND license (<http://creativecommons.org/licenses/by-nc-nd/4.0/>).

O uso da anestesia local e sedação na desarterialização hemorroidária transanal com doppler

R E S U M O

Palavras-chave:

Desarterialização hemorroidária
Anestesia local
Hemorróida
Cirurgia ambulatorial

O tratamento da doença hemorroidária nunca foi tão inovado como nas últimas décadas. A desarterialização hemorroidária transanal é uma dessas inovações. Foi originalmente descrita sob anestesia geral ou bloqueio espinal e não há relatos de utilização de anestesia local. Assim, este estudo visa avaliar a segurança do uso da anestesia local com sedação na desarterialização hemorroidária transanal. Para tal, dois casos são relatados com descrição da técnica e análise da segurança e resultados. Ambas pacientes eram mulheres com doença hemorroidária grau II e III. Foram submetidas à indução anestésica, posicionadas em litotomia e sedadas com midazolam e petidina. Realizou-se bloqueio interesfincteriano seguido de desarterialização hemorroidária transanal com doppler associado a mucopexia. Uma das pacientes fez um hematoma submucoso pequeno, sem expansão. As pacientes ficaram estáveis e confortáveis durante todo o procedimento. Ambas receberam alta no dia seguinte, com analgesia habitual. No sétimo dia do pós-operatório, ambas apresentavam incômodo leve pelo tenesmo constante, que foi reduzindo gradualmente. Os casos ilustram que a desarterialização hemorroidária transanal é factível quando realizada com anestesia local e sedação, visto que é segura e eficaz. Esta nova tecnologia pode também ser incorporada aos serviços cujo protocolo de anestesia local seja padrão.

© 2017 Publicado por Elsevier Editora Ltda. em nome de Sociedade Brasileira de Coloproctologia. Este é um artigo Open Access sob uma licença CC BY-NC-ND (<http://creativecommons.org/licenses/by-nc-nd/4.0/>).

Introduction

The treatment of hemorrhoidal disease has never been more innovative than in the last decades. This stems from a better understanding of the pathophysiology of this disease and from the technological acquisition. Among the most modern techniques, mechanical anopexy (PPH[®] or EEA[®]) and transanal hemorrhoidal dearterialization (THD[®] or Minipex[®]) are the most commonly used procedures.

In practice, this has led to an increase in surgical-hospital costs, which should be weighed against the reduction of the great social impact classically raised by resection techniques. In contrast, hemorrhoidectomy has always been inviting for the practice of local anesthesia, with the goal of reducing costs. Several health services defend this anesthetic technique as a standard, which is really interesting, given the Brazilian reality, where anesthetists, beds, and resources are scarce.

Thus, will the acquisition of these new technologies lead to the end of the official surgery with local anesthesia? Will those services where local anesthesia is the medical standard be far from the acquisition of new technologies, by technical restriction?

Objective

To evaluate the safety of the use of local anesthesia with sedation in transanal hemorrhoidal dearterialization (THD) with Doppler.

Method

This is a report of two cases of transanal hemorrhoidal dearterialization with Doppler under local anesthesia and sedation,

in January 2016 at Hospital Heliópolis, São Paulo, with a description of the technique and analysis of safety and results.

Results

Two female patients aged 64 and 68 years, had grade-II and -III hemorrhoidal disease, with complaints of hematochezia, anal discomfort, and prolapse. Both had regular bowel habit and history of ex-smokers and multiparity.

Diazepam 5 mg was administered as a pre-anesthetic medication and, in the operating room, these patients were monitored with cardiac monitor, pulse oximetry and sphygmomanometer, under nebulization of supplemental oxygen. After positioning in lithotomy, the patients were sedated with midazolam 3–5 mg associated with pethidine 20–50 mg. Sedation was accompanied by a surgical team physician (a non-anesthesiologist) and performed according to the patient's systemic response (vital signs and verbal response). Following the protocol, midazolam 2 mg and 20 mg pethidine were started, with the addition of the optimum dose.

After asepsis, antisepsis, and placement of sterile fields, local intersphincteric anesthesia was started with 2% lidocaine 10 mL and a 0.5% bupivacaine (same volume), both without a vasoconstrictor. For this purpose, a 13 mm × 0.45 mm needle was inserted in the posterior medial line and then in the anterior line, to instill 0.5 mL of the solution at each point, with the aim of causing an anesthetic button for subsequent introduction of a larger-caliber needle. Then, a 32 mm × 0.7 mm needle connected to a 20-mL syringe containing the described solution was introduced in a fan-shaped way, at the 45° position toward the ischial tuberosity. Thus, the entire anal circumference is anesthetized with 5 mL of the solution at each point: right and left side initially by the posterior medial region and then by the anterior medial region.

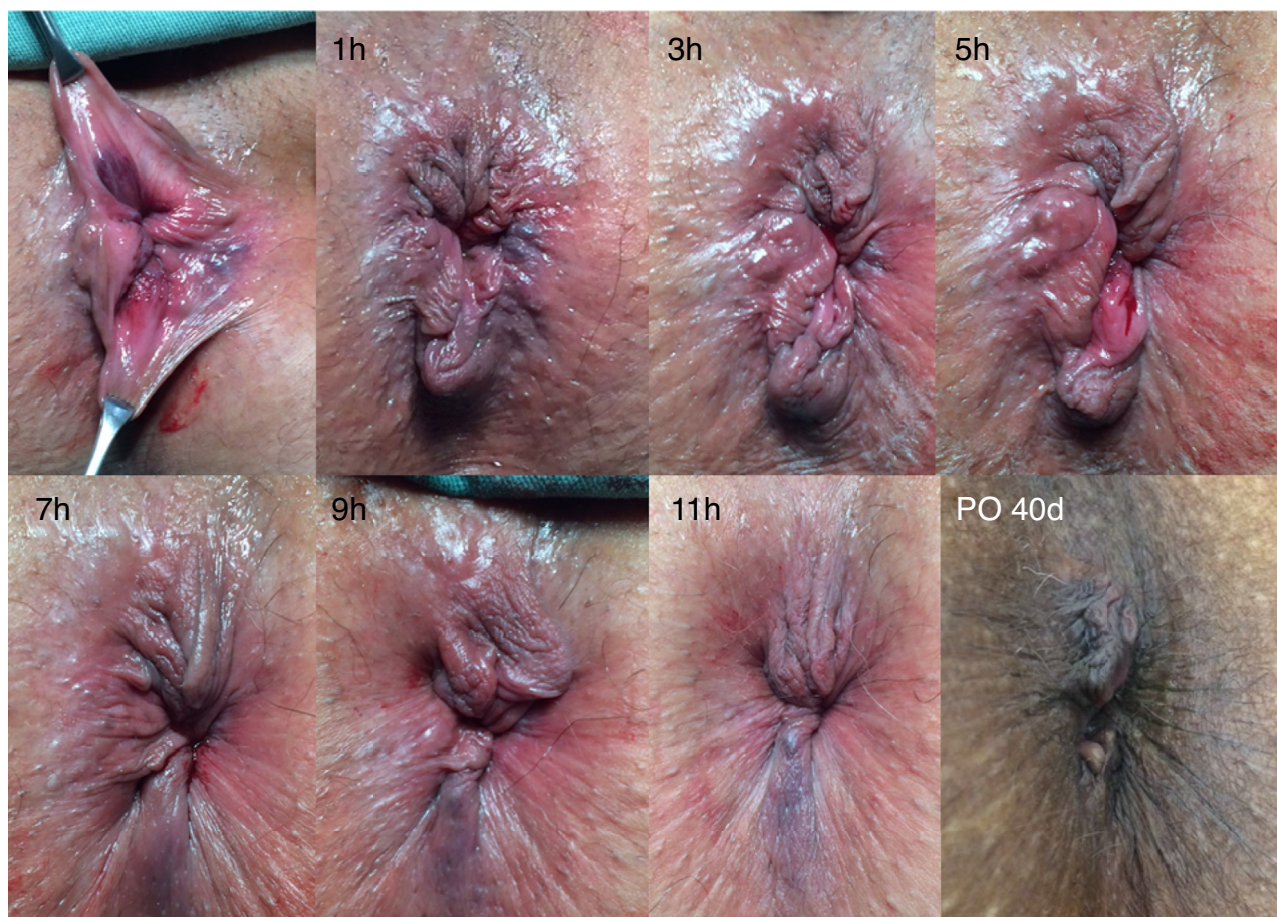


Fig. 1 – Intraoperative and postoperative result of the technique of transanal hemorrhoidal dearterialization. The hours correspond to the point that underwent ligation with mucopexy.

The surgical technique of transanal hemorrhoidal dearterialization was followed according to the standardization by Ratto.¹⁻³ All points of higher Doppler blood flow signal were verified, with a “Z” ligation of the odd locations of the anus, making six fastenings. Then, a continuous suture was applied at each point, in a proximal-distal direction, with fastenings for mucopexy (Fig. 1).

The procedures lasted 55 and 80 min. In the second patient, a small, non-expansile submucosal hematoma occurred at 11 h.

Patients were stable and comfortable throughout the procedure. With 40 min of surgery, the first patient needed more sedation, so that she did not move until the end of the operation, but it did not exceed 5 mg of midazolam.

The next day both patients were discharged, with a usual analgesia protocol (dipyron and diclofenac sodium), in addition to mineral oil. Only one of them complained of a mild tenesmus, without bleeding or pain (both patients had a score of 0 on the visual analog pain scale).

On the seventh postoperative day, the patients presented mild discomfort due to the constant tenesmus. The second patient (that with the submucosal hematoma) had a perianal ecchymosis and no more had tenesmus compared to the other patient. At the surgical site, no infection or thrombosis occurred. On the 15th postoperative day, a mild tenesmus was

informed, and the ecchymosis had disappeared. On the 40th postoperative day, the two patients were asymptomatic and were discharged from the outpatient clinic (Fig. 1).

Discussion

The Coloproctology Service, Hospital Heliópolis, stands out for the adoption of a local anesthesia protocol with sedation since 1995, with an average of 170 procedures per year. Considering the current economic and social Brazilian situation, this protocol is important in our milieu, due to a 50–80% reduction in costs.^{4,5}

The tolerance and safety of local anesthesia with sedation are excellent, with rare and easily managed intercurrents. In the first year of application of this protocol in that Service, in 110 operated patients there was only one case of a complication: a patient with respiratory depression, which was promptly reversed with flumazenil.⁴

Figs. 2 and 3 were reproduced from the original article⁴ and demonstrate the anesthetic technique used. The use of the rectal touch is interesting so that there is no penetration of the intraluminal or submucosal space; however, the touch becomes unnecessary with the surgeon’s acquisition of experience with the technique.

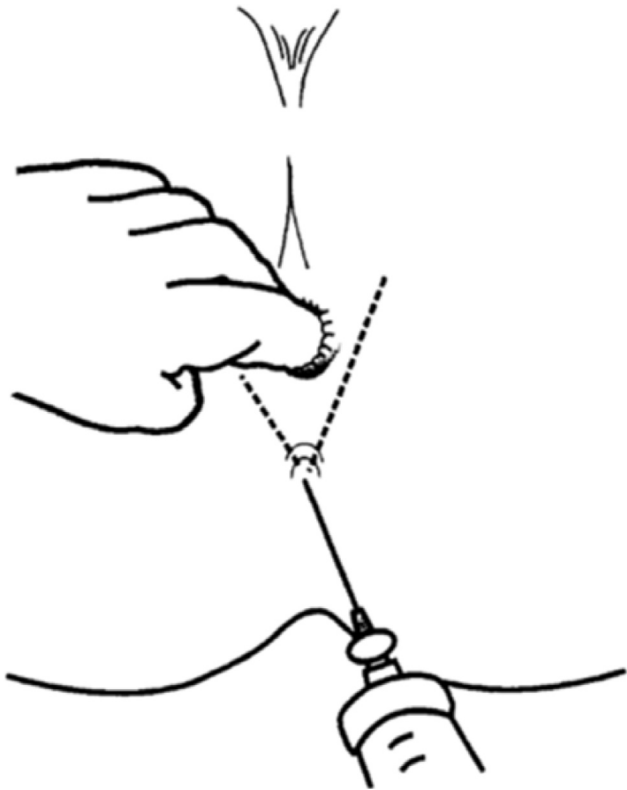


Fig. 2 – Schematic representation illustrating a fan-like infiltration.

Other services also describe their surgeries under local anesthesia as safe, less costly and equally effective procedures.⁵⁻¹¹ Some of these services associate the outpatient protocol with hospital discharge on the same day, which is completely feasible.^{5,6,8-11}

In some cases, local anesthesia without sedation causes an intense pain, reported by patients in the infiltration stage,^{5,6} reaching up to 16.1% of the patients.⁸ Pre-anesthetic and intra-operative sedation brings comfort throughout the surgical act, as well as some degree of postoperative amnesia. In our experience, this situation promotes greater acceptance of the technique by the patients, in spite of the increase in costs, compared to the exclusive use of local anesthesia. Sedation also does not contraindicate the outpatient protocol,¹⁰ since it is a short-term procedure; in addition, the physician may always resort to antagonists.

The surgeon should appropriately adjust his or her patient to the local anesthesia protocol⁸ by assessing his or her ability to understand, age, use of medications, and drug addiction.

Kulkarni et al. conducted a comparative study with 60 patients suffering from simple anorectal diseases, evenly divided into a group that received local anesthesia by intersphincteric, intrasphincteric, and submucosal pudendal/perianal blockage versus a group with spinal anesthesia.¹² These authors found lower urinary retention in the local anesthesia group – 6.7% versus 30%; shorter hospitalization times – 93.3% with local anesthesia were discharged in one day versus 70% with spinal anesthesia; and a similar degree of patient satisfaction was observed between groups.¹² A similar national

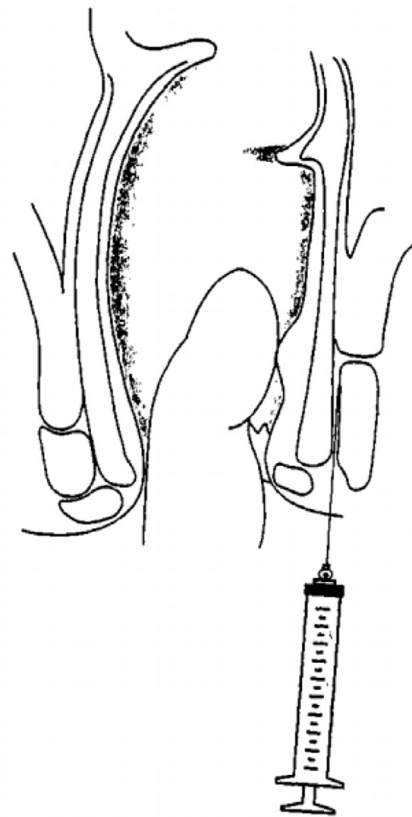


Fig. 3 – Schematic representation, in lateral section, illustrating the intersphincteric infiltration.

study also showed that, in the comparison of pain, bleeding, and urinary retention, urinary retention was the only complication with a significant difference: 2% retention in the local anesthesia (perianal and submucosal) group versus 34% for the group with spinal anesthesia ($p < 0.001$).⁵

The pudendal blockage is also responsible for some cases of urinary retention, unlike the use of the solely intersphincteric blockage¹³; hence our preference for the second option.

Notwithstanding the achievement of an adequate muscle relaxation through local anesthesia,^{9,14} the presence of a retractor into the anal canal may be uncomfortable for the patient, which makes sedation an important option. Hemorrhoidectomies performed with resection techniques such as open, closed, or semi-closed procedures do not use the anoscope throughout the procedure, contrary to what happens in the techniques of mechanical anopexy and transanal hemorrhoidal dearterialization. The latter technique is a more time-consuming method and uses a larger diameter anoscope, compared to commonly used devices (rectal speculum of Pitanga Santos and of Sims, and Hill Fergusson valve). It is evident here the interest of this paper in studying the use of the local anesthesia protocol with sedation specifically in this technique.

Transanal hemorrhoidal dearterialization with Doppler was originally described by Morinaga et al. In 1995,¹⁵ but it was Ratto, who, in recent years, disseminated this technique. The technique is based on a reduction of the arterial flow to the hemorrhoidal tissue, associated or not with a procedure of

mucopexy for repositioning of prolapsed tissue,^{2,3,15,16} which is in line with the two most accepted pathophysiologies of hemorrhoidal disease: hyperflux and prolapse of the hemorrhoidal cushion.^{17–19} For this purpose, an anoscope with a Doppler device at its tip (THD[®]) is used; this instrument pinpoints the largest arterial flow, usually in the six odd positions of the anus. Continuous sutures of the proximal-distal region are applied, with preservation of the pectineal line. At the end of this procedure, a mucopexy is carried out with the ligature of the proximal to the distal suture.

The description of the technique presupposes its completion under general anesthesia or spinal blockage.^{2,3,15,16} Ratto states that the limited locoregional (local) anesthesia does not allow a complete intraoperative analgesia due to the visceral pain induced by the surgical ligation and suture for the mucopexy.² In our experience, sedation is the correct way to dodge visceral pain; for this method, this is an interesting association.

In the long term, the main benefit of this method is the absence of incontinence, because there are no sphincter injury and no hemorrhoidal tissue removal. This was the reason why we selected the two (multiparous) patients described – although both presented an external plicomatous component, the clinical complaint related to prolapse and bleeding.

In the short term, the main benefits of the technique are the obviously lessened pain and a faster healing. The pain is replaced by a transient tenesmus, a nuisance usually well tolerated, as it has been in our patients. The faster healing results in lower social loss and lower costs, with early outpatient discharge. In addition, with the use of this method, there will be a low risk of chronic pain.³

Thus, the two patients were inserted in the local anesthesia/sedation protocol and evaluated for the safety of the technique of dearterialization, since there is no description of this method in the literature.

The more time-consuming manipulation and the dilation by the continuous presence of the anoscope were not unfavorable factors to local anesthesia. Both patients were comfortable and used the standard dose of sedation (midazolam 3–5 mg and pethidine 50 mg). The first patient was uncomfortable after 40 min of the procedure, but the maximum dose of midazolam had not yet been administered. For the second patient, we started with a lower dose at baseline and gradually added the agent until reaching the maximum dose; this strategy made the patient comfortable for an uninterrupted 80-minute period.

The literature describes the use of PPH[®] under local anesthesia,²⁰ but not with THD[®]; hence our interest in reporting our experience.

Final considerations

Transanal hemorrhoidal dearterialization is a feasible technique to be performed with local anesthesia and sedation since it is a safe and effective procedure. Thus, this new technology can also be incorporated into those services that have local anesthesia as their standard protocol.

Conflicts of interest

The two THD[®] kits were donated to the Coloproctology Service, Hospital Heliópolis by Siltace – Produtos Laboratoriais e Hospitalares (www.siltace.com.br).

REFERENCES

- Ratto C, Donisi L, Parello A, Litta F, Doglietto GB. Evaluation of transanal hemorrhoidal dearterialization as a minimally invasive therapeutic approach to hemorrhoids. *Dis Colon Rectum*. 2010;53:803–11.
- Ratto C. THD Doppler procedure for hemorrhoids: the surgical technique. *Tech Coloproctol*. 2014;18:291–8.
- Ratto C, de Parades V. Doppler-guided ligation of hemorrhoidal arteries with mucopexy: a technique for the future. *J Visc Surg*. 2015;152 Suppl 2:S15–21.
- Magi JC, Silva JH, Kock KS, Horta SHC. Anestesia local em cirurgia orifical. *Rev Bras Colo-Proct*. 1996;16:70–3.
- Lacerda-Filho A, Melo JRC. Hemorroidectomia em regime ambulatorial sob anestesia local Estudo prospectivo de 50 casos. *Rev Bras Colo-Proct*. 1995;15:2006–10.
- Buffara VA Jr, Najjar N, Frare RC, Marchesini JB. Cirurgias anais ambulatoriais sob anestesia local. *Rev Bras Colo-Proctol*. 1991;11:67–9.
- Lacerda-Filho A, Cunha-Melo JR. Outpatient hemorrhoidectomy under local anaesthesia. *Eur J Surg*. 1997;163:935–40.
- Sobrado CW, Bringel RW, Nahas SC, da Silva JH, Habr-Gama A. Ambulatory anorectal surgery under local anesthesia: analysis of 351 procedures. *Rev Hosp Clin Fac Med Sao Paulo*. 1998;53:277–82.
- Capelhuchnik P, Ju LY, Carvalho F, Ojeda CV, Bin FC, Klug WA. Hemorroidectomia ambulatorial com bloqueio da fossa isquiorretal com lidocaína e/ou morfina. *Rev Bras Coloproctol*. 2002;22:77–81.
- Haveran LA, Sturrock PR, Sun MY, McDade J, Singla S, Paterson CA, et al. Simple harmonic scalpel hemorrhoidectomy utilizing local anesthesia combined with intravenous sedation: a safe and rapid alternative to conventional hemorrhoidectomy. *Int J Colorectal Dis*. 2007;22:801–6.
- Aphinives P. Perianal block for ambulatory hemorrhoidectomy, an easy technique for general surgeon. *J Med Assoc Thai*. 2009;92:195–7.
- Kulkarni SV, Agarwal P, Nagraj K. To compare the outcome of minor anorectal surgeries under local anesthesia versus spinal anesthesia. *Indian J Surg*. 2014;76:343–434.
- Bansal H, Jenaw RK, Mandia R, Yadav R. How to do open hemorrhoidectomy under local anesthesia and its comparison with spinal anesthesia. *Indian J Surg*. 2012;74:330–3.
- Foo E, Sim R, Med M, Lim HY, Chan STF, Ng BK. Ambulatory anorectal surgery – is it feasible locally. *Ann Acad Med Singapore*. 1998;27:512–4.
- Morinaga K, Hasuda K, Ikeda T. A novel therapy for internal hemorrhoids: ligation of the hemorrhoidal artery with a newly devised instrument (moricorn) in conjunction with a Doppler flowmeter. *Am J Gastroenterol*. 1995;90:610–3.
- Gomez-Rosado JC, Sanchez-Ramirez M, Capitan-Morales LC, Valdes-Hernandez J, Reyes-Diaz ML, Cintas-Catena J, et al. Resultados a un año tras desarterialización hemorroidal guiada por doppler. *Cir Esp*. 2012;90:513–7.

17. Haas PA, Fox TA Jr, Haas GP. The pathogenesis of hemorrhoids. *Dis Colon Rectum*. 1984;27:442-50.
18. Aigner F, Bodner G, Gruber H. The vascular nature of hemorrhoids. *J Gastrointest Surg*. 2006;10:1044-50.
19. Aigner F, Gruber H, Conrad F. Revised morphology and hemodynamics of the anorectal vascular plexus: impact on the course of hemorrhoidal disease. *Int J Colorectal Dis*. 2009;24:105-13.
20. Cosenza UM, Masoni L, Conte S, Simone M, Nigri G, Mari FS, et al. Stapled hemorrhoidopexy as a day-surgery procedure. *Am Surg*. 2011;77:552-6.