

Perianal Psoriasis as the First Manifestation of the Disease

Claudia Alejandra Aceves Quintero¹  Miguel Angel Rosado Martínez² 

¹Hospital Ángeles Pedregal, Mexico City, Mexico

²Hospital Faro del Mayab, Mérida, Yucatán, Mexico

J Coloproctol 2022;42(4):345–347.

Address for correspondence Claudia Alejandra Aceves Quintero, M.D., Hospital Ángeles Pedregal, Camino Santa Teresa 1055, Col. Héroes de Padierna. 10710. Mexico city, Mexico (e-mail: dra.acevesq@gmail.com).

Abstract

Introduction Inverse psoriasis affects the skin of flexural areas, such as the groin, axillae, umbilicus, intergluteal fold, and external genitalia.

Clinical Case We herein report the case of a man who presented with anal pruritus and, upon physical examination, a perianal dermatosis was found, which was characterized by erythematous plaques, with fine scaling. The case was initially managed with zinc oxide, and when no improvement was observed, we decided to take an incisional biopsy, which indicated histological changes suggestive of psoriasiform dermatitis.

Discussion Inverse psoriasis affects 3% to 7% of patients with psoriasis, and it manifests with erythematous plaques without the classic scaling appearance. The skin in these areas is susceptible to maceration, irritation, and ulceration, which alter the classic clinical picture. It may present with typical lesions or, less frequently, in isolation in the anogenital region. In the anogenital presentation only, the diagnosis should be made by biopsy, looking for the classic histopathological features of psoriasis. As for the first-line treatment, low- or medium-potency topical steroids are used for short periods of time; the second-line treatment is with emollients and tar-based products; and the third-line treatment uses an immunomodulator.

Conclusion This presentation is infrequent, and it requires a high index of suspicion for the diagnosis, always supported by biopsies, in search of the classic histopathological features of psoriasis.

Keywords

- ▶ perianal psoriasis
- ▶ inverse psoriasis
- ▶ perianal pruritus

Introduction

Psoriasis is a chronic inflammatory dermatosis that affects approximately 1% to 3% of the population, and it manifests with erythematous plaques with scaling. It commonly affects

the elbows, knees, scalp, and, less frequently, the skin of the face, palms, soles; when it affects intertriginous regions (21–30%), it is known as “inverse psoriasis”, a rare form of presentation in flexural areas, such as the groin, axillae, umbilicus, intergluteal fold and external genitalia.

received

August 21, 2022

accepted after revision

October 25, 2022

DOI <https://doi.org/>

10.1055/s-0042-1759681.

ISSN 2237-9363.

© 2022. Sociedade Brasileira de Coloproctologia. All rights reserved.

This is an open access article published by Thieme under the terms of the Creative Commons Attribution-NonDerivative-NonCommercial-License, permitting copying and reproduction so long as the original work is given appropriate credit. Contents may not be used for commercial purposes, or adapted, remixed, transformed or built upon. (<https://creativecommons.org/licenses/by-nc-nd/4.0/>)

Thieme Revinter Publicações Ltda., Rua do Matoso 170, Rio de Janeiro, RJ, CEP 20270-135, Brazil

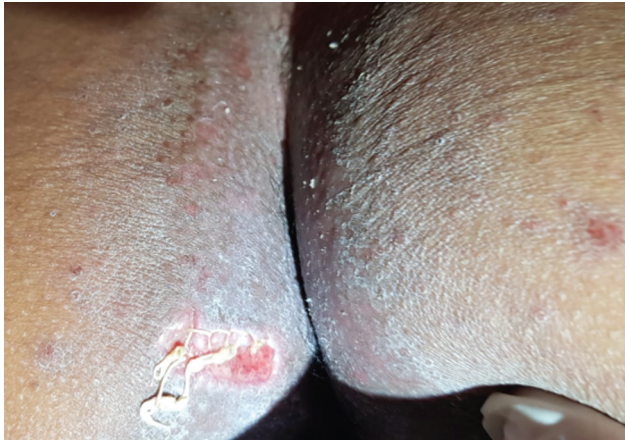

Image 1 Perianal dermatosis characterized by erythematous plaques with fine scaling.

Clinical Case

We herein report the case of a 38-year-old male patient who presented to the clinic referring intense anal pruritus of sudden onset, for which he applied zinc oxide ointment by self-prescription.

The patient had no past medical history, he referred 3 to 4 bowel movements a day, had a score of 4 to 5 on the Bristol stool chart, without bleeding, with water intake around 1 L every day, and abundant intake of fats and dairy products. He reported a feeling of wetness around the anus during the day.

The physical examination revealed a dirty anus with perianal dermatosis limited to the anal verge, characterized by erythematous plaques, with fine scaling, extending towards the anal canal, moist and friable skin (**Image 1**). The rectal examination and anoscopy were normal.

Topical treatment was administered with zinc oxide every 12 hours and changes in hygienic-dietary habits were suggested.

When the patient returned for a check-up after 3 weeks, he reported not having ingested irritants, fats, and drinking more than 2L of water per day. The physical examination revealed localized dermatosis of the perianal skin characterized by erythematous skin with fine scales. As there was no improvement with the treatment, we decided to take an

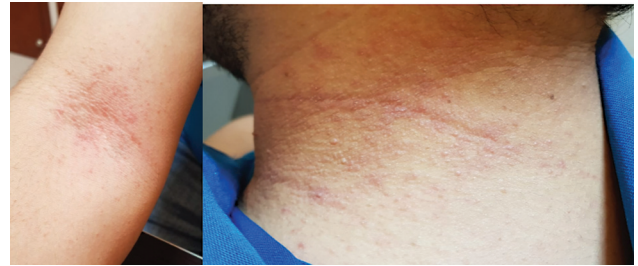

Image 3 Erythematous plaques with fine, pruritic scaling on the neck (right) and ulnar fossae (left).

incisional biopsy of the perineal skin, which indicated histological changes suggestive of psoriasiform dermatitis (**Image 2**).

Upon detailed physical examination, the patient was found to have erythematous plaques with fine, pruritic scaling on the neck and ulnar fossae (**Image 3**).

Discussion

Inverse psoriasis affects approximately 3% to 7% of patients with psoriasis, and it manifests with well-demarcated erythematous plaques without the classic appearance of desquamation and with a shiny aspect, which is why the diagnosis is often overlooked.

The characteristics of these specific skin areas, make them susceptible to maceration, irritation, and ulceration, and the absence of desquamation alters the classic clinical picture and causes symptoms such as pruritus, irritation, and pain. It may occur in conjunction with typical lesions in areas of extension or, less frequently, in isolation in the anogenital region in 2% to 5% of the patients.^{1,2}

Dermoscopy is an excellent diagnostic tool, especially when the disease presents in unusual anatomical areas, for it enables the finding of whitish scales with punctate vessels and tortuous capillaries with uniform distribution on an erythematous base. In the case of manifestations only in the anogenital region, the diagnosis should be made by biopsy, looking for the classic histopathological features of psoriasis, such as epidermal hyperplasia, acanthosis, hypogranulosis, hyperkeratosis, parakeratosis, and, in some cases, collections of Munro-Sabouraud neutrophils and Kogoj micropustules.²⁻⁴

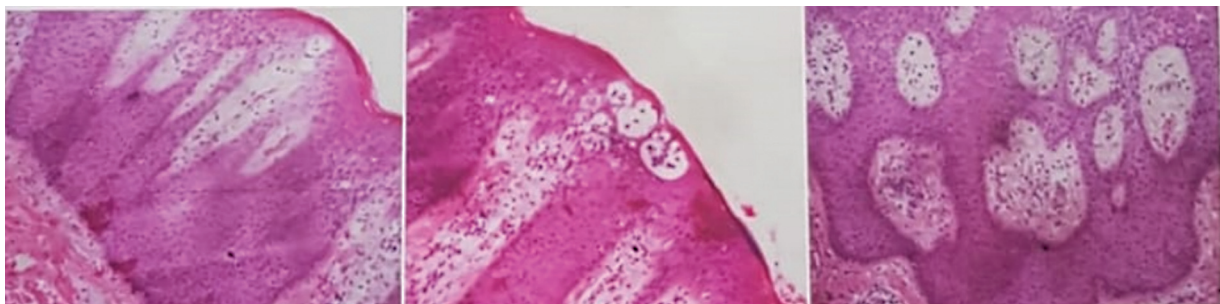


Image 2 Stratified flat epithelium with connected interpapillary ridges, with intraepidermal inflammatory infiltrate, with formation of Munro microabscesses.

Treatment is challenging because there is greater absorption of steroids and alcohol in this area, which can lead to adverse reactions. Topical agents are recommended as first-line, with short course of steroids (two to four weeks). The second-line treatment consists of emollients and tar-based products, and the third-line treatment involves immunomodulators, which have yielded good long-term results. In severe cases resistant to the topical treatment, the systemic treatment (with methotrexate, cyclosporine, biologic agents) can be considered; however, they often have a negative impact on quality of life and are not recommended in cases of isolated inverse psoriasis.^{1,2}

Conclusion

This presentation of psoriasis is quite infrequent, so it requires a high index of suspicion when encountering a patient with this type of manifestations and without a history suggestive of the diagnosis. We must rely on biopsies,

looking for the classic histopathological characteristics of psoriasis, to reach the diagnosis and to be able to provide an adequate treatment.

Conflict of Interests

The authors have no conflict of interests to declare.

References

- 1 Dopytalska K, Sobolewski P, Błaszczak A, Szymańska E, Walecka I. Psoriasis in special localizations. *Reumatologia* 2018;56(06): 392–398
- 2 Guglielmetti A, Conlledo R, Bedoya J, Ianiszewski F, Correa J. Inverse psoriasis involving genital skin folds: successful therapy with dapsone. *Dermatol Ther (Heidelb)* 2012;2(01):1–9
- 3 Kelly A, Ryan C. Genital psoriasis: impact on quality of life and treatment options. *Am J Clin Dermatol* 2019;20(05):639–646
- 4 Micali G, Verzi AE, Giuffrida G, Panebianco E, Musumeci ML, Lacarrubba F. Inverse psoriasis: from diagnosis to current treatment options. *Clin Cosmet Investig Dermatol* 2019; 12:953–959