



Case Report

Anal canal adenocarcinoma with a late brain metastatic lesion – a case report

Ashraf Imam *, Daniel Gold, Guy Pines , Arie Pelta, Eli Mavor, Efraim Idelevich, Harbi Khalayleh 

Kaplan Medical Center, Rehovot and The Hebrew University, Medical School, Jerusalem, Israel

ARTICLE INFO

Article history:

Received 25 March 2018

Accepted 1 August 2018

Available online 21 August 2018

Keywords:

Anal canal adenocarcinoma

Metastatic disease

Brain metastasis

Palavras-chave:

Adenocarcinoma de canal anal

Doença metastática

Metástase cerebral

ABSTRACT

Herein we present a rare case of anal canal adenocarcinoma manifesting as non-healing perianal abscess that subsequently underwent radiochemotherapy followed by abdominoperineal resection for residual disease. The patient recovered, and a year later presented with a single brain metastasis. The lesion was successfully resected, and the patient is now disease free.

© 2018 Sociedade Brasileira de Coloproctologia. Published by Elsevier Editora Ltda. This is an open access article under the CC BY-NC-ND license (<http://creativecommons.org/licenses/by-nc-nd/4.0/>).

Adenocarcinoma de canal anal com lesão cerebral metastática tardia – um relato de caso

RESUMO

Apresentamos aqui um caso raro de adenocarcinoma de canal anal que se manifesta como abscesso perianal não cicatrizado que subsequentemente foi submetido à radioquimioterapia seguida de ressecção abdominoperineal por detecção de doença residual. O paciente recuperou-se e um ano depois apresentou uma única metástase cerebral. A lesão foi ressecada com sucesso e o paciente agora está livre da doença.

© 2018 Sociedade Brasileira de Coloproctologia. Publicado por Elsevier Editora Ltda. Este é um artigo Open Access sob uma licença CC BY-NC-ND (<http://creativecommons.org/licenses/by-nc-nd/4.0/>).

Introduction

Anal carcinomas are uncommon types of gastrointestinal malignancies. Out of those, adenocarcinomas of the anal canal

are very rarely encountered during the career of any colorectal or general surgeon. There are several proposed predisposition factors that may lead eventually to the development of this condition such as Crohn's disease and anal fistulas.¹ Treatment of anal adenocarcinoma was debated greatly in the past and is not well defined even to date. Abdominoperineal resection (APR), chemotherapy and radiation are previously demonstrated approaches.²

* Corresponding author.

E-mail: ash_imam04@hotmail.com (A. Imam).<https://doi.org/10.1016/j.jcol.2018.08.001>2237-9363/© 2018 Sociedade Brasileira de Coloproctologia. Published by Elsevier Editora Ltda. This is an open access article under the CC BY-NC-ND license (<http://creativecommons.org/licenses/by-nc-nd/4.0/>).

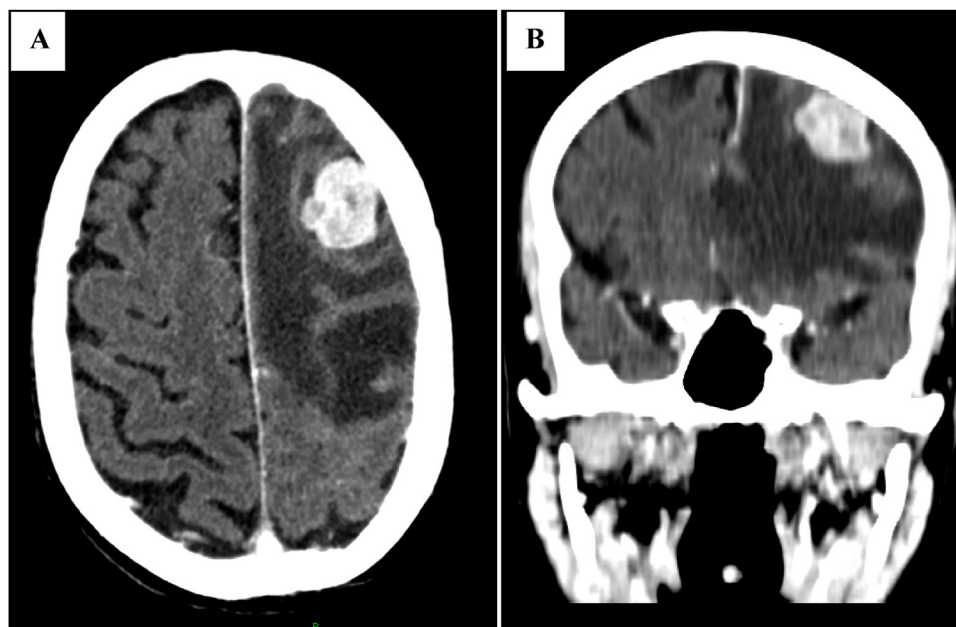


Fig. 1 – Coronal [A] and axial [B] views of the head CT scan demonstrating a single frontal metastatic lesion.

We present a case of a patient who had a non-resolving perianal abscess and fistula and who ultimately was diagnosed with anal canal adenocarcinoma.

Patient description

A 67-year-old male presented to the emergency room complaining of rectal pain of 4 days duration. He is a smoker and his history was significant only for a hemorrhoidectomy in his 20s. A digital rectal examination (DRE) was performed revealing a tender anterior midline bulge with induration and fluctuation suggestive of perianal abscess. Surgery was performed which revealed perianal abscess with a trans-sphincteric fistula. The abscess was drained and two Setons placed in the fistula tract.

On follow-up examinations the patient continued to complain of rectal discomfort and secretions. Lack of fistula healing was observed on examination and an elective fistulotomy was advised. During surgery, a firm bulge is felt in the anal canal next to the fistula tract and biopsies were taken. Pathology was consistent with poorly to moderately differentiated adenocarcinoma. Immunohistochemistry demonstrated positive staining of cytokeratin 7, 20 (CK7, CK20) and CDX2.

Total body computerized tomography (CT) was performed and no systemic involvement was noted. Colonoscopy revealed no synchronous disease. A multidisciplinary meeting was conducted, and a decision was made to treat this tumor with definitive radiochemotherapy as in anal squamous cell carcinoma. No local staging was performed for this reason. Treatment was then initiated with combined Capecitabine based chemo-radiation therapy.

Post treatment CT scan showed complete resolution of the anal mass, but DRE showed a residual ulcer in its previous location. Biopsies from the ulcer's margins and base were pos-

itive for moderately differentiated adenocarcinoma invading the submucosa.

Salvage abdominoperineal resection was performed as next step in management. Surgery revealed no hepatic or peritoneal metastasis and the tumor was completely resected. Patient recovered well and was sent home with a functioning colostomy.

Pathology reports of the specimens from surgery described a 3.8 cm mass invading the Muscularis Propria with clear margins. No lympho-vascular involvement was noted and the 13 regional lymph nodes dissected were free of tumor. Pathological staging was pT2N0. No postoperative treatment was given since the patient underwent definitive radiochemotherapy.

A year later the patient presented to the emergency room with confusion. His family reported that he has slurred speech and progressive weakness for the past two months. On physical examination the patient was drowsy with no focal neurological signs. A head Computerized Tomography (CT) exam was done and a frontal, hypodense, space-occupying lesion was observed (Fig. 1). A magnetic resonance imaging (MRI) demonstrated an enhancing lesion 24 mm × 19 mm in size, surrounded by vasogenic edema and a 6 mm midline shift.

Uncomplicated frontal craniotomy was performed with complete resection of the tumor. Pathology was consistent with metastatic adenocarcinoma of gastrointestinal origin.

3 months post-surgery, patient maintains close follow-ups and is free of tumor as seen in his last positron emission tomography-computed tomography (PET-CT) scan.

Discussion

Anal canal carcinomas are seldom seen in practice, accounting for less than 2% of all gastrointestinal malignancies. Among

those, adenocarcinomas of the anal canal comprise approximately 20% of all anal carcinomas.³

The anal canal is approximately 4 cm long extending from the rectal mucosa at the level of the pelvic floor to the anal verge. The canal is covered with epithelium, either squamous or non-squamous. Distal to the dentate line the canal is lined with squamous mucosa and proximal to it colorectal origin columnar epithelium or either transitional mucosa can be found.^{4,5}

Adenocarcinoma of the anal canal can be sub-classed into two types: (1) colorectal type – arising from anal canal mucosa; (2) extra-mucosal type – arising from anal glands positioned at the level of the dentate line and from fistulae. The extra-mucosal type is rare and hard to detect as it grows intramural and does not invade the overlying mucosa.⁶

Immunohistochemistry is used to help determine the origin of the tumor and to differentiate between the two subtypes of anal adenocarcinoma. Expression patterns of cytokeratin 7 and 20 (CK7, CK20) are of great value in doing so. Previous studies found that anal squamous cell carcinomas are mainly stained CK7–/CK20–, anal adenocarcinomas of colorectal subtype are stained CK7–/CK20+ and adenocarcinomas of extra-mucosal subtype are expressing CK7+ and CK20+/-.^{5,7,8}

Pathogenesis of this malignancy is not entirely clear. Factors such as Crohn's disease, chronic inflammation, HPV infection and a preexisting fistula were hypothesized and studied.^{1,9}

In our case immunohistochemistry staining matched that of the extra-mucosal subtype of anal adenocarcinoma. This result also correlates with the clinical presentation of our patient that started with a non-healing abscess and fistula that revealed a tumor.

Anal canal adenocarcinoma has a poor prognosis, possibly due to late diagnosis of the disease. Five year survival rates vary greatly depending on the stage of disease and choice of treatment, ranging between 30 and 60% and under 5% in advanced disease.^{1,2,10}

Benign anal diseases are very common and may be the first presentation of anal cancer.¹¹ In our case a persistent perianal abscess was the first manifestation of the disease. A situation as this should always sound an alarm as to malignancy possibility. Patients displaying recurrent or non-healing perianal abscesses and fistulas should be sampled for anal cancer and monitored closely.

Unlike anal canal squamous cell carcinoma, adenocarcinoma has no clear management strategy and various approaches were offered. Radiation therapy, chemotherapy, local excision and radical surgeries were all tried. The limited current literature supports the use of multimodality treatment comprised of radical surgery and chemo-radiotherapy.^{1,12} Our case supports concurrent approach. The case presented was treated with definitive RCT with partial response followed by salvage resection. Surgery played a crucial part of treatment.

Adenocarcinoma of the anal canal can spread both hematogenously and through lymphatic structures due to the

anal canal's combined blood supply and lymphatic drainage.⁴ Previous studies documented tumor spread to the lungs, liver, bones, regional nodes and skin.¹ We present an unusual case of which a distant, single, brain metastasis was found with no adjacent structural or lymphatic involvement as seen in surgery, CT and PET-CT scans. This rare presentation is surprising and data of similar cases was not found in the literature. This case implores us to keep a close and tight follow-up of patients after treatment and raises the question of whether adjuvant therapy should be added to reduce recurrence rates.

Conclusion

A high index of suspicion of anal canal adenocarcinoma may be lifesaving and may lead to early diagnosis and better prognosis while treating persistent or atypical benign anal diseases.

Conflicts of interest

The authors declare no conflicts of interest.

REFERENCES

1. Belkacémi Y, Berger C, Poortmans P, Piel G, Zouhair A, Meric JB, et al. Management of primary anal canal adenocarcinoma: a large retrospective study from the Rare Cancer Network. *Int J Radiat Oncol Biol Phys.* 2003;56:1274–83.
2. Anwar S, Welbourn H, Hill J, Sebag-Montefiore D. Adenocarcinoma of the anal canal – a systematic review. *Colorectal Dis.* 2013;15:1481–8.
3. Joon D, Chao M, Ngan S, Joon M, Guiney M. Primary adenocarcinoma of the anus: a retrospective analysis. *Int J Radiat Oncol Biol Phys.* 1999;45:1199–205.
4. Ryan DP, Compton CC, Mayer RJ. Carcinoma of the anal canal. *N Engl J Med.* 2000;342:792–800.
5. Hoff PM, Coudry R, Moniz CM. Pathology of anal cancer. *Surg Oncol Clin N Am.* 2017;26:57–71.
6. Kulkarni MP, Momin YA, Pandav AB, Sulhyan KR. Adenocarcinoma of the anal canal: a report of two cases with review of literature. *Indian J Pathol Microbiol.* 2016;59:404–6.
7. Lisovsky M, Patel K, Cymes K, Chase D, Bhuiya T, Morgenstern N. Immunophenotypic characterization of anal gland carcinoma: loss of p63 and cytokeratin 5/6. *Arch Pathol Lab Med.* 2007;131:1304–11.
8. Hobbs CM, Lowry MA, Owen D, Sobin LH. Anal gland carcinoma. *Cancer.* 2001;92:2045–9.
9. Tarazi R, Nelson RL. Anal adenocarcinoma: a comprehensive review. *Semin Surg Oncol.* 1994;10:235–40.
10. Li LR, Wan DS, Pan ZZ, Zhou ZW, Chen G, Wu XJ, et al. Clinical features and treatment of 49 patients with anal canal adenocarcinoma. *Zhonghua Wei Chang Wai Ke Za Zhi.* 2006;9:402–4.
11. Abel M, Chiu Y, Russell T, Volpe P. Adenocarcinoma of the anal glands. *Dis Colon Rectum.* 1993;36:383–7.
12. Chang G, Gonzalez R, Skibber J, Eng C, Das P, Rodriguez-Bigas M. A twenty-year experience with adenocarcinoma of the anal canal. *Dis Colon Rectum.* 2009;52:1375–80.