

McKittrick Wheelock Syndrome Secondary to Adenocarcinoma of the Rectum. Case Report and Diagnostic Considerations

Claudia Alejandra Aceves Quintero² Santiago Taracena Pacheco¹ Itzel Vela Sarmiento³

¹Department of Internal Medicine, Hospital Angeles Pedregal, Mexico city, México

²Department of General Surgery, Hospital Angeles Pedregal, Mexico city, México

³Department of Surgical Oncology and Robotic Surgery, Hospital Angeles Pedregal, Mexico city, Mexico

Address for correspondence Claudia Alejandra Aceves Quintero, MD, General Surgery resident. Hospital Angeles Pedregal, Mexico City, México (e-mail: dra.acevesq@gmail.com).

J Coloproctol 2023;43(3):e224–e226.

Abstract

Introduction McKittrick-Wheelock syndrome is a rare entity characterized by chronic diarrhea, acute kidney injury, and hydroelectrolytic imbalance associated with a large rectal tumor, frequently a villous adenoma.

Case report A 69-year-old male with chronic diarrhea with mucus. He underwent a colonoscopy with biopsies, reporting adenocarcinoma of the rectum in situ, and underwent a robot assisted intersphincteric resection with colo-anal anastomosis and a protective ileostomy.

Discussion Described in 1954, this syndrome is manifested by electrolyte imbalance and acute renal injury secondary to diarrhea associated with a rectal villous adenoma, often with long lasting symptoms. The most frequent symptom being watery diarrhea with mucus. The definitive treatment consists of surgical resection.

Conclusion Although this is a rare pathology, it should be considered as a differential diagnosis in cases of chronic diarrhea associated with water and electrolyte disorders.

Keywords

- ▶ Villous adenoma
- ▶ watery diarrhea
- ▶ acute kidney injury
- ▶ rectal cancer

Introduction

McKittrick-Wheelock syndrome, described in 1954, is a low incidence entity, benign in most cases, characterized by a secretory villous adenoma accompanied by acute renal injury and hydroelectrolytic imbalance.^{1,2}

Regarding epidemiology, the population usually affected are elderly men, who complain of long lasting watery non-bloody diarrhea with mucus. Patients usually report symptoms of several months of duration, presenting severe hyponatremia and hypokalemia, discovered at the time of the approach. In some cases, patients are hospitalized several times before a diagnosis is reached.

The diagnostic tool of choice is sigmoidoscopy, due to the distal location of these tumors. Abdominal and pelvic CT is useful for surgical planning and to locate the tumor mass in relation to the adnexa. For treatment, complete resection of the causative lesion is sought. Without treatment, mortality can reach 100 %, indicating the importance of radical treatment to improve patient prognosis.^{1,2}

Clinical Case

A 69-year-old male with no medical history of importance came for consultation for having chronic non-bloody diarrhea accompanied by mucus.

received
September 20, 2022
accepted after revision
August 14, 2023

DOI <https://doi.org/10.1055/s-0043-1773781>.
ISSN 2237-9363.

© 2023. Sociedade Brasileira de Coloproctologia. All rights reserved.

This is an open access article published by Thieme under the terms of the Creative Commons Attribution-NonDerivative-NonCommercial-License, permitting copying and reproduction so long as the original work is given appropriate credit. Contents may not be used for commercial purposes, or adapted, remixed, transformed or built upon. (<https://creativecommons.org/licenses/by-nc-nd/4.0/>)

Thieme Revinter Publicações Ltda., Rua do Matoso 170, Rio de Janeiro, RJ, CEP 20270-135, Brazil

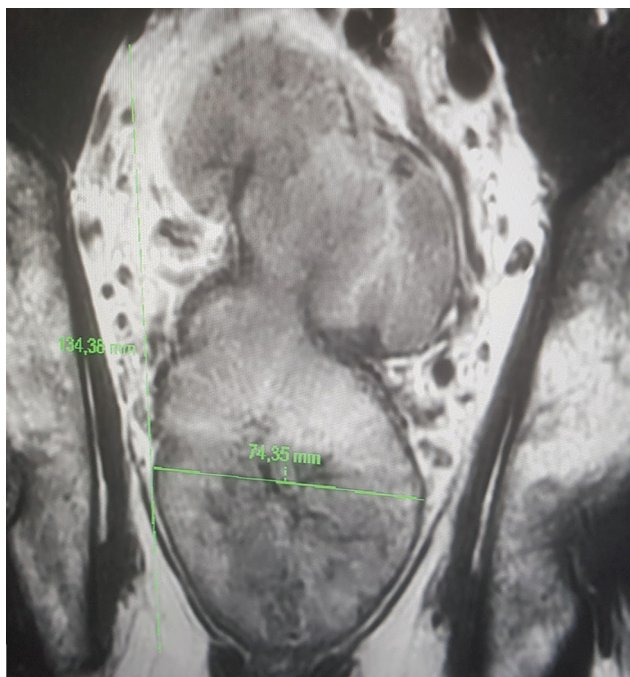


Fig. 1 Magnetic resonance imaging, coronal section. Image suggestive of neoplastic process with diameters of 13.4 × 7.4 cm involving the mucosal, muscular and serous layer.

He underwent a colonoscopy with biopsies taken, in which adenocarcinoma in situ of the rectum was reported. Laboratory studies were taken, showing carcinoembryonic antigen of 9.33 (0.2-5 ng/mL), hemoglobin 18.2 g/dL, hematocrit 53.7%, WBC $14.8 \times 10^3/\mu\text{L}$, neutrophils $10.1 \times 10^3/\mu\text{L}$, lymphocytes $2.3 \times 10^3/\mu\text{L}$, platelets $333 \times 10^3/\mu\text{L}$, glucose 128 mg/dL, urea 65.9 mg/dL, creatinine 1.29 mg/dL, Ca 9.7 mg/dL, P 4.6 mg/dL, Na 127 mg/dL, K 3.7 mg/dL, Cl 88.6 mg/dL.

A magnetic resonance with gadolinium was performed, which reported an image suggestive of a neoplastic process

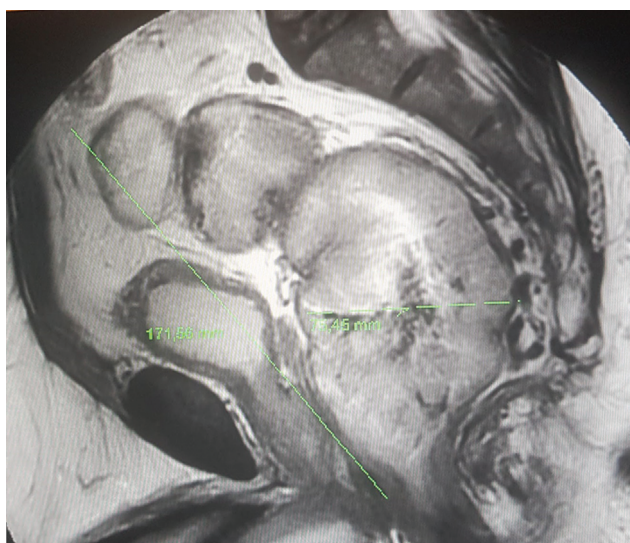


Fig. 2 Magnetic resonance imaging, sagittal view. Image suggestive of neoplastic process of 17.1 × 7.5 cm.

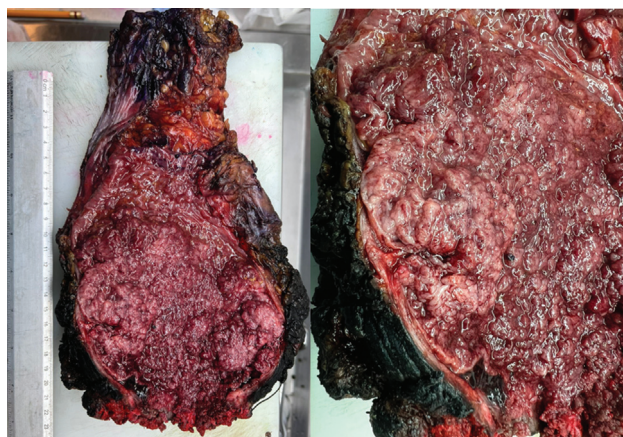

Fig. 3 Product of intersphincteric resection. Macroscopic image of the rectal tumor.

in the lower, middle, and upper rectum, located 4.1 cm from the anal margin, with involvement of all layers of the rectal wall, with diameters in the sagittal plane of 17.1 × 7.5 cm (► **Figures 1 and 2**).

He underwent a robotic assisted intersphincteric resection with colo-anal anastomosis and a protective ileostomy (abdominal and perineal proctectomy with anastomosis).

The histopathology report showed a well differentiated invasive adenocarcinoma, with mucosal and submucosal invasion, secondary to a precursor lesion of a villous adenoma 12.5 cm in diameter, without lymphovascular or neural invasion, with margins free of neoplasia and 19 negative nodes analyzed (► **Figure 3**).

The patient's evolution was satisfactory, with tolerance of the liquid diet on the first postoperative day and subsequent progression to a soft diet; he began to ambulate on the second day.

A colon enema was performed 3 weeks postoperatively, with no evidence of contrast medium leakage. He is in protocol for intestinal restitution.

Discussion

Described by McKittrick and Wheelock in 1954, the syndrome bearing the same name is characterized by an electrolyte imbalance with acute renal injury secondary to chronic diarrhea due to a secretory rectal villous adenoma.

Villous Adenomas and their Characteristics

Villous adenomas represent 5% of colonic adenomas and, of these only 3% have secretory activity, as in the case presented.

This syndrome is associated with large tumors, generally larger than 3 cm, which have a higher risk of malignant transformation, since 50% of villous adenomas larger than 2 cm are carriers of invasive cancer.^{2,3}

In spite of being characterized by a large tumor located in the lower rectum, the delay in diagnosis is frequent, given that the digital rectal exam is not always relevant in inexperienced hands, due to its soft texture because it

has a mucin coating, which gives it a velvety texture. Therefore, in patients with good diagnostic possibilities, sigmoidoscopy is estimated to have a diagnostic capacity of up to 99 % of the cases.¹

The Acute Kidney Injury and its Hypersecretory State

This hypersecretory state is due to the fact that these bulky tumors promote fluid secretion by expression of prostaglandin E₂, with elevations of up to 6 times the normal value than in the mucosa of healthy patients. The action of prostaglandins and fluid secretion are an area of study and debate in relation to their specific action, but it is considered that the evolution and action of prostaglandins in relation to the clinical evolution of the patient is divided into 3 phases: A prolonged latent phase, a short phase of deterioration and finally, a phase of decompensation. These 3 stages usually have a duration of 24 months, characteristically maintaining diarrhea throughout this period. This last stage of decompensation is usually the cause of admission and investigation for hydroelectrolytic and metabolic imbalances, specifically acute kidney injury with hyponatremia and hypokalemia, if the tumor mass was not detected or addressed in previous evaluations.¹⁻⁶

Treatment

Treatment consists of resuscitation with intravenous fluids, correction of electrolyte imbalance and surgical resection as definitive treatment.

For patients who are not fit for surgery or who maintain large volume bowel movements prior to the procedure, the use of indomethacin and octreotide have been used in small case series, with moderate response without a significant reduction in mortality.^{7,8}

For definitive surgical treatment, an abdominoperineal resection has been proposed as the ideal approach. This is due to the involvement of the tumor towards the rectal wall, however, when the resources are available to perform robot-assisted surgery, an intersphincteric resection with preservation of the anal sphincter can be performed, thus

preserving continence, with a high impact on patients' quality of life.¹

Conclusions

McKittrick Wheelock syndrome is relevant as a diagnostic consideration in patients with chronic diarrhea and non-relevant rectal examination in the first instance, given the difficulty that may imply its finding with ordinary methods. The high impact of early diagnosis on patients' lives and survival makes this syndrome an important consideration for all clinicians dealing with patients with diarrhea.

Conflict of Interest

None declared.

References

- 1 Orchard MR, Hooper J, Wright JA, McCarthy K. A systematic review of McKittrick-Wheelock syndrome. *Ann R Coll Surg Engl* 2018;100(08):1-7
- 2 Martins BA, Gomes AC, de Almeida Santos ME, Moreira NM, de Almeida RM, de Sousa JB. McKittrick-Wheelock Syndrome Secondary to Rectal Adenocarcinoma. *J Coloproctol (Rio J)* 2022;42(02):187-189
- 3 Raphael MJ, McDonald CM, Detsky AS. McKittrick-Wheelock syndrome. *CMAJ* 2015;187(09):676-678
- 4 de Sousa Miranda I, Ferreira JR, Rocha S, Monteiro M, Guilherme J, Domingos R. McKittrick-Wheelock Syndrome: A Neoplastic Cause of Electrolyte Imbalance. *Eur J Case Rep Intern Med* 2022;9(03):003231
- 5 Podestà MA, Cucchiari D, Merizzoli E, Elmore U, Angelini C, Badalamenti S. McKittrick-Wheelock syndrome: a rare cause of acute renal failure and hypokalemia not to be overlooked. *Ren Fail* 2014;36(05):811-813
- 6 Ordieres Díaz C, Pérez Valle I, Fernández de la Varga M, et al. Síndrome de McKittrick-Wheelock: adenoma vellosa rectal como causa de insuficiencia renal aguda. *Rev Esp Enferm Dig* 2022;114(04):245
- 7 Fernández-López F, Paredes-Cotore JP. McKittrick-Wheelock syndrome - Prolapsed giant villous adenoma of the rectum. *Rev Esp Enferm Dig* 2013;105(05):309-310
- 8 Nakhla SG, Murakami TT, Sundararajan S. Poorly differentiated neuroendocrine tumor of the rectum coexistent with giant rectal villous adenoma presenting as McKittrick-Wheelock syndrome. *Case Rep Oncol Med* 2015;2015:242760