



Case Report

Submucosal lipoma simulating a malignant tumor of the left colon: a case report



Victor Minari Campos^{a,*}, Sergio Mazzola Poli de Figueiredo^a,
Rodrigo Salmeron de Toledo Aguiar^a, Augusto Canton Gonçalves^a,
Thiago Manzione^b, Fang Chia Bin^b

^a Faculdade de Ciências Médicas da Santa Casa de São Paulo (FCMSCSP), São Paulo, SP, Brazil

^b Irmandade de Misericórdia da Santa Casa de São Paulo, Departamento de Coloproctologia, São Paulo, SP, Brazil

ARTICLE INFO

Article history:

Received 1 February 2016

Accepted 20 April 2016

Available online 30 June 2016

Keywords:

Lipoma

Colon tumor

Benign tumor

Colon

Descending colon

ABSTRACT

Intestinal lipomas can occur anywhere in the gastrointestinal tract, and these tumors are more frequent in the colon. By being largely asymptomatic, colonic lipomas are usually found incidentally, as findings in colonoscopy examinations, in association with biopsy. Endoscopic or surgical resection is the therapeutic option, depending on the size of the tumor, its location, and the presence or absence of symptoms. In this study, we present a case of a 59-year old woman, with a descending colon lipoma histologically diagnosed only after surgical resection of the lesion. The approach was adopted according to the patient's clinical picture (intestinal bleeding, vomiting and weight loss), in addition to the occlusion of 80% of the colonic lumen observed in a colonoscopy.

© 2016 Sociedade Brasileira de Coloproctologia. Published by Elsevier Editora Ltda. This is an open access article under the CC BY-NC-ND license (<http://creativecommons.org/licenses/by-nc-nd/4.0/>).

Lipoma submucoso simulando tumor maligno de cólon esquerdo: relato de caso

RESUMO

Os lipomas intestinais podem ocorrer em qualquer parte do trato gastrointestinal, sendo mais frequente no cólon. Por serem em grande parte assintomáticos, os lipomas colônicos são usualmente encontrados acidentalmente como achados de exame de colonoscopia associada à biópsia. Como opções de tratamento, há a ressecção endoscópica ou cirúrgica, a depender do tamanho do tumor, sua localização e presença (ou não) de sintomas. Nesse relato, é apresentado um caso de uma mulher de 59 anos com lipoma de cólon

Palavras-chave:

Lipoma

Tumor de colon

Tumor benigno

Colon

Colon descendente

* Corresponding author.

E-mail: victor_mcampos@hotmail.com (V.M. Campos).

<http://dx.doi.org/10.1016/j.jcol.2016.04.014>

2237-9363/© 2016 Sociedade Brasileira de Coloproctologia. Published by Elsevier Editora Ltda. This is an open access article under the CC BY-NC-ND license (<http://creativecommons.org/licenses/by-nc-nd/4.0/>).

descendente, diagnosticado histologicamente apenas após ressecção cirúrgica da lesão. A conduta foi adotada pelo quadro clínico de enterorragia, vômitos e perda ponderal, além da oclusão de 80% da luz do cólon observada em exame de colonoscopia.

© 2016 Sociedade Brasileira de Coloproctologia. Publicado por Elsevier Editora Ltda. Este é um artigo Open Access sob uma licença CC BY-NC-ND (<http://creativecommons.org/licenses/by-nc-nd/4.0/>).

Introduction

Colonic lipomas are benign tumors arising from the connective tissue of the intestinal wall,¹ representing 2.6% of non-malignant tumors of the gastrointestinal tract.² Although this is the most frequent non-malignant intramural mesenchymal tumor of the gastrointestinal tract and the third in frequency, coming after adenomatous and hyperplastic polyps, are few the cases described in the literature.²⁻⁴ In most cases, the tumor is asymptomatic,^{1,3,5} generally being an accidental finding of imaging studies,³⁻⁷ but these tumors may show symptoms such as abdominal pain, rectal bleeding, change in bowel habits, abdominal bloating, anorexia, and weight loss.^{3-6,8}

Case report

Our patient was a 59-year old brown-colored female seen at the Coloproctology outpatient clinic of a tertiary hospital with a history of hypogastric colic pain for a year, accompanied by vomiting, diarrhea, and rectal bleeding. In addition, the patient mentioned a weight loss of 5 kg in a year. This patient is hypertensive, with lactose intolerance and has no family history of gastrointestinal disease. On physical examination, the abdomen was flat, flaccid, and painless to palpation and with hydro-aerial sounds present. The proctologic examination revealed a normal static and dynamic inspection and the digital rectal examination was without palpable lesions. Three colonoscopies were performed; the first two were performed in other services, indicating a benign tumor of approximately 5 cm, at the transition between the descending colon and the sigmoid, occluding 40% of the colonic lumen. However, the biopsies produced unspecific results. Between the first and the last colonoscopy, 7 months have passed, and it was noted a substantial increase of 80% in the colonic lumen occlusion. The last colonoscopy was performed in our service, in order to attain a better direct visualization of the lesion, in an attempt for the histological diagnosis, and also for tattooing the lesion found, in order to facilitate the intra-operative management of the injury. A CT scan showed left colon thickening (Fig. 1). The laboratory workup showed no changes, with CEA=1.8 before surgery. Tumor excision and primary anastomosis of the resected colonic portion were carried out. Postoperatively, there were no complications and the patient was discharged in a good condition. The pathological examination showed a polypoid-like lesion measuring 4.5 cm × 3.5 cm, with a yellow, soft to cut, tissue (Figs. 2 and 3). A mucosa with reduced wrinkling and a gray area and with parietal infiltration was also observed. The adipose tissue was

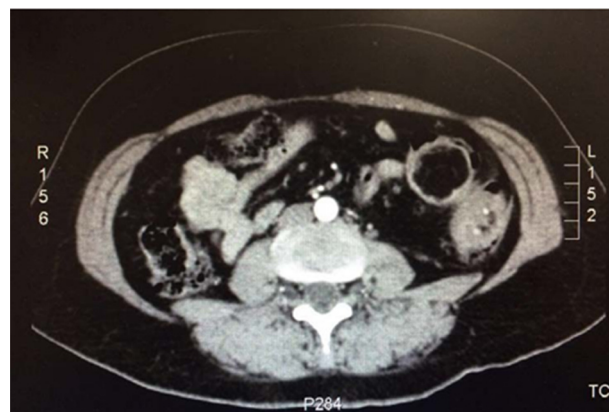

Fig. 1 – Abdominal CT with left colon thickening.

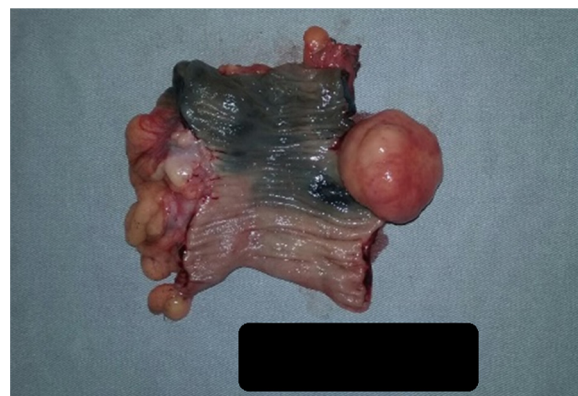

Fig. 2 – Surgical specimen.

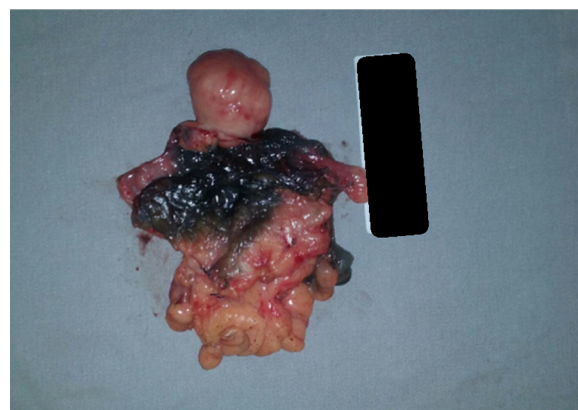

Fig. 3 – Surgical specimen.

lobed and without special features. The diagnosis of intestinal submucosal lipoma was confirmed, with process-free surgical margins.

Discussion

Our patient is a 59-year old female, which corresponds to the most frequent gender and age group of patients diagnosed with lipoma: women between the fifth and sixth decade of life.^{1,6,7}

Intestinal lipomas are commonly diagnosed through findings in colonoscopy procedures indicated for the treatment of other diseases or for screening purposes, considering that these tumors are more prevalent in the colon than in the small intestine,^{2,5,7,8} being asymptomatic in most cases.^{1,3,5,7} Clinical manifestations are evident in approximately 6–25% of diagnoses.^{1,5} However, the case at issue corresponds to a giant lipoma, anatomopatologically proven by the size of the surgical specimen, a piece measuring over 4 cm. In the face of tumors of such size, the percentage of symptomatic cases is 75%.^{5,6} The patient complained of an hypogastric pain, episodes of rectal bleeding, diarrhea and a mild weight loss – normal findings in symptomatic cases of lipoma.^{4-6,8} In addition, the patient had vomit episodes, which is not often described in the literature.

Colonoscopy is the primary method for diagnosis of colonic lipomas. The characteristic findings are the presence of a wide-base tumor, with a yellowish tint due to the underlying fatty tissue. Furthermore, a “tenting sign” and a “cushion sign” are also observed: the first signal is elicited if one pulls the mucosa overlying the lipoma, which detaches itself easily, as seen in other submucosal lesions; the second signal consists in touching the lipoma with a biopsy forceps; the lipoma is depressed easily and quickly returns to its original form.^{3,4,6,9} After the establishment of the diagnosis, one must consider a surgical approach. Tumor resection is indicated in cases of a symptomatic lipoma, particularly with obstruction or bleeding; if the mass measures more than 2.5 cm; or if the injury is mimicking malignancy.^{1,2,5,6,8} In the case reported, with the first two consecutive colonoscopies a 4-cm diameter protruding injury with a 40% of occlusion of the lumen of the descending colon – site of 20% of colonic lipomas – was diagnosed.^{1,4-7} At this point, a surgery could have been performed, both considering the clinical manifestations and the tumor size. However, this was not done due to the irregular follow-up in another service. After 7 months, a new colonoscopy showed a 6-cm lesion with 80% of occlusion; this time, the lesion was resected, despite the absence of a histological diagnosis with the colonoscopy examinations performed prior to surgery. Thus, a laparotomy was performed, along with a segmental left colectomy with primary anastomosis. Lipomas with a less than 2-cm diameter can be removed endoscopically; on the other hand, larger lesions must be surgically resected.⁴

The pathological examination of the surgical specimen confirmed a description macro- and microscopically consistent with a diagnosis of intestinal submucosal lipoma, which is in accordance with the highest frequency among

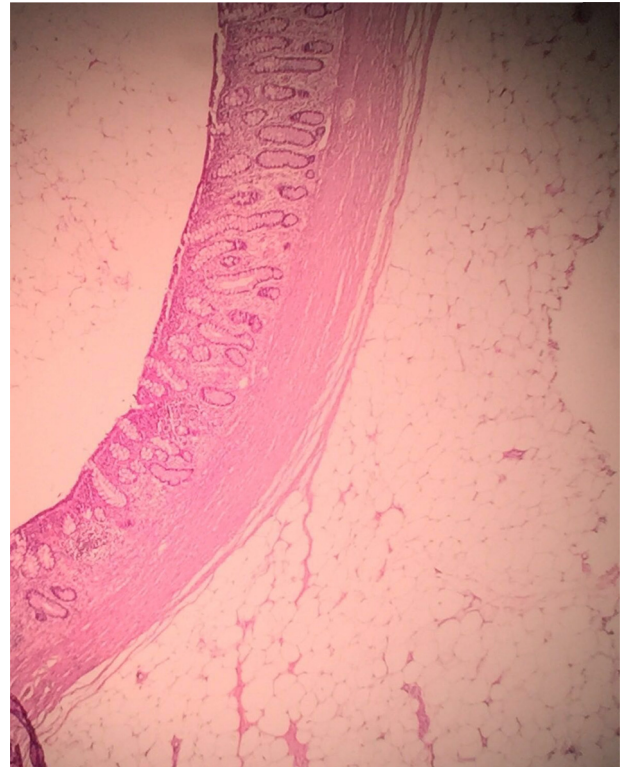


Fig. 4 – Histology of lesion compatible with submucosal lipoma.

its subtypes. Submucosal lipomas are more frequent than subserosal and mixed lipomas.^{1,4} Histologically, the lipoma shows a dense accumulation of enlarged and rounded fat cells with cytoplasm and nucleus in the cell periphery (Fig. 4).¹ Grossly, the tumor may present itself in different forms: rounded, sessile or covered by a fibrous tissue capsule branching over the adipose tissue mass, which results in their lobate appearance.^{1,4}

Conclusion

Lipomas are rare benign tumors. In most cases, these tumors are asymptomatic and are accidentally diagnosed, particularly by colonoscopy. Their treatment is based on the size of the lesion, presence of symptoms, and if there is suspicion of malignancy, and the evaluated criteria point to an endoscopic or surgical resection. The gender and age group of our patient were the most prevalent for this disease, and hers was a giant and symptomatic tumor; however, it tumor was not localized in the most frequent position in the colon. For all these reasons, we chose to perform a surgery.

Conflicts of interest

The authors declare no conflicts of interest.

REFERENCES

1. Andrei LS, Andrei AC, Usurelu DL, Puscasu LI, Dima C, Preda E, et al. Rare cause of intestinal obstruction – submucous lipoma of the sigmoid colon. *Chirurgia (Bucur)*. 2014;109:142–7.
2. Aminian A, Noaparast M, Mirsharifi R, Bodaghabadi M, Mardany O, Ali FAH, et al. Ileal intussusception secondary to both lipoma and angiolipoma: a case report. *Cases J*. 2009;2:7099.
3. Dultz LA, Ullery BW, Sun HH, Huston TL, Eachempati SR, Barie PS. Ileocecal valve lipoma with refractory hemorrhage. *JSLs*. 2009;13:80–3.
4. Katsinelos P, Chatzimavroudis G, Zavos C, Pilpilidis I, Lazaraki G, Papaziogas B, et al. Cecal lipoma with pseudomalignant features: a case report and review of literature. *World J Gastroenterol*. 2007;13:510–3.
5. Morimoto T, Fu KI, Konuma H, Izumi Y, Matsuyama S, Ogura K, et al. Peeling a giant ileal lipoma with endoscopic unroofing and submucosal dissection. *World J Gastroenterol*. 2010;16:1676–9.
6. Rehman A, Ahluwalia JP. Large tubular colonic mass with hematochezia and altered bowel habits. *Am Fam Physician*. 2012;86:451–3.
7. Jiang L, Jiang L-S, Li F-Y, Ye H, Li N, Cheng NS, et al. Giant submucosal lipoma located in the descending colon: a case report and review of the literature. *World J Gastroenterol*. 2007;13:5664–7.
8. Paškauskas S, Latkauskas T, Valeikaitė G, Paršeliūnas A, Svagždys S, Saladžinskas Z, et al. Colonic intussusception caused by colonic lipoma: a case report. *Medicina (Kaunas)*. 2010;46:477–81.
9. Lagos AC, Marques I, Neves B. Lipomatose gastroduodenal. *GE J Port Gastroenterol*. 2012;19:162–3.