



# Journal of Coloproctology

www.jcol.org.br



## Case Report

# Perianal hidradenoma papilliferum<sup>☆</sup>



Eduardo Rosetti Filho, Fernanda Bellotti Formiga, Sabrina Miotto,  
Galdino José Sitonio Formiga\*

Hospital Heliópolis, Serviço de Coloproctologia, São Paulo, SP, Brazil

### ARTICLE INFO

#### Article history:

Received 3 February 2017

Accepted 4 November 2017

Available online 27 December 2017

#### Keywords:

Acrospiroma

Hidradenoma papilliferum

Anal canal

Perianal

#### Palavras-chave:

Acrospiroma

Hidradenoma papilífero

Canal anal

Perianal

### ABSTRACT

Hidradenoma papilliferum is a benign cystic tumor originated in apocrine sweat glands of the anogenital region. It is common in vulvar topography and rare in the perianal region. A well-documented case of a patient with slow-growing perianal nodulation without pain or other symptoms is reported. The histological study shows a hidradenoma papilliferum. The article reviews the topic and discusses the importance of the differential diagnosis of proctological conditions. A biopsy is mandatory in anal lesions of unusual presentation.

© 2017 Published by Elsevier Editora Ltda. on behalf of Sociedade Brasileira de Coloproctologia. This is an open access article under the CC BY-NC-ND license (<http://creativecommons.org/licenses/by-nc-nd/4.0/>).

### Hidradenoma papilífero perianal

#### RESUMO

O hidradenoma papilífero é um tumor cístico benigno originado nas glândulas sudoríparas apócrinas da região anogenital, sendo comum em topografia vulvar e raro na região perianal. Relata-se um caso bem documentado de paciente com nodulação perianal de crescimento lento, sem dor ou outros sintomas, cujo estudo histológico revelou se tratar de hidradenoma papilífero. O artigo revisa o tema e discute a importância do diagnóstico diferencial das afecções proctológicas, sendo a biópsia obrigatória em lesões anais de apresentação não-usual.

© 2017 Publicado por Elsevier Editora Ltda. em nome de Sociedade Brasileira de Coloproctologia. Este é um artigo Open Access sob uma licença CC BY-NC-ND (<http://creativecommons.org/licenses/by-nc-nd/4.0/>).

<sup>☆</sup> Paper presented in September 2012 as a poster at the 61st Congresso Brasileiro de Coloproctologia, Belo Horizonte, MG, Brazil.

\* Corresponding author.

E-mail: [coloproctologiaheliopolis@yahoo.com](mailto:coloproctologiaheliopolis@yahoo.com) (G.J. Formiga).

<https://doi.org/10.1016/j.jcol.2017.11.001>

2237-9363/© 2017 Published by Elsevier Editora Ltda. on behalf of Sociedade Brasileira de Coloproctologia. This is an open access article under the CC BY-NC-ND license (<http://creativecommons.org/licenses/by-nc-nd/4.0/>).

## Introduction

Hidradenoma papilliferum is a benign cystic tumor, predominant in women aged 30–50 years.<sup>1</sup> Originating in the apocrine sweat glands of the anogenital region, this tumor affects the vulva preferentially, being uncommon in other topographies. Cooper and Mac Donald, in 1944, described the first case of perianal hidradenoma papilliferum<sup>2</sup>; since then, less than 20 cases have been published to date. Due to the small number of cases, this article reports a well-documented case of hidradenoma papilliferum with a perianal location.

## Case report

The patient is a 31-year-old, brown-colored woman. She has been exhibiting a slow-growing perianal nodule for one year without pain or other symptoms. Deny comorbidities or addictions; her mother died of breast adenocarcinoma. At the examination, we observed a cystic nodulation of 10 mm in diameter located 1 cm from the anal border (Fig. 1), without other changes in the proctological and gynecological examination. The patient was submitted to total excision of the lesion under local anesthesia, and her histological diagnosis was hidradenoma papilliferum (Fig. 2A and B).

## Discussion

Hidradenoma papilliferum is a rare benign tumor, originating in the apocrine sweat glands of the anogenital region. The literature describes this lesion as a tumor that affects almost exclusively Caucasian postpubertal women, although the case described is a brown-colored woman. The mean

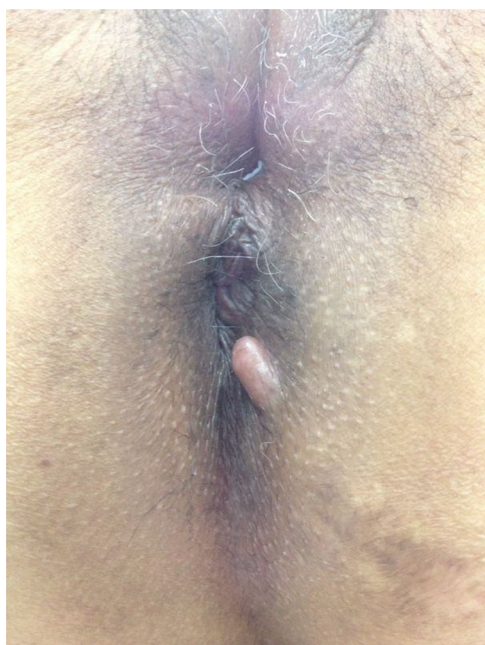


Fig. 1 – Perianal cystic nodulation.

age of patients with perianal lesions is higher (approximately 45 years) versus patients with vulvar lesions (approximately 39 years). The occurrence of this tumor in men is rare,<sup>3</sup> and some authors consider it as an accessory mammary gland tumor.<sup>2</sup>

The most common site of involvement is the vulva, especially the large lips. Less frequently, the tumor may also present in the small lips, interlabial sulcus, clitoris, posterior fourchette, pubis, perineum, anal region, and in extragenital sites.<sup>1,4</sup> The vulvar occurrence is four times more frequent than perianal occurrence.

Clinically, the tumor presents as a single, painless, small (<2 cm), unilateral nodule, with an overlying intact skin, of fibroelastic consistency, with precise limits, and with mobility; may also be of a polypous, vegetative or cystic nature. Rarely there is symptomatology in the perianal region; but in some cases, symptoms such as pain, a burning sensation, discharge, bleeding, and pruritus may be present as a result of fecal transit.

Histologically, the tumor is located in the dermis, unrelated to the epidermis; and is limited by fibrous connective tissue. The tumor consists of a conglomerate of glandular acini, tubules and small cysts covered with papillae with a double cell layer, the first with clear cuboidal or columnar cells with a basal nucleus (PAS positive) and the second with contiguous myoepithelial cells.<sup>5</sup> The absence of connective tissue in the papillary structure distinguishes hidradenoma papilliferum from syringocystoadenoma papilliferum.<sup>6</sup>

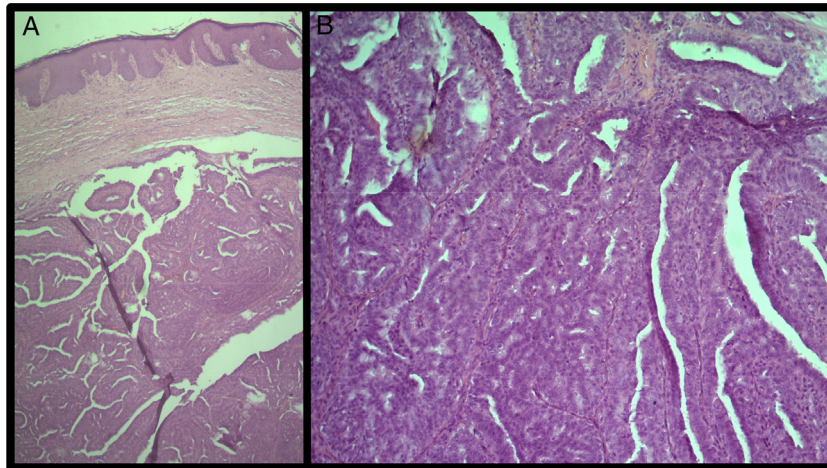
The literature is controversial about the evolution of this tumor to cancer. Many authors consider the possibility of malignancy, while others believe that this does not occur.<sup>2,5</sup> Adenomatous hyperplasia with cellular pleomorphism and an irregular papillary pattern of the acinus without lumen formation motivate a speculation about its malignant potential; sometimes this lesion is even diagnosed as adenocarcinoma. But a careful critical reassessment of suspected cases of malignancy, often misinterpreted as adenocarcinomas, has shown that, in most cases, they were, histologically, cases of hidradenoma papilliferum.<sup>1</sup>

The spectrum of differential diagnoses is broad, comprising more commonly benign lesions such as hemorrhoidal disease, anorectal abscess, viral verrucous lesion, sebaceous cyst, lipoma, and neurofibroma; and malignant lesions, such as metastatic papillary carcinoma, syringocystoadenocarcinoma papilliferum, and squamous cell carcinoma. Excisional biopsy confirms the diagnosis.

Local excision with a margin will be sufficient for its diagnosis, treatment, and cure.<sup>6</sup> In conclusion, considering the histological diversity of the anal region, dermatological diseases are a differential diagnosis of proctological conditions. A biopsy is mandatory for all anal lesions with unusual presentation.

## Conflicts of interest

The authors declare no conflicts of interest.



**Fig. 2 - (A) HE 40x - a circumscribed dermal nodule with ramifications and cystic spaces; (B) HE 100x - papillae coated by layers of tall cylindrical cells and cuboidal cells.**

#### REFERENCES

1. Handa Y, Yamanaka N, Inagaki H, Tomita Y. Large ulcerated perianal hidradenoma papilliferum in a young female. *Dermatol Surg.* 2003;29:790-2.
2. Lisbôa AC. *An brasil dermat e sif.* 1958;33:9.
3. Loane J, Kealy WF, Mulcahy G. Perianal hidradenoma papilliferum occurring in a male: a case report. *Ir J Med Sci.* 1998;167:26-7.
4. Vang R, Cohen PR. Ectopic hidradenoma papilliferum: a case report and review of the literature. *J Am Acad Dermatol.* 1999;41:115-8.
5. Elbendary A, Cochran E, Xie Q, Kabigting F, Pereira L, Elston DM, et al. Hidradenoma papilliferum with oncocytic metaplasia: a histopathological and immunohistochemical study. *Am J Dermatopathol.* 2016;38:444-7.
6. Daniel F, Mahmoudi A, de Parades V, Fléjou JF, Atienza P. An uncommon perianal nodule: hidradenoma papilliferum. *Gastroenterol Clin Biol.* 2007;31:166-8.