


# Perianal Tuberculosis in an Immunocompetent Patient: Exploring the Uncommon Manifestation

Ana Rita Ferreira<sup>1</sup> Hugo Pereira<sup>1</sup> Bárbara Castro<sup>1</sup> Joana Ferreira<sup>1</sup> Joana Esteves<sup>1</sup> Bela Pereira<sup>1</sup>  
Sílvia Vale<sup>1</sup> Manuel Oliveira<sup>1</sup>

<sup>1</sup> General Surgery Department, Centro Hospitalar de Vila Nova de Gaia, Espinho EPE, Portugal

Address for correspondence Ana Rita Ferreira, MS, General Surgery Department, Centro Hospitalar de Vila Nova de Gaia, Espinho EPE, Portugal (e-mail: anarita878@hotmail.com).

J Coloproctol 2024;44(2):e137–e140.

## Abstract

### Keywords

- ▶ extrapulmonary tuberculosis
- ▶ mycobacterium tuberculosis complex infection
- ▶ perianal tuberculosis
- ▶ inflammatory bowel disease
- ▶ tuberculosis-associated immunocompetent patient

As it is an infrequent etiology, the diagnosis of perianal tuberculosis is challenging, especially in the absence of a pulmonary focus. TB should be considered in the differential diagnosis of perianal ulcers, fistulas, abscesses, mainly in non-healing and recurrent anal lesions. Treatment with anti-TB agents can provide complete recovery. Furthermore, these lesions are often diagnosed later after complete histopathological and mycobacterial results, where the benefit of avoiding morbid multiple surgeries by effective anti-TB treatment is lost.

We reported a rare case of an immuno-competent patient with perianal TB, which was the first manifestation of the disease. A fit-and-well man in his 20s presented a large perianal abscess. Unexpectedly, his chest X-ray showed a rounded hyper-transparency in the left lung. The abscess was drained. Posterior investigation with culture analysis from pus swabs and sputum revealed the presence of Mycobacterium tuberculosis complex infection. After completing the 6 months of oral administration of anti-TB drugs, the patient was asymptomatic.

By highlighting this unusual manifestation, we aim to improve clinicians' awareness of perianal TB, facilitating early recognition and appropriate management.

## Introduction

Despite the downward trend, tuberculosis (TB) remains one of the top 10 causes of death worldwide.<sup>1</sup> However, the median of days until diagnosis has remained high, reflecting the lower suspicion of the disease, both by the population and by health professionals.<sup>2</sup>

Traditionally associated with pulmonary involvement, Mycobacterium tuberculosis can disseminate through hematogenous spread or direct extension from a primary focus, resulting in extrapulmonary manifestations in about 15% of all cases.<sup>3</sup>

Involvement of any part of the gastrointestinal tract accounts for 2%, skin occurs in 1.5% of the cases, and perianal involvement is extremely rare, with an incidence of 0.7% of

the total reported extrapulmonary manifestations. Even more unusual, it is a perianal TB in a patient without clinical pulmonary disease.<sup>2,4</sup>

Proctology TB manifestations can range from a variety of clinical conditions. Anal ulceration and fistula are the most frequent ones, but they can present as pilonidal sinus, recurrent perianal abscess, inguinal lymphadenopathy, anal fissures, anal masses, and strictures. These lesions often mimic inflammatory bowel disease, pyoderma gangrenosum, or malignancy of the anus and rectum.<sup>5</sup>

For this reason, the diagnosis of TB should be considered in cases of non-healing or recurrent perianal lesions. Mycobacterium tuberculosis culture and histologic examination should be conducted, since the early start of treatment with a prolonged course of anti-TB regimen could lead to complete

received

April 10, 2023

accepted after revision

February 7, 2024

DOI <https://doi.org/>

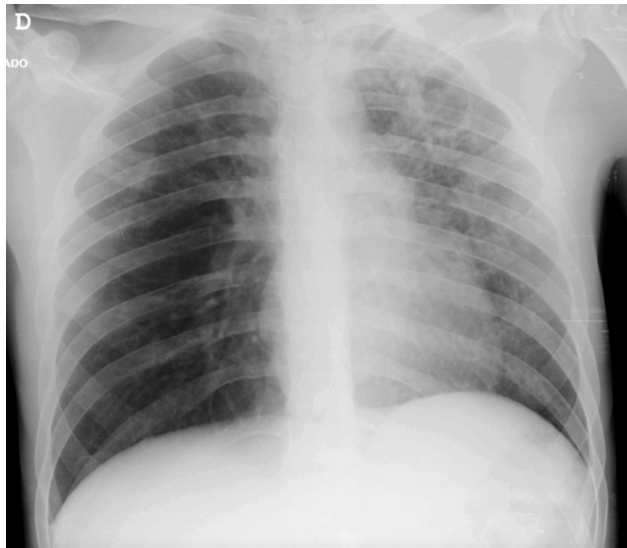10.1055/s-0044-1787286.

ISSN 2237-9363.

© 2024. The Author(s).

This is an open access article published by Thieme under the terms of the Creative Commons Attribution 4.0 International License, permitting copying and reproduction so long as the original work is given appropriate credit (<https://creativecommons.org/licenses/by/4.0/>).

Thieme Revinter Publicações Ltda., Rua do Matoso 170, Rio de Janeiro, RJ, CEP 20270-135, Brazil



**Fig. 1** Rounded hyper-transparency in the upper third of the left lung on chest radiography.

resolution of complications in majority of patients, avoiding in the morbidity of multiple surgeries.<sup>6</sup>

## Case Report

A male in his 20s presented to the Emergency Department with a fever associated with pain and swelling in the perineum in the past 5 days. His past medical history was irrelevant.

Proctological inspection showed redness, swelling, and tenderness in the right perineum. On physical examination, a 7 centimeters mass from the anal verge over the 9 o'clock position, with fluctuance and perianal pus discharge was noted.

Apart from raised white cell count (total white cell count:  $18.5 \times 10^9/L$ , reference range  $3.6-11 \times 10^9/L$ ) and raised C-reactive protein level (12.44 mg/dL, reference range 0-0.5 mg/dL), other blood parameters were within normal limits.

A surgical incision and drainage were proposed to the patient.

Unexpectedly, in the preoperative study, chest radiography showed a rounded hyper-transparency in the upper third of the left lung (►Fig. 1).

Intraoperative findings revealed a large abscess cavity in the right perineum, about 10 centimeters, without evidence of fistulas. Approximately 80 cubic centimeters of foul-smelling white creamy pus was drained and sent for microbiology and mycobacterial analyses, then the wound cavity was washed and laid open for dressings.

In view of these findings, thoracic Computed Tomography (CT) was performed and confirmed a sizeable cavitated image in the apical-posterior segment of the upper lobe of the left lung, measuring about  $6 \times 3.8$  centimeters in the axial plane, surrounded by numerous centrilobular micronodules in "tree-in-bud". Other micronodules with identical characteristics are observed spread over practically the entire left lung. This set of findings was characteristic of pulmonary TB. (►Fig. 2)

The patient did not present the typical symptoms of TB and denied any pulmonary complaints.

Mycobacterial culture from pus swabs indicated the presence of *Mycobacterium tuberculosis* complex.

Following culture analysis in the sputum confirmed *Mycobacterium tuberculosis*.

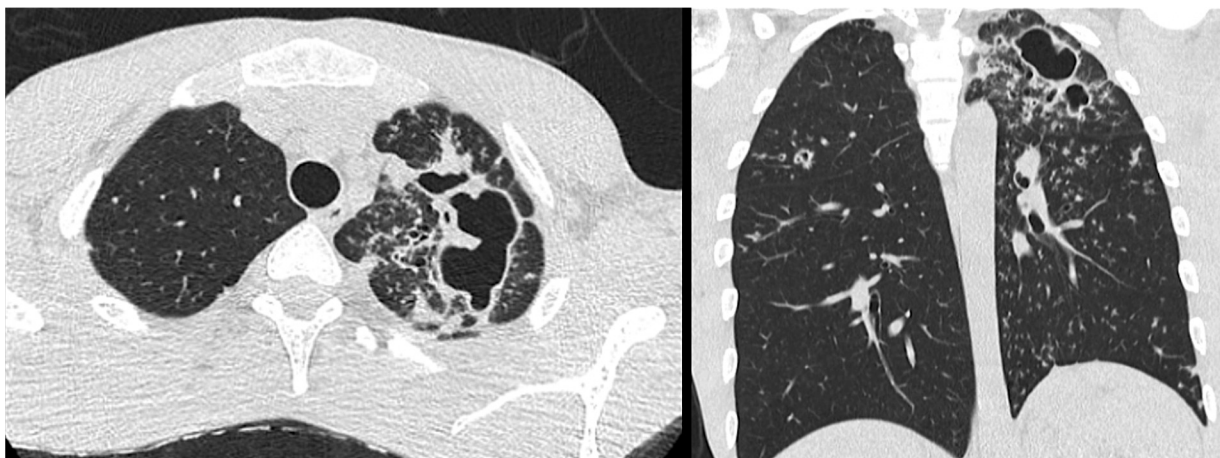
The patient tested negative for human immunodeficiency virus, hepatitis B/C, and venereal diseases.

Treatment consisting of RHZE (rifampicin, isoniazid, pyrazinamide, and ethambutol) was started and the patient's clinical course was favorable. He was discharged on the 5th postoperative day.

After completing the 6 months of oral administration of anti-TB drugs, the patient was asymptomatic. No apparent underlying disease was detected at the 6-month follow-up examination.

## Discussion

Perianal TB, a rare manifestation of the *Mycobacterium tuberculosis* infection, primarily affects immunocompromised patients.<sup>2</sup>



**Fig. 2** CT scan showing characteristic findings of pulmonary TB: cavitated image in the apical-posterior segment of the upper lobe of the left lung, abundant centrilobular micronodules in "tree-in-bud" and other micronodules spread over practically the entire left lung.

This enigmatic condition challenges our understanding of TB pathogenesis and necessitates a comprehensive exploration of its clinical characteristics, diagnostic challenges, and management strategies.

Immunocompetent individuals are typically equipped with a robust immune system capable of effectively combatting *Mycobacterium tuberculosis* infection. However, several factors, such as local tissue damage, fecal contamination, and genetic susceptibility, may contribute to the development of perianal TB in these patients.<sup>3</sup>

The exact mechanisms underlying this unexpected manifestation remain unclear, warranting further research to comprehend the interplay between host factors and mycobacterial virulence.

Therefore, it is necessary to thoroughly assess not only immunocompromised individuals but also immunocompetent patients, as TB can also manifest in this population, as noted in our case.

In relation to possible mechanisms of dissemination, the ingestion of sputum containing active pulmonary disease bacilli is the most frequent, in addition to hematogenous dissemination of a pulmonary focus, lymphatic dissemination of intestinal or genitourinary disease from regional lymph nodes, or even direct propagation from adjacent organs.<sup>3</sup>

The diagnosis of TB infection can be made based on an association between clinical findings with at least one of the following criteria: histopathological demonstration of caseating granulomatous necrosis; positive acid-fast bacilli stain from the biopsied tissue; positive TB polymerase chain reaction (PCR) on tissue or specimen; or histopathological confirmation of granuloma in a cluster with rapid response to anti-mycobacterium treatment.<sup>5,6</sup>

Accurate diagnosis of perianal TB relies on a complex approach, encompassing clinical evaluation, radiological imaging, and microbiological investigations. Histopathological examination of tissue samples, together with the identification of acid-fast bacilli, remains the gold standard for definitive diagnosis. However, the paucibacillary nature of perianal TB and the need for invasive procedures can pose difficulties in obtaining adequate diagnostic specimens.

Perianal TB generally occurs secondarily to or coexists with a lung lesion.<sup>3</sup>

In suspected cases or after confirmation, chest radiography and CT scans are priority exams. In addition, patients should also be evaluated with an ultrasound, CT or magnetic resonance of the abdomen, and colonoscopy to identify possible gastrointestinal involvement.<sup>3</sup>

Clinically, perianal TB often presents with nonspecific symptoms, including perianal pain, swelling, and discharge. Due to the similarity of these symptoms to other perianal conditions, such as perianal abscesses or fistulas, establishing an accurate diagnosis could be a challenge, requiring a high level of suspicion. The lack of awareness and limited clinical suspicion for perianal TB in immunocompetent patients leads to misdiagnosed cases.

Perianal TB patients often experience a prolonged period of disease prior to diagnosis and initiation of treatment, as frequent misidentification of perianal TB and frequently

mistaken for other more prevalent perianal conditions, such as Crohn's disease, pyoderma gangrenosum, hidradenitis, sarcoidosis, herpes simplex. Consequently, a majority of patients present with chronic and recurrent lesions that have exhibited resistance to numerous pharmacological and surgical interventions.<sup>6,7</sup>

To the best of our knowledge, fewer than 60 cases of perianal TB have been reported in the literature.

In a comprehensive review, Tago et al.<sup>4</sup> studied 58 cases of perianal TB (abscess, fistula, and ulceration) reported from 1970 to 2014 worldwide, and found that the duration of persistent perianal lesions was much longer in patients without active pulmonary TB (APT) than in those with APTB. In this sample, only 18.6% of those patients had underlying diseases related to immunodeficiency.

Almost all the literature on the subject is case reports, the most frequent being skin ulcerations, fistulas, and, more infrequently, abscesses or necrotizing fasciitis.

Recently, Lip et al,<sup>6</sup> reported a case of a patient with a perianal ulcerating tumor, who succumbed 2 days postoperatively, probably to a pre-existing undiagnosed disseminated TB with perianal sepsis.

While perianal TB typically has a low mortality rate, its severe form of necrotizing fasciitis with the underlying immunocompromised state can result in a mortality rate of as high as 50%.<sup>6,7</sup>

Perianal TB does not resolve spontaneously and, if not properly treated, it can lead to death by miliary spread.

Perianal TB treatment includes a medical regimen but may require a surgical approach, mainly in abscesses.

The description of a case with perianal TB is *per se* of interest since this form of tuberculosis is very atypical and diagnosis is delayed.

We presented a challenging diagnostic case of perianal TB in an immunocompetent patient, in which cutaneous perianal disease was the only TB symptom, with no previous or current abdominal TB history. The patient's condition posed a significant diagnostic hurdle, and, in our opinion, exogenous inoculation probably occurred after local trauma.

## Conclusion

Exploring the underlying mechanisms responsible for perianal TB in immunocompetent individuals may offer valuable insights into the pathogenesis of tuberculosis and potentially pave the way for novel therapeutic interventions. Comprehensive knowledge and further research in this domain are crucial for refining diagnostic algorithms and improving patient outcomes.

As we embark on this exploration, it becomes evident that perianal tuberculosis in immunocompetent patients represents a medical puzzle that demands meticulous investigation and collaboration between clinicians, researchers, and public health authorities.

By databasing and investigating this condition, we can achieve earlier detection, effective management, and ultimately, better patient care.

Given the disease's epidemiological significance, accurate diagnosis and careful patient follow-up were of maximum

importance, with potential impact on quality of life, and the associated high morbidity and mortality rates.<sup>4</sup>

#### Consent to Participate

The patient consented to this case report.

#### Written Consent for Publication

The first author obtains the patient's written consent for publication.

#### Authors' Contributions

AF is responsible conception and design of the article, for writing the manuscript (and revision), and received informed consent from the patient. HP and BC are responsible for critically revising the article. JF and JE are responsible for the surgical care of the patient and critical revision of the article. BP, SV, and MO are responsible for the surgical department, and they critically revised the article.

#### Ethics Approval

Not applicable

#### Availability of Data and Material (Data Transparency)

The authors confirm that the data supporting the findings of this study are available within the article.

#### Code Availability (Software Application or Custom Code)

Not applicable

#### Fundings

No funds, grants, or other support was received.

#### Conflict of Interests

All authors declare that they have no conflict of interest.

#### References

- 1 World Health Organization, The top 10 causes of death,. 9 December 2020
- 2 Mosenza G, Della Giustina A, Matos D'Almeida Santos JC, Schwartz J, Almeida Victorino J. Perianal tuberculosis in an immunocompetent patient. *J Eur Acad Dermatol Venereol* 2018;32(06):e229–e230. Doi: 10.1111/jdv.14757
- 3 Takahashi AAR, Bassaneze T, Longo KS, Batista JG, Waisberg J. Primary extensive perianal cutaneous tuberculosis: A challenging diagnosis. Case report and a review of the literature. *Braz J Infect Dis* 2023;27(01):102722. Doi: 10.1016/j.bjid.2022.102722
- 4 Tago S, Hirai Y, Ainoda Y, Fujita T, Takamori M, Kikuchi K. Perianal tuberculosis: A case report and review of the literature. *World J Clin Cases* 2015;3(09):848–852. Doi: 10.12998/wjcc.v3.i9.848
- 5 Medina-Murillo GR, Rodríguez-Medina U, Rodríguez-Wong U. Perianal cutaneous tuberculosis. *Rev Gastroenterol Mex* 2017; 82(03):259–260. Doi: 10.1016/j.rgm.2017.02.002
- 6 Lip HTC, Huei TJ, Qin NZ. Perianal Tuberculosis. *J Gastrointest Surg* 2021;25(07):1920–1922. Doi: 10.1007/s11605-021-04907-5
- 7 Garg P, Garg M, Das BR, Khadapkar R, Menon GR. Perianal Tuberculosis: Lessons Learned in 57 Patients From 743 Samples of Histopathology and Polymerase Chain Reaction and a Systematic Review of Literature. *Dis Colon Rectum* 2019;62(11):1390–1400. Doi: 10.1097/DCR.0000000000001493