



Original article

# Assessment of LIFT (ligation of the intersphincteric fistula tract) technique in patients with perianal transsphincteric fistulas



Caroline Sauter Dalbem, Sérgio Danilo Tanahara Tomiyoshi,  
Carlos Henrique Marques dos Santos\*

Universidade Federal de Mato Grosso do Sul (UFMS), Campo Grande, MS, Brazil

## ARTICLE INFO

### Article history:

Received 26 March 2014

Accepted 4 September 2014

Available online 22 October 2014

### Keywords:

Fistula

Treatment

Colorectal surgery

## ABSTRACT

Perianal fistulas are a relatively common condition in Proctology offices, ranging from simple cases with easily palpable superficial tracts to complex problems with deep tracts across significant portions of the anal sphincter, which section can lead to varying degrees of incontinence during a fistulotomy.

**Objective:** To evaluate the effectiveness of the use of the LIFT (ligation of the intersphincteric fistula tract) technique in patients with perianal transsphincteric fistulas.

**Method:** A prospective study of patients with perianal transsphincteric fistula who underwent LIFT. Patients with perianal fistulas of cryptoglandular transsphincteric origin with no previous surgical interventions were included in the study. Patients with perianal fistulas from another source, such as Crohn's disease, tuberculosis, anal cancer and recurrent fistulas, were excluded. All patients underwent the same anesthetic technique, with subsequent surgical treatment in two stages: seton placement and, after 6 weeks, completion of LIFT.

**Results:** We evaluated 22 patients; the mean age was 45.6 years. The post-LIFT outpatient follow-up ranged from 4 to 24 months with a mean follow-up of 14 months. The healing time varied from 4 to 8 weeks after the procedure. Seventeen patients were cured (77%) and five relapsed (23%); however, all of them exhibited the intersphincteric type, having been treated by fistulotomy and also achieving complete cure. One female patient developed mild fecal incontinence.

**Conclusion:** The LIFT technique proved to be safe and effective in the treatment of transsphincteric perianal fistulas.

© 2014 Sociedade Brasileira de Coloproctologia. Published by Elsevier Editora Ltda. All rights reserved.

\* Corresponding author.

E-mail: [chenriquems@yahoo.com.br](mailto:chenriquems@yahoo.com.br) (C.H.M. dos Santos).

<http://dx.doi.org/10.1016/j.jcol.2014.09.001>

2237-9363/© 2014 Sociedade Brasileira de Coloproctologia. Published by Elsevier Editora Ltda. All rights reserved.

## Avaliação da técnica LIFT (Ligation of the Intersphincteric Fistula Tract) em pacientes com fístulas perianais transesfincterianas

### R E S U M O

#### Palavras-chave:

Fístula

Tratamento

Cirurgia colorretal

As fístulas perianais são uma condição relativamente comum em consultório de proctologia, podendo variar desde casos simples, com trajetos superficiais facilmente palpáveis, até casos complexos, com trajetos profundos, atravessando porções consideráveis do aparelho esfinteriano, cuja secção pode levar a graus variáveis de incontinência durante uma fistulotomia.

**Objetivo:** Avaliar a efetividade do emprego da técnica LIFT (ligation of the intersphincteric fistula tract) nos pacientes portadores de fístulas perianais transesfincterianas.

**Método:** Estudo prospectivo com pacientes portadores de fístula perianal transesfincteriana submetidos à técnica LIFT. Foram incluídos no estudo pacientes portadores de fístulas perianais de origem criptoglandular transesfincteriana sem intervenções cirúrgicas prévias. Foram excluídos pacientes portadores de fístulas perianais de outra origem, como doença de Crohn, tuberculose, neoplasia anal e fístulas recidivadas. Todos os pacientes foram submetidos à mesma técnica anestésica e posterior tratamento cirúrgico em dois tempos: colocação de sedenho e após seis semanas realização de LIFT.

**Resultados:** Foram avaliados 22 pacientes; a média de idade observada foi de 45,6 anos. O seguimento ambulatorial pós-LIFT variou de 4 a 24 meses, com média de acompanhamento de 14 meses. O tempo de cicatrização variou de 4 a 8 semanas pós-procedimento. Dezesete pacientes ficaram curados (77%) e cinco apresentaram recidiva (23%), porém, todos na forma interesfincteriana e foram tratados por fistulotomia, alcançando também a cura completa. Uma paciente evoluiu com incontinência fecal leve.

**Conclusão:** A técnica LIFT demonstrou ser segura e eficaz no tratamento das fístulas perianais transesfincterianas.

© 2014 Sociedade Brasileira de Coloproctologia. Publicado por Elsevier Editora Ltda.

Todos os direitos reservados.

## Introduction

The occurrence of perianal disease dates back from antiquity. For the treatment of anal fistulas, Hippocrates recommended, among other procedures, cauterizing and anodizing the fistula – which can be understood today as seton application.<sup>1</sup>

Over the years, various studies and surgical techniques have been developed with the aim to find the most appropriate treatment for this disease, which has an incidence of 1/10,000 inhabitants per year and represents 5% of all Coloproctology office visits.<sup>2,3</sup>

These defects are distributed in the following proportion, using the classification described by Parks et al. (1976): intersphincteric (60–75%), transsphincteric (15–20%), suprasphincteric (5%) and extrasphincteric (1–3%) fistulas.<sup>2</sup>

Currently, there is little doubt as to the indication of surgical treatment as the best treatment option, and fistulotomy is the technique of choice for the vast majority of cases. However, more complex fistulae, when treated similarly, can be cured – but only at the expense of varying degrees of fecal incontinence.

Thus, many other techniques have been developed with the aim to achieve the same cure rate for fistulotomy, but without causing fecal incontinence in cases of greater complexity. However, there is still no clear definition of the best option in these cases.

In 2007, Rojanasakul et al.<sup>4</sup> described a new therapeutic option for cases like these, with very promising initial results. The LIFT (ligation of the intersphincteric fistula tract) technique, as it became known, has shown good results also in other studies,<sup>5</sup> not inferior to traditional techniques, and still having as great merit the fact of (theoretically) not causing fecal incontinence, considering that no section of the sphincter occurs. As there are still few studies on the subject, the aim of this research is to evaluate the results of LIFT in patients with transsphincteric perianal fistulas.

## Method

The study was approved by the Ethics Committee on Research of the Universidade Federal de Mato Grosso do Sul. For inclusion, the patients were informed by the research team on the surgical technique used and on the possible complications of the surgery; and agreed to participate in the study, completing the free and informed consent term.

Prospectively, we described a series of patients with transsphincteric perianal fistula who underwent surgical repair using LIFT. The study included men and women with transsphincteric perianal fistulas of cryptoglandular source with no previous surgical intervention, between 18 and 80 years of age, from the Coloproctology Service, Hospital Universitário Maria Aparecida Pedrossian (Universidade Federal de Mato Grosso do Sul), from an outpatient clinic of

Coloproctology, Hospital Regional de Mato Grosso do Sul, and from the private practice of one of the authors.

The study was conducted from May 2012 to September 2013. Patients with perianal fistulas from another source, individuals with Crohn's disease, tuberculosis, anal cancer and who had recurrent fistulas were excluded. Patients with intersphincteric, suprasphincteric and extrasphincteric perianal fistulas were also excluded. All patients were operated under spinal block with morphine. The surgical treatment was performed in two stages: first, the identification of the fistula, thus confirming a transsphincteric tract. The fistula was then repaired by applying a latex seton. The placement of the seton was intended to induce a more consistent fibrosis, making the fistulous tract well defined. The second step was performed after 6 weeks: the removal of the latex seton, curettage of the tract, an opening of the skin approximately 1 cm perpendicular to the fistulous tract and dissection between the internal and external sphincters, to the identification and repair of the fistula. Then a transfixing ligature with polyglactin zero and the section of the tract between the sphincters were performed, followed by the introduction of a probe to confirm the closing of the segments of the fistulous tract and of skin closure. The crypt (inner hole) was cauterized with electrocautery and the external os was kept open.

The postoperative follow-up was performed in an outpatient clinic on the 15th day and then every 30 days until the complete healing of the fistula. Thereafter, the visits occurred bimonthly or before that time, if necessary.

In the outpatient follow-up, perioperative infection, healing time, pain, recurrence and fecal continence change were evaluated.

## Results

During the study period, 41 patients with transsphincteric perianal fistulas were selected, of which 22 met the inclusion and exclusion criteria and were kept in the study.

Of these 22 patients, 12 (55%) were male and 10 (45%) were female. The age ranged from 17 to 62 years, with a mean of 45 years. The time elapsed from the onset of a complaint compatible with perianal fistula to the diagnosis ranged from 3 to 36 months, with a mean of 11 months (Table 1).

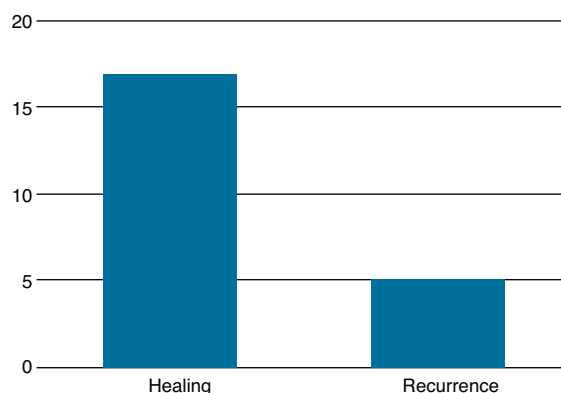
In each case, the patient was discharged within 24 h. During the outpatient follow-up, local infection (drainage of pus from surgical wound) occurred in five patients (23%), who were only followed without further intervention and with spontaneous resolution.

The post-LIFT outpatient follow-up ranged from 4 to 24 months, with a mean follow-up of 14 months. The healing time varied from 4 to 8 weeks after the procedure.

Seventeen (77%) patients obtained complete resolution of their fistula with the technique adopted, while five (23%) relapsed. Of these five, all had a recurrence in the form of an intersphincteric fistula, being subsequently operated by fistulotomy, with complete resolution – thus, a third surgical procedure. A female patient developed mild fecal incontinence (Fig. 1).

**Table 1 – Patients with perianal transsphincteric fistula treated with LIFT technique.**

Patient	Gender	Age (years)	Time from disease to treatment (months)
1	Male	24	5
2	Male	28	9
3	Female	17	14
4	Male	45	14
5	Male	60	3
6	Male	46	12
7	Female	38	10
8	Female	60	10
9	Male	34	9
10	Female	57	5
11	Male	35	4
12	Male	56	36
13	Female	50	18
14	Female	49	13
15	Female	62	10
16	Male	48	16
17	Female	49	7
18	Male	49	9
19	Female	48	12
20	Male	49	6
21	Male	39	12
22	Female	47	8
Mean	12M/10F	45	11



**Fig. 1 – Assessment of primary healing index after LIFT in the treatment of perianal transsphincteric fistulas.**

## Discussion

Many studies on the LIFT surgical technique are still in progress; this is still considered a novel technique for use in the treatment of perianal fistulas.

In the original publication describing the technique, Rojanasakul et al.<sup>4</sup> applied LIFT in 18 consecutive patients, observing primary healing in 17 of them. This result encouraged other authors to evaluate LIFT in studies worldwide.

In this series of cases, a primary healing rate of 77% was observed. In American studies that included patients who failed a previous treatment, the healing rate ranged from 55 to 64%.<sup>6</sup> In Australia, Ooi et al.,<sup>7</sup> who also included in the sample patients with recurrent perianal fistulas (40% of the sample), achieved primary healing in 68.0% of cases. On the

other hand, Shanwani et al.<sup>5</sup> reported cure in 82% of their sample. European studies showed resolution rates of 71–83% for primary healing, and in some of them up to 100% healing in the sample, in those studies that considered secondary healing patients. This demonstrates that the results obtained in this study were within the expected, according to the available literature, which can be considered a good outcome for a still recent technique.<sup>6</sup>

The mean follow-up in this series was 14 months and the relapse rate was 23%. In studies of Yassin et al.<sup>6</sup> and Liu et al.<sup>8</sup> the mean follow-up was 19 and 28 months, respectively, and the recurrence rate was 36% and 32%, respectively. Possibly the lower relapse seen in this paper is inferior to the other studies presented here due to a shorter follow-up, although the most important publications on LIFT demonstrate no late recurrence of fistulas. When relapse occurs, it is usually in the first weeks, a fact also observed in our five patients in whom recurrence was observed.

The healing time observed in this study ranged from 4 to 8 weeks. Ooi et al.<sup>7</sup> and Shanwani et al.<sup>5</sup> reported a mean healing time of 6 and 5 weeks, respectively, i.e., the same mean here obtained. The occurrence of slight variations is probable in accordance with what is considered as “healing”. Here, we considered as “complete healing” the interruption of the flow of purulent secretion with coaptation of the edges of the wound.

In the literature, data are lacking for comparison with the results presented here with respect to postoperative infection, probably because this analysis is quite subjective. Moreover, this analysis is less important compared with fistula healing and the evaluation of continence – parameters that are effectively analyzed by most publications on LIFT.

Although generally the results obtained in this study demonstrate that LIFT is a very promising technique, in line with data from the literature, we consider as being quite disturbing the observation of fecal incontinence in one of our patients, by being a young woman with no other risk factors for this condition. Considering that one of the main expected advantages of the technique is a low or zero possibility of an impaired sphincter function (since there is no section of the sphincter), this result was quite surprising. That patient has been treated with pelvic floor physical therapy, with improvement. No American, Asian or Oceanian study reported damage to the sphincter function. However, in a review conducted by Yassin et al.,<sup>6</sup> it was observed that in 11% of their sample there was some sort of change in continence. This may be associated with the inclusion of patients with recurrent perianal fistula who had gone through previous treatments.

Of the five patients who did not achieve a primary healing in this study, all showed recurrence in the incision for ligation of the fistulous tract, i.e., their defects turned into intersphincteric fistulas, and could be subsequently treated by fistulotomy with complete resolution and with no fecal incontinence. This development has already been reported by others and can be considered an advantage of the method, which enables a primary cure in most cases, but, when this does not occur, at least reduces the complexity of the fistulous tract.<sup>6-9</sup>

---

## Conclusion

The LIFT technique was effective in the treatment of perianal transsphincteric fistulas.

---

## Conflicts of interest

The authors declare no conflicts of interest.

---

## REFERENCES

1. A história da coloproctologia [Internet]. Available from: <http://www.procto.net.br/page.html> [accessed 02.04.12].
2. Sobrado CW, Nahas SC, Marques CFS. Fístulas Anorretais. In: Rodrigues JG, Machado MCC, Rasslan S, editors. *Clínica Cirúrgica*, 1. Barueri-SP: Editora Manole; 2008. p. 997–1007.
3. Rocha JJR. Processos Infeciosos Perianais, Abscessos Perianais, Fístulas Perianais e Gangrena perineal [Internet]. Available from: <http://www.fmrp.usp.br/cg/novo/images/pdf/conteudo.disciplinas/processosinfeciosos> [accessed 30.03.12].
4. Rojanasakul A, Pattanaarun J, Sahakitrungruang C. Total anal sphincter saving technique for fistula-in-ano; the ligation of intersphincteric fistula tract. *J Med Assoc Thai*. 2007;90:581–6.
5. Shanwani AMS, Nor AM, Amri NMK. The ligation of the intersphincteric fistula tract (LIFT): a sphincter-saving technique for fistula-in-ano. *Dis Colon Rectum*. 2010;53:39–42.
6. Yassin NA, Hammond TM, Lunniss PJ, Phillips RK. Ligation of the intersphincteric fistula tract in the management of anal fistula. A systematic review. *Colorectal Dis*. 2013;15:527–35.
7. Ooi K, Skinner I, Croxford M, Faragher I, McLaughlin S. Managing fistula-in-ano with ligation of the intersphincteric fistula tract procedure: the Western Hospital experience. *Colorectal Dis*. 2012;14:599–603.
8. Liu WY, Aboulian A, Kaji AH, Kumar RR. Long-term results of ligation of intersphincteric fistula tract (LIFT) for fistula-in-ano. *Dis Colon Rectum*. 2013;56:343–7.
9. Van Onkelen RS, Gosselink MP, Schouten WR. Ligation of the intersphincteric fistula tract in low transsphincteric fistulae: a new technique to avoid fistulotomy. *Colorectal Dis*. 2013;15:587–91.