



## Original Article

# A prospective study on tubercular fistula in ano and its management



Manoranjan Sahu<sup>a,\*</sup>, Jai Krishna Mishra<sup>b</sup>, Ashish Sharma<sup>a</sup>, Uzma Fatmi<sup>a</sup>

<sup>a</sup> Banaras Hindu University, Institute of Medical Sciences, Faculty of Ayurveda, Department of Shalya Tantra, Varanasi, India

<sup>b</sup> Banaras Hindu University, Institute of Medical Sciences, Department of Respiratory Diseases, Varanasi, India

### ARTICLE INFO

#### Article history:

Received 8 January 2017

Accepted 21 April 2017

Available online 19 May 2017

#### Keywords:

Tuberculosis

Fistula in ano

Antitubercular treatment

### ABSTRACT

**Objective:** Tuberculosis fistula in ano, though less encountered, is an important clinical entity in developing countries like India. Diagnosis of TB fistula is a challenge despite of advances in diagnostic modalities and it depends upon both local and systemic clinical presentation. This prospective study aimed at to substantiate the importance of clinical diagnosis as well as medical management of tubercular fistula by antitubercular drugs.

**Methods and results:** 25 patients of fistula in ano suspected to be of tubercular origin underwent histopathology of fistulous tracks and an 8 week therapeutic trial of antitubercular treatment after getting an informed consent. Though biopsy showed positive evidence of tubercular pathology only in 52% cases, therapeutic trial showed improvement in local and systemic features in 23 (92%) cases. Of these 23 cases, 3 were cured after 18 months of anti tubercular treatment and 18 showed cure after 24 months of anti tubercular treatment while 2 cases withdrew from the study at 12 and 14 months respectively due to adverse drug reactions though their fistulous symptoms were relieved.

**Conclusion:** Meticulous clinical evaluation plays a vital role in diagnosis of tubercular fistula in addition to other diagnostic methods. Anti tubercular treatment is the mainstay of treatment in tubercular fistula with a minimum duration of 18–24 months owing to the recurrent and relapsing nature of disease.

© 2017 Sociedade Brasileira de Coloproctologia. Published by Elsevier Editora Ltda. This is an open access article under the CC BY-NC-ND license (<http://creativecommons.org/licenses/by-nc-nd/4.0/>).

### Estudo prospectivo sobre a fístula anal tuberculosa e seu tratamento

#### RESUMO

**Objetivo:** A fístula anal da tuberculose (TB), embora menos observada, constitui entidade clínica importante em países em desenvolvimento, como a Índia. O diagnóstico de fístula TB é tarefa desafiadora, apesar dos avanços nas modalidades diagnósticas; seu estabelecimento depende tanto da apresentação clínica local, como da apresentação sistêmica. Esse estudo

#### Palavras-chave:

Tuberculose

Fístula anal

Tratamento antituberculose

\* Corresponding author.

E-mail: [msahuvns@gmail.com](mailto:msahuvns@gmail.com) (M. Sahu).

<http://dx.doi.org/10.1016/j.jcol.2017.04.005>

2237-9363/© 2017 Sociedade Brasileira de Coloproctologia. Published by Elsevier Editora Ltda. This is an open access article under the CC BY-NC-ND license (<http://creativecommons.org/licenses/by-nc-nd/4.0/>).

prospectivo teve por objetivo consubstanciar a importância do diagnóstico clínico e também do tratamento clínico da fistula TB com medicamentos contra tuberculose.

**Métodos e resultados:** Foi realizado estudo histopatológico de tratos fistulosos em 25 pacientes com fistula anal com suspeita de origem tuberculosa; depois de obtido o consentimento livre e informado, esses pacientes foram submetidos a tratamento anti-tuberculose (TAT) durante 8 semanas. Embora a biópsia tenha revelado evidência positiva de patologia tuberculosa em apenas 52% dos casos, o curso terapêutico resultou em melhora nos aspectos local e sistêmico em 23 (92%) pacientes. Desses 23 casos, 3 e 18 casos estavam curados após 18 e 24 meses de TAT, respectivamente, enquanto que 2 pacientes desistiram do estudo após 12 e 14 meses, respectivamente, em decorrência de reações farmacológicas adversas, mesmo diante do alívio de seus sintomas fistulosos.

**Conclusão:** Juntamente com outros métodos diagnósticos, uma avaliação clínica metódica desempenha papel vital no diagnóstico da fistula TB. TAT é o principal procedimento terapêutico em pacientes com fistula TB, com duração mínima de 18-24 meses devido à natureza recorrente e recidivante da doença.

© 2017 Sociedade Brasileira de Coloproctologia. Publicado por Elsevier Editora Ltda. Este é um artigo Open Access sob uma licença CC BY-NC-ND (<http://creativecommons.org/licenses/by-nc-nd/4.0/>).

## Introduction

Tuberculosis (TB) is one of the leading causes of death worldwide particularly in developing countries, ranking alongside HIV/AIDS. According to WHO Annual Report 2016, 9.6 million people suffered with tuberculosis globally in 2014 and India shared the largest number of cases in the south-east Asian region with prevalence and incidence of 2.5 and 2.2 million respectively.<sup>1</sup> Tubercular manifestations can be of two types: pulmonary (PTB) and extra pulmonary (EPTB). Though pulmonary infections are more commonly encountered, extrapulmonary forms have also been a matter of concern since long. In India, 20% of all TB cases are extrapulmonary forms.<sup>2</sup> Though vascular areas like lymph nodes, meninges, kidney, spine and growing ends of bones are commonly involved sites in EPTB; pleura, pericardium, peritoneum, liver, gastrointestinal tract (GIT), genitourinary tract and skin may also be involved.<sup>3</sup> GI tuberculosis accounts for 1-3% of extrapulmonary cases,<sup>4</sup> which may be primary due to ingestion of *M. bovis* strain or may be secondary due to a primary focus elsewhere which is usually pulmonary. Tuberculosis of anoperineal region is a relatively rare form of EPTB which may often manifest in the form of anorectal abscesses, fistula and in some cases, may also present with anal stenosis.

TB is often a neglected cause of anorectal sepsis which usually remains unrecognized leading to recurrence of anal fistulae even after multiple surgeries. Although fistula in ano is a surgical disease, tubercular fistulae often present as an exception to this and can be managed effectively by proper antitubercular chemotherapeutic treatment. This paper describes a prospective series of tubercular fistula in ano where the patients were primarily managed medically and the outcomes have been reported.

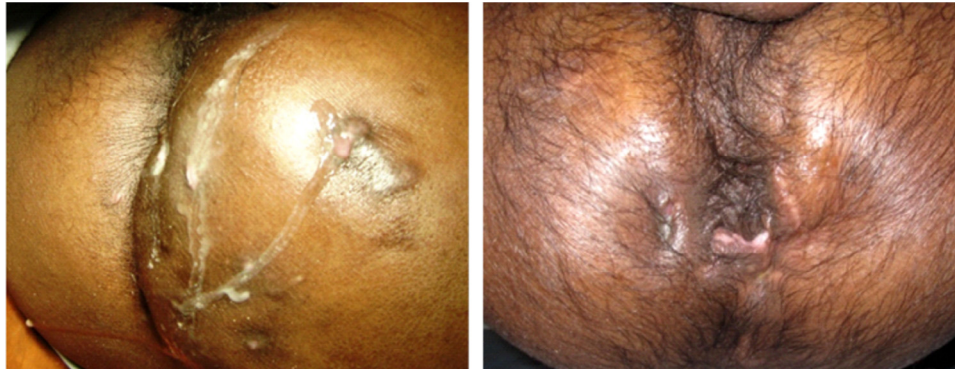## Methods

This prospective study included 25 patients of tubercular fistula in ano who attended the Ano-rectal clinic at Sir Sunder Lal

Hospital, Banaras Hindu University, Varanasi, India from June 2012 to July 2016. Unlike all other types of EPTB, there are no specific symptomatology or investigative findings attributed to tubercular fistula in ano and so, the diagnosis was made especially on the basis of clinical grounds, both on local as well as systemic presentation. Non-crypto glandular origin of fistula in ano, recurrent nature of fistulae, multiple fistulae not linked to each other (tracks not communicating to each other), fistula with multiple external openings, thin caseous discharge, undermined edges of external opening, progressive anorectal stenosis and inguinal lymphadenopathy arouse suspicion of tubercular fistula in ano (Fig. 1).

Constitutional symptoms like low grade fever especially in the evening hours, anorexia and weight loss with features of anemia are the other features which further strengthen the doubt of a tubercular pathology, however all these symptoms were not present in all cases.<sup>5,6</sup> All patients underwent routine hematological investigations which included hemogram with ESR, blood sugar levels, liver function tests, serum urea-creatinine estimation along with serological testing for HIV and HBsAg status. Digital chest radiography and Mantoux testing was done. Sigmoidoscopy was performed to rule out inflammatory and other bowel pathologies. In addition to this, biopsy of the tissue excised from the core of the fistulous track was sent for histopathological examination. After confirming the diagnosis by histopathology, antitubercular treatment was started according to body weight on daily dosage pattern. The regime is shown in Table 1.

In cases, where the histological findings were not suggestive of tubercular pathology but the clinical sign and symptoms were in agreement of tuberculosis, a therapeutic trial of anti-tubercular treatment (ATT) was started for 8 weeks duration with 6 drugs (Table 1) and the treatment was further continued or ceased depending on the response of the patient. Informed consents were taken from all the patients prior to the inception of treatment. Patients were evaluated clinically at three months interval during the course of study and the cessation of CP was decided on the basis of healing of fistula in terms of a discharge free period for more than one year as



**Fig. 1 – Clinical photographs showing caseating discharge from multiple external openings of tubercular fistula (left) and recurrent fistula in ano with multiple external openings and stenosis at anorectal junction (right).**

**Table 1 – Regime of antitubercular treatment for tubercular fistula in ano.**

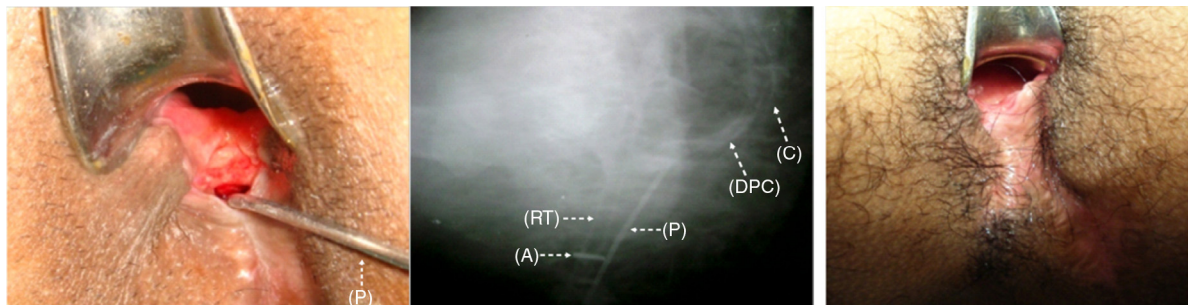
Phase	Duration (months)	Drugs (dose)
Intensive (IP)	3	Isoniazid (H; 5 mg/kg), rifampicin (R; 10 mg/kg), pyrazinamide (Z; 25 mg/kg), ethambutol (E; 15 mg/kg), streptomycin (S, 750 mg), moxifloxacin (400 mg)
	3	HRZE + moxifloxacin (400 mg)
Continuation (CP)	12-18	HRE

well as improvement in systemic complaints and weight gain (Fig. 2).

**Results**

The study included 23 males and 2 females with mean age of 36.8 years (range 18-72 years). 44% cases were of recurrent fistula and 20% of the total cases presented with anal stenosis at the level of anorectal junction. No anal crypt involvement could be elicited in any of the patient on clinical examination. Sigmoidoscopy did not reveal the presence of inflammatory

bowel disease (IBD) in any of the cases. 3 (12%) patients had a positive past history of antitubercular treatment for 6-9 months for pulmonary tuberculosis and their chest radiographs showed evidence of previous pulmonary tubercular involvement. 32% patients had constitutional symptoms like evening rise of temperature, anorexia and weight loss. ESR was raised in all cases with an average of 54.5 mm/1st hour by Westergren method. Mantoux test was positive in 8 (32%) patients with more than 15 mm induration size measured after 72 h of tuberculin injection. On histopathological examination of the tissue biopsy obtained from the fistulous track, 13 (52%) cases showed presence of granulomatous pathology with caseating necrosis and Langhans giant cells, thus confirming the diagnosis of tuberculosis and hence, ATT was started in them. Among the biopsy negative cases, an 8 week therapeutic trial of ATT was started. Two patients did not respond to the therapeutic trial. Their anti tubercular chemotherapy was discontinued and the cases were managed by surgical intervention and medicated seton (ksharsutra) therapy. The remaining ten patients responded to ATT and thus, a total of 23 (92%) cases underwent and completed the 6 months intensive phase (IP) schedule. During the continuation phase (CP), 2 patients discontinued the treatment themselves at the end of 6 months and 8 months due to adverse reactions like arthralgia, lethargy, nausea, vomiting etc. and did not turn up for further follow up, however their fistulous symptoms



**Fig. 2 – Clinical photograph of patient presented with post surgical recurrence of fistula in ano. Fistulous opening with ulceration may be seen located at mucocutaneous junction in posterior midline with malleable silver probe (P) extending in deep post anal space (left). Fistulogram (lateral view) of same patient depicts track with deep post anal space collection (DPC) extending close to the tip of coccyx (C). Anal verge being marked by anal marker (A) on the rubber tube (RT) placed inside the anal canal (middle). Healed fistula of the same patient following antitubercular treatment (right).**

were relieved. In the rest 21 (84%) cases, 3 patients underwent a 12 month CP while 18 underwent an 18 month CP. Thus, 3 patients completed a course of ATT for 18 month while 18 patients underwent a 24 months course of ATT.

## Discussion

Anal tuberculosis is a rarely encountered form of extrapulmonary tubercular involvement. As the incidence of primary GIT tuberculosis has declined due to the preferred use of pasteurized milk, tuberculosis of anal region is usually secondary to a primary focus elsewhere which is more often pulmonary.<sup>6</sup> The probable method of infection of the anorectal region may be due to swallowing of sputum infected with tubercular bacilli which may enter the anal or perianal tissue through a minute abrasion in the lining of the anal canal. Infection may also occur as a direct inoculation of tubercle bacilli during anal toilet on to the excoriations or cracks in the anal or perianal skin from the patient's finger, contaminated by contact with his own infected sputum. More rarely, a hematogenous or lymphatic spread may also occur leading to the lodging of tubercular bacillus in the perianal or ischioanal tissues.<sup>7</sup> The disease may have varied presentation including the formation of fistulae, perianal or mucosal ulcerations, firm and annular strictures or submucosal nodular form with ulceration. It may also be presented in verrucous form with smooth warty appearance.<sup>8</sup> Suppurations and fistulae are, however, the most frequently encountered lesions.<sup>9</sup>

Though the recommendations are that EPTB should be diagnosed bacteriologically, histopathologically or on clinical judgment of treating specialists but in most cases, diagnosis of EPTB has been found to be made on clinical grounds<sup>2,10</sup> and it raises the difficulty among the clinicians with varying degree of experience in fistula in ano treatment. So, the problems of a missed or overdiagnosis of tubercular fistula are common in practice. It has been observed that ATT is advised empirically in cases of recurrent fistula in ano at several occasions considering it tubercular in nature which is however not justified because recurrence after surgical treatment is not uncommon specially in complex fistula in ano due to several reasons like missed sepsis, inability to correctly identify the internal opening or the site of cryptoglandular infection etc. A high index of clinical understanding of both local as well as systemic features is required for making a diagnosis of tubercular fistula as described earlier. Constitutional features like anorexia, fever, weight loss etc. however, may not always be present<sup>6</sup> as only 32% patients presented with such symptoms in this study also. The diagnosis can be confirmed by positive *Mycobacterium tuberculosis* (MTB) culture in the pus sample but being a paucibacillary disease, the yield and the sensitivity of the test is low. Moreover, it generally takes about 2-3 months to obtain the culture results which may delay the commencement of treatment. Also, MTB culture is difficult in cases where the main presenting feature is anorectal stenosis with no or little discharge. So, the diagnosis depends mainly upon the histopathological evidence and hence, the excised tissue from fistulous tract should always be sent for histopathological examination in all suspected cases. Presence of giant cell (Langhans type) granulomas with epithelioid cell infiltration,

caseating necrosis and demonstration of AFB are positive histological evidences but these may not be always present and a low host immunity may result in more inflammatory or suppurative response on histological findings.<sup>11</sup> Biopsy may be repeated in some cases as tuberculous lesions may be submucosal in nature and may be missed in the section studied.<sup>12</sup> In the present study also, histological evidence could not be found in 48% cases but a therapeutic trial of ATT based on the clinically suspected features showed successful results which approved the diagnosis and the treatment was continued. The investigations like Mantoux testing and Quantiferon TB Gold may aid to the diagnosis but their value is questioned. The value of Mantoux test is limited in adults in India as about 40% of the adult population is infected with TB.<sup>13</sup> Since there have been no validated hematological biomarkers suggested that can detect TB, the role of blood based antibody tests or interferon gamma release assays such as TB Gold and TB platinum is questionable.<sup>14</sup> Nucleic acid amplification tests (NAAT) like polymerase chain reaction (PCR) testing using pus and tissue specimen may be useful in rapid detection of the disease but the sensitivity is low and variable in EPTB case samples and require a multiple sample testing.<sup>11</sup> In 2013, WHO endorsed the use of Xpert MTB/RIF assay, a cartridge based NAAT for extrapulmonary cases, which allows for rapid detection of MTB DNA along with confirmation of rifampicin resistance.<sup>15</sup> Various studies have shown that even tissue biopsies can be used as a sample for the diagnosis of tuberculosis by this test. MRI and Transrectal ultrasonography may be helpful in understanding the course and extent of disease while MRI can also reveal the fibrosis and stricture formation which usually occur within 10 cm from anal verge by detecting the increased presacral space in such cases.<sup>16,17</sup> Crohn's disease is an important differential diagnosis wherein a non caseating granuloma is found in histology and a lower GI endoscopy may be helpful in suspected cases.

As the diagnosis of a fistula in ano heralds the need of a surgical treatment, the role of surgery in tubercular fistula cases is limited to drainage of an abscess, obtaining samples for histopathological examinations or in extreme cases, for correction of the stenosis which if persist after a full course of ATT. The mainstay of treatment of tubercular fistula in ano is the antitubercular chemotherapeutic treatment. However, the issue of the ideal regimen and duration of treatment in EPTB is yet to be resolved. Though a 6 months ATT course (2 months IP with HRZE and 4 months CP with HR) is recommended in all new severe forms of EPTB (which includes GI tuberculosis),<sup>18,19</sup> it is always advisable to start with 4-6 drugs in IP and at least 3 drugs in CP in tubercular fistulae. Since relapse in cases of tuberculous fistula in ano is high due to delayed diagnosis and recurrent nature of disease and a slow response to treatment like that of resistant cases has been observed, the treatment strategy planned was containing both first line as well as second line (fluoroquinolone) drugs. Also, the duration of treatment was increased but was not fixed and decided on the basis of clinical response of the patient because in EPTB cases, each patient is needed to be assessed individually and treatment duration may need to be extended.<sup>20</sup> IP was continued for 6 months and after careful assessment, the CP was started. There are recommendations that the duration of CP may be extended by three to six months

in special situations like bone and joint TB, spinal TB with neurological involvement, etc.<sup>21</sup> Tubercular fistulae are also similar to these special situations due to factors like slow response to treatment and tendency for relapse or recurrence. Hence, an extension of CP may be done on the basis of clinical assessment. The help of radiological and other relevant investigations may also be taken. In our experience, total duration of treatment for tubercular fistula should never be less than 18 months; rather in difficult and complicated cases, the duration may be increased up to 24 months or till satisfactory clinical response is achieved. Although the daily and intermittent regimens have shown equal chemotherapeutic efficacy, the daily regimen should be the choice in tubercular fistula. Recent guidelines under revised national tuberculosis control programme (RNTCP) also advocates for daily regimen.<sup>21</sup> There are no clear cut guidelines for end point of treatment in EPTB cases; however, in cases of tubercular fistula, improvement in systemic features, weight gain and healing of fistula may be taken as the end point of treatment.

## Conclusion

Diagnosis of tubercular fistula is still a big challenge and it is difficult to establish in a fair number of cases despite of available diagnostic tools. A meticulous clinical observation along with non cryptoglandular origin of fistula plays an important role in cases where histological evidences are not supportive for tuberculosis. It is primarily a medical condition and surgical intervention is seldom required. ATT should not be initiated merely on the basis of recurrent nature of disease and there should be adequate clinical evidence and/or investigative support to start antitubercular treatment. However, the regime and duration of treatment should be judiciously decided individually on the basis of response to the treatment and preferably, it should not be less than 18–24 months. A high index of clinical suspicion, judicious use of diagnostic methods for confirmation of diagnosis and proper regime in terms of dose and duration with regular follow up and assessment are the keys to success.

## Conflicts of interest

The authors declare no conflicts of interest.

## REFERENCES

1. Tuberculosis control in South-East Asia Region: annual report 2016. New Delhi: Regional office for South East Asia, World Health Organization; 2016.
2. Arora VK, Chopra KK. Extrapulmonary tuberculosis. *Indian J Tuberc.* 2007;54:165–7.
3. Wares F, Balasubramanian R, Mohan A, Sharma SK. Extrapulmonary tuberculosis: management and control. In: Agarwal SP, Chauhan LS, editors. *Tuberculosis control in India*. New Delhi: Directorate General of Health Services, Ministry of Health and Family Welfare; 2005. p. 95–114.
4. Haines CF, Sears CL. Infectious enteritis and proctocolitis. In: Feldman M, Friedman LS, Brandt LJ, editors. *Sleisenger and Fordtran's gastrointestinal and liver disease*. 10th ed. Philadelphia (USA): Elsevier Saunders; 2016.
5. Mishra JK, Sahu M, Sharma A. Non cryptoglandular fistula in ano. In: Sahu M, editor. *A manual on fistula in ano and ksharsutra therapy*. Varanasi (India): National Resource Center on Ksharsutra Therapy; 2015. p. 154–63.
6. Gupta PJ. Tuberculosis fistulas. In: Abcarian H, editor. *Anal fistula: principles and management*. New York: Springer Science + Business Media; 2014.
7. Gupta PJ. Ano-perianal tuberculosis – solving a clinical dilemma. *Afr Health Sci.* 2005;5:345–7.
8. Rai RR, Nijhawan S, Bhargava N, Nepalia S, Pokhrana DS. Rectal tuberculosis – a case report. *Indian J Med Res.* 1993;111:35–7.
9. Romelaer C, Abramowitz L. Anal abscess with a tuberculous origin: report of two cases and review of the literature. *Gastroenterol Clin Biol.* 2007;31:94–6.
10. Shukla HS, Gupta SC, Singh G, Singh PA. Tubercular fistula in ano. *Br J Surg.* 1988;75:38–9.
11. Lee JY. Diagnosis and treatment of extrapulmonary tuberculosis. *Tuberc Respir Dis.* 2015;78:47–55.
12. Rasheed S, Zinicola R, Watson D, Bajwa A, McDonald PJ. Intra-abdominal and gastrointestinal tuberculosis. *Colorectal Dis.* 2007;9:773–83.
13. Revised National Tuberculosis Control Programme. Technical guidelines for tuberculosis control. New Delhi: Central TB Division, Directorate General of Health Services, Ministry of Health and Family Welfare, Government of India; 1997.
14. Pai M, Nathavitharana R. Extrapulmonary tuberculosis: new diagnostics and new policies. *Indian J Chest Dis Allied Sci.* 2014;56:71–3.
15. Xpert MTB/RIF assay for the diagnosis of pulmonary and extrapulmonary TB in adults and children. Policy update. Geneva: World Health Organization; 2013.
16. Sharma MP, Bhatia V. Abdominal tuberculosis – review article. *Indian J Med Res.* 2004;120:305–15.
17. Taieb ABPM. Tuberculosis of rectum mimicking malignancy: a case report and review of literature. *Abdom Surg.* 2013.
18. Standards for TB care in India. New Delhi: country office for India. World Health Organization; 2014.
19. Balasubramanian R, Rajeshwari R, Santa T. How does management of extra pulmonary tuberculosis differ from that of pulmonary tuberculosis? In: Frieden T, editor. *Toman's tuberculosis*. Geneva: World Health Organization; 2004. p. 162–5.
20. Sharma SK, Mohan A. Extrapulmonary tuberculosis. *Indian J Med Res.* 2004;120:316–53.
21. Revised National TB Control Programme, Technical and operational guidelines for tuberculosis control in India 2016. New Delhi: Central TB Division, Directorate General of Health Services, Ministry of Health and Family Welfare, Government of India; 2016.