



## Case Report

# Perianastomotic cyst following rectosigmoidectomy due to adenocarcinoma of the proximal rectum: a case report

Fernando Simões de Sena <sup>a,\*</sup>, Raquel Ferreira Nogueira<sup>a</sup>, Lorena de Oliveira Barroso<sup>b</sup>, Marco Antônio Miranda dos Santos<sup>c</sup>, Sinara Mônica de Oliveira Leite<sup>c</sup>

<sup>a</sup> Hospital Governador Israel Pinheiro, Belo Horizonte, MG, Brazil

<sup>b</sup> Hospital Vila da Serra, Belo Horizonte, MG, Brazil

<sup>c</sup> Hospital Governador Israel Pinheiro, Serviço de Coloproctologia, Belo Horizonte, MG, Brazil

## ARTICLE INFO

## Article history:

Received 27 February 2020

Accepted 30 May 2020

Available online 20 June 2020

## Keywords:

Low anterior resection

Colorectal surgery

Perianastomotic cyst

Inclusion cyst

Endoscopic drainage

## ABSTRACT

The implantation cyst occurs from the imprisonment and subsequent proliferation of the colonic mucosa below the submucosa during mechanical stapling. The understanding and definition of the evaluation protocol of these lesions is important, since they can generate the need for a new complex surgical procedure and cause anxiety in patients and surgeons. This case reports the occurrence of a subepithelial lesion in follow-up imaging of a patient who underwent videolaparoscopic rectosigmoidectomy for adenocarcinoma of the proximal rectum, submitted to an endoscopic attempt to drain/detangle the lesion and subsequent histopathological analysis showing colic mucosa without changes. In line with Katsumata, it is suggested to asymptomatic patients without alteration of the CEA or suspicious imaging signs a follow up with periodic imaging methods. For symptomatic patients with normal CEA, or whose lesions are growing at follow-up exams, it is suggested to continue with the investigation, with biopsy and/or effluent sample for histopathological study in addition to an attempt at symptomatic resolution. Finally, in the presence of an alteration in CEA, despite symptoms, it is suggested that the lesion be managed as a suspected local tumor recurrence.

© 2020 Published by Elsevier Editora Ltda. on behalf of Sociedade Brasileira de Coloproctologia. This is an open access article under the CC BY-NC-ND license (<http://creativecommons.org/licenses/by-nc-nd/4.0/>).

## Cisto perianastomótico pós-retossigmoidectomia por adenocarcinoma de reto alto: relato de caso

## RESUMO

O cisto de implantação ocorre a partir do aprisionamento e subsequente proliferação da mucosa colônica abaixo da submucosa durante o grampeamento mecânico. A compreensão

## Palavras-chave:

Ressecção baixa anterior

\* Corresponding author.

E-mail: [editoracaratinga@hotmail.com](mailto:editoracaratinga@hotmail.com) (F.S. Sena).

<https://doi.org/10.1016/j.jcol.2020.05.018>

2237-9363/© 2020 Published by Elsevier Editora Ltda. on behalf of Sociedade Brasileira de Coloproctologia. This is an open access article under the CC BY-NC-ND license (<http://creativecommons.org/licenses/by-nc-nd/4.0/>).

Cirurgia colorretal  
Cisto perianastomótico  
Cisto de inclusão  
Drenagem endoscópica

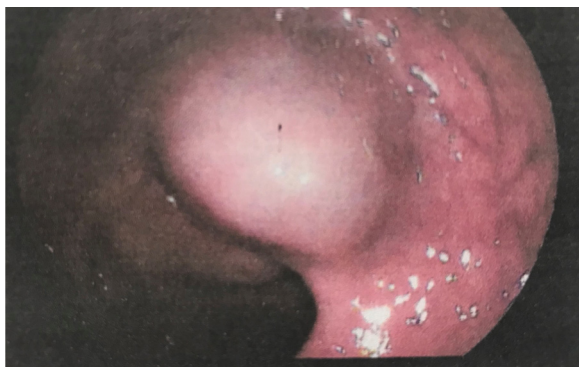e definição do protocolo de avaliação dessas lesões é importante, pois podem gerar a necessidade de um novo procedimento cirúrgico complexo e causar ansiedade em pacientes e cirurgiões. Este caso relata a ocorrência de uma lesão sub-epitelial na imagem de seguimento de um paciente submetido à retossigmoidectomia por via videolaparoscópica devido a adenocarcinoma do reto proximal, submetido a uma tentativa endoscópica de drenar/remover a lesão e subsequente análise histopatológica mostrando a mucosa cólica sem alterações. De acordo com Katsumata, sugere-se que pacientes assintomáticos sem alteração do CEA ou sinais de imagem suspeitos tenham um seguimento com métodos de imagem periódicos. Para pacientes sintomáticos com CEA normal, ou cujas lesões mostrem crescimento nos exames de seguimento, sugere-se continuar a investigação, com biópsia e/ou amostra de efluente para estudo histopatológico, além de uma tentativa de resolução sintomática. Finalmente, na presença de uma alteração no CEA, apesar dos sintomas, sugere-se que a lesão seja tratada como uma suspeita de recorrência local do tumor.

© 2020 Publicado por Elsevier Editora Ltda. em nome de Sociedade Brasileira de Coloproctologia. Este é um artigo Open Access sob uma licença CC BY-NC-ND (<http://creativecommons.org/licenses/by-nc-nd/4.0/>).

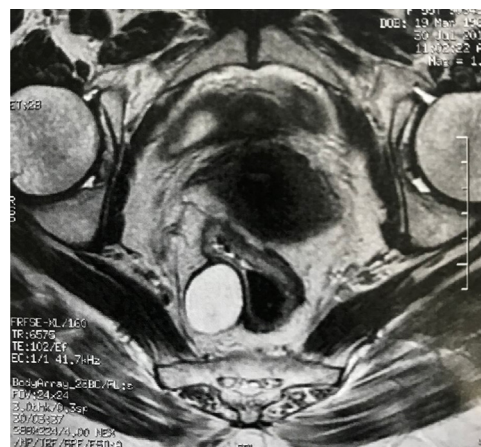
## Case report

M.D.S., 55 years old, on oncological surveillance after being submitted to a videolaparoscopic rectosigmoidectomy, without reports of complications, in another hospital in 2016, due to neoplastic lesion in the upper rectum. Histopathology of the surgical specimen disclosed moderately differentiated, invasive, stage T3 adenocarcinoma, with dissection of 16 lymph nodes without nodal involvement, free surgical margins and microsatellite stability.

In March 2018, she reported, after 2 years of follow-up, diarrhea twice a month, more than five liquid bowel movements / day, with mucus, without blood. She denied associated systemic symptoms, with normal bowel habits in the intervals. Normal proctological examination. The rectosigmoidoscopy showed a wide anastomosis and no alterations. Colonoscopy and CTs of the chest and abdomen were requested. Colonoscopy (04/19/2018): up to the terminal ileum, with good intestinal preparation. Patent anastomosis at 10 cm from the anal border. Subepithelial lesion depressible to touch, measuring 30 mm, bulging into the rectal lumen. Normal overlying mucosa (Fig. 1). Chest and abdomen CTs showed no alterations (carcinoembryonic antigen (CEA) = 2.8/urinary routine tests without alterations; CRP = 6.08/LG 5600).



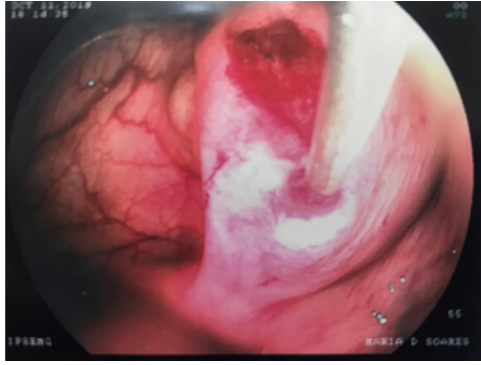
**Fig. 1 – Perianastomotic lesion discovered in a follow-up colonoscopy.**



**Fig. 2 – Perianastomotic lesion evaluation by MRI.**

Pelvic MRI (07/30/2019): Lobulated cystic formation, finely septated, right posterior pararectal region, at the level of the anastomosis, without cleavage plane with the rectal wall, measuring  $5 \times 3 \times 2.4$  cm, partially obstructing the lumen (Fig. 2). At the time, persistent diarrhea, with 2-3 episodes/week. Colonoscopic drainage was chosen, which confirmed a subepithelial lesion with an overlapping tattoo (Fig. 3). An attempt was made to drain it with an injector catheter, overlapping biopsies with biopsy tweezers and detachment of the lesion, without success. It was achieved through transanal puncture under view, and a sample of the lesion content, which had a mucoid aspect and residual volume was sent for laboratory analysis along with a fragment of the cyst wall.

The anatomopathological examination of the cyst wall disclosed histologically nonspecific, mild chronic colitis, and it was decided to maintain the patient under follow-up, based on the absence of symptoms.



**Fig. 3 – Attempt of transanal drainage of the perianastomotic lesion using a needle, during colonoscopy.**

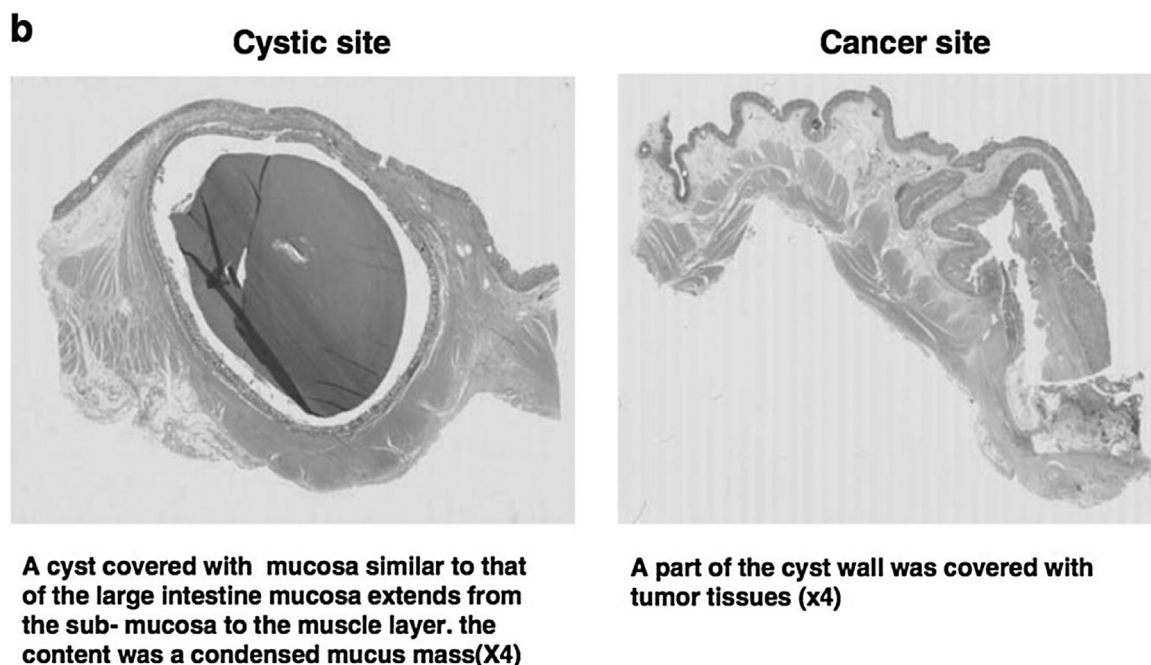
## Discussion

It has been proposed that the implantation cyst occurs from the imprisonment of the colonic mucosa below the submucosa during mechanical stapling, with the viability of the mucous tissue and its proliferation, similar to what occurs in a lipped fistula or in the tissue proliferation occasionally seen in colostomy edges. The generation of a closed environment after the tissue is cut by the stapler explains the cyst formation, through the continuous production of mucus. As described by Dukes and Shindo,<sup>1,2</sup> it is important to understand and define an evaluation protocol for this lesion, as it may generate the need for a new complex surgical procedure and result in anxiety for patients and surgeons.

Katsumata et al.<sup>3</sup> performed a retrospective systematic review on the occurrence of perianastomotic cysts after anterior rectal resection (ARR), based on a case similar to the one described above, as they identified a lack of studies in

the literature review on the subject. The authors found 448 patients, between 1996 and 2006, who underwent ARR, identifying 9 perianastomotic cysts. Of these cases, two underwent therapeutic intervention. The first patient underwent videolaparoscopic lowering due to a significant increase in CEA together with symptoms of tenesmus and serial evacuations during oncological follow-up. The histopathological analysis of the patient's surgical specimen showed two lesions: one measuring 13 mm, surrounded by colic mucosa, extending from the submucosal to the muscular layer, containing a collection of concentrated mucus with calcified deposits, suggestive of an implantation cyst; and the other, measuring 20 × 15 mm, with components suggestive of a solid tumor, covered by little to moderately differentiated adenocarcinoma (Fig. 4). The second patient was submitted to treatment due to symptoms affecting his quality of life. With CEA level within normal limits during follow-up and imaging aspects showing good prognosis, lesion puncture and fenestration by colonoscopy was chosen, with clear mucoid drainage, similar to that found in the present case. This patient underwent two drainage attempts on the first occasion, with remission of the lesion and symptoms, but showed symptomatic and lesion recurrence after 5 months. He was then submitted to a new drainage via the same route and subsequently maintained under follow-up. As for the other 7 patients, as they did not show any symptoms or CEA alteration, it was decided to maintain them under oncological follow-up, without interventions. The follow-up periods varied from 2 years and 11 months to 9 years and 9 months, without complications.

In agreement with what was reported by Katsumata, we attempted to study the lesion through aspiration puncture and oncotic cytological evaluation, based on the patient's manifestation of symptomatology and the growth of the finding in serial imaging exams that occurred without CEA levels



**Fig. 4 – Histopathological analysis performed by Katsumata in his study, in 2010.**

elevation, which showed: histopathological tissue analysis compatible with colonic mucosa, without alterations.

---

### Conclusion

Therefore, a follow-up with imaging methods for asymptomatic patients and no alteration in CEA levels or suspicious imaging signs is suggested. For symptomatic patients, but with normal CEA, or whose lesions show growth at follow-up exams, it is suggested to continue with the investigation, with an effluent biopsy and /or sample for histopathological study, in addition to an attempt at symptomatic resolution. Finally, in the presence of CEA alterations, despite the presence of symptoms, it is suggested that the lesion be managed as a suspected local tumor recurrence.

---

### Conflicts of interest

The authors declare no conflicts of interest.

---

### REFERENCES

1. Dukes C. Submucous implantation cysts of the rectum. *Proc R Soc Med.* 1929;22:715–8.
2. Shindo K. A mucocele in the anal canal. *Am J Proctol.* 1972;23:235–9.
3. Katsumata K, Mori Y, Kawakita H, Matsuda D, Enomoto M, Aoki T. A study of incidence of implantation cyst at anastomotic sites after low anterior resection of the rectum with the double stapling technique. *Langenbecks Arch Surg.* 2010;395:465–9.