


# Detection of Upper Gastrointestinal Disorders in Patients with Positive Fecal Immunochemical Test (FIT) and Normal Colonoscopy: A Cross-Sectional Study

Sahar Ravanshad<sup>1,\*</sup>  Atefeh Golhasani<sup>1,\*</sup> Hassan Mehrad-Majd<sup>2</sup> Mohammadhossein Taherynejad<sup>3</sup>   
Ali Beheshti Namdar<sup>4</sup>

<sup>1</sup> Department of Internal Medicine, Faculty of Medicine, Mashhad University of Medical Sciences, Mashhad, Iran

<sup>2</sup> Cancer Molecular Pathology Research Center, Mashhad University of Medical Sciences, Mashhad, Iran

<sup>3</sup> Student Research Committee, Faculty of Medicine, Mashhad University of Medical Sciences, Mashhad, Iran

<sup>4</sup> Department of Gastroenterology and Hepatology, Faculty of Medicine, Mashhad University of Medical Sciences, Mashhad, Iran

**Address for correspondence** Ali Beheshti Namdar, Assistant Professor, Narjes BLDG, Qaem Hospital, Ahmadabad ST, Mashhad, Iran (e-mail: BeheshtiA@mums.ac.ir).

J Coloproctol 2024;44(1):e17–e21.

## Abstract

**Introduction** Colorectal cancer (CRC) is the second most prevalent cancer in the world, and the fecal immunochemical test (FIT) can be mentioned among the CRC screening methods based on the detection of occult blood in the feces, which may indicate upper gastrointestinal (UGI) malignancies; therefore, patients with a positive FIT but normal colonoscopy may be considered for a UGI endoscopy.

**Materials and Methods** The present study was conducted on patients with a positive FIT who were submitted to colonoscopy with normal results. They subsequently underwent endoscopy for the detection of UGI disorders.

**Results** We included 121 patients (64.5% of women and 35.5% of men; average age:  $58.85 \pm 12.93$  years), 72.7% of whom were positive for *Helicobacter pylori*. The predominant result of the UGI endoscopy was normal, followed by erythema of the gastric mucosa, and anemia and dyspepsia were the most common clinical findings. The most common pathological result was chronic gastritis, followed by acute gastritis. Only one patient presented stomach cancer (adenocarcinoma).

**Conclusion** Considering the small prevalence of cancer in the UGI endoscopies of patients with positive FIT and normal colonoscopy, to the performance of UGI endoscopy in these patients may not be necessary.

## Keywords

- ▶ fecal immunochemical test
- ▶ cancer
- ▶ colonoscopy
- ▶ *Helicobacter pylori*

\* These authors contributed equally to the present study.

received  
August 29, 2023  
accepted after revision  
January 10, 2024

DOI <https://doi.org/10.1055/s-0044-1785212>.  
ISSN 2237-9363.

© 2024. The Author(s).

This is an open access article published by Thieme under the terms of the Creative Commons Attribution 4.0 International License, permitting copying and reproduction so long as the original work is given appropriate credit (<https://creativecommons.org/licenses/by/4.0/>).  
Thieme Revinter Publicações Ltda., Rua do Matoso 170, Rio de Janeiro, RJ, CEP 20270-135, Brazil

## Introduction

Colorectal cancer (CRC) is the second most prevalent cancer in the world. With the use of screening methods, this disease can be detected in its early stages, leading to prevention of severe clinical outcomes.<sup>1</sup> If CRC is detected early, the 5-year survival rate is of 93.2%, whereas the same rate for individuals with metastatic disease is of only 8.1%.<sup>2</sup> Based on existing guidelines, CRC screening is recommended in individuals > 50 years of age. The diagnostic tests for CRC screening present varying levels of sensitivity, specificity, effectiveness, accessibility, and costs. Patients who receive a positive screening result through a method other than colonoscopy must undergo a routine colonoscopy evaluation to confirm the presence of adenomatous polyps or CRC.<sup>3</sup> Among the CRC screening methods based on the detection of occult blood in the feces, the fecal immunochemical test (FIT) can be mentioned. Since it is specifically used to identify human globulin, it presents few false positive cases. The FIT is considered a suitable method for CRC screening due to its high diagnostic accuracy and ease of performance; furthermore, with the positive result, the patient becomes a colonoscopy candidate.<sup>4</sup> Despite being considered a suitable diagnostic method for patients with a positive FIT, > 50% of patients undergoing colonoscopy present normal results.<sup>5</sup> Since the presence of blood in the stool detected by the FIT can indicate possible upper gastrointestinal (UGI) malignancies, patients with a positive FIT but normal colonoscopy results may be considered for a UGI endoscopy. Previous studies have produced conflicting results regarding the need to perform a UGI endoscopy in patients with normal colonoscopy findings and fecal occult blood. Zappa et al.<sup>6</sup> reported that the positive predictive value (PPV) of the fecal occult blood test (FOBT) for gastric cancer is of 0.4%. It seems that this percentage cannot be completely ignored, but the diagnosis must be established according to clinical symptoms and the existence of family and regional risk factors. According to a recent study conducted in the United States by Robertson et al.<sup>7</sup> on screening using the FIT, in cases in which there are no symptoms of the upper digestive system, despite the positive FIT and the absence of pathological findings on the colonoscopy, UGI endoscopy is not recommended. Furthermore, most of these studies have primarily used the FOBT, while studies exploring the application of the FIT in this context remain limited.<sup>8</sup> The objective of the present study was to assess the available evidence and offer recommendations concerning the use of routine esophagogastroduodenoscopy (EGD) for the detection of UGI cancers. The focus is on patients who are participating in a population-based CRC screening program, have tested positive on the FIT, and have received a negative colonoscopy result.

## Materials and Methods

The present study was conducted between 2018 and 2021 at the endoscopy center of 2 referral hospitals in Mashhad, Iran. The demographic, clinical, and endoscopic data of 121 patients who had a positive FIT, were submitted to colonoscopy with

**Table 1** General information of the studied patients

Variable	n (%)	
Gender	Male	43 (35.5)
	Female	78 (64.5)
Familial history of cancer	5 (4.1)	
Positive result for <i>Helicobacter pylori</i> on the blood test	88 (72.7)	

normal results, and subsequently underwent endoscopy were extracted and analyzed. The exclusion criteria were individuals with a history of gastrointestinal malignancy, individuals with a history of malignancy that has metastasized, and those who have recently undergone endoscopy and obtained normal results within the last six months.

The data of all eligible patients were collected from the archives of the Endoscopy Department, and they were analyzed considering demographic, clinical, and endoscopic details. The checklist of the researcher was used to extract and document demographic information, such as age, gender, residential area, family history of gastrointestinal malignancy, as well as clinical data, including data on anemia, dyspepsia, and weight loss. The endoscopic findings of these patients were also recorded.

The current research was presented on July 6, 2021 to the Organizational Ethics Committee of the Mashhad University of Medical Sciences. The study protocol was approved under the code IR.MUMS.MEDICAL.REC.1400.369.

## Results

We included 121 patients: 78 women (64.5%) and 43 men (35.5%), with an average age of  $58.85 \pm 12.93$  years. **Table 1** provides an overview of the general information of the study sample.

In the analysis (**Fig. 1**), anemia (9.9%) was the predominant clinical finding, followed by dyspepsia (6.6%). The frequency of the UGI endoscopy results is listed in **Fig. 2**. As observed, the predominant findings of the UGI endoscopy were normal (60.3%), followed by erythema of the gastric mucosa (19%), making it the most commonly observed result.

We were able to access the pathology of 39 patients. The frequencies of the pathology results of the UGI endoscopy biopsies are listed in **Fig. 3**, which evidences that chronic gastritis (13.2%) was the most prevalent pathological result, followed by acute gastritis (9.9%). There was only one case of stomach cancer (adenocarcinoma) identified among the patients. The frequency distribution of endoscopy results in relation to *Helicobacter pylori* infection demonstrated a statistically significant association between abnormal endoscopy findings and positive *H. pylori* status ( $p = 0.015$ ).

## Discussion

As aforementioned, in the present study, most UGI endoscopy results were normal (60.3%). The most common pathological findings were chronic gastritis (13.2%), followed by acute

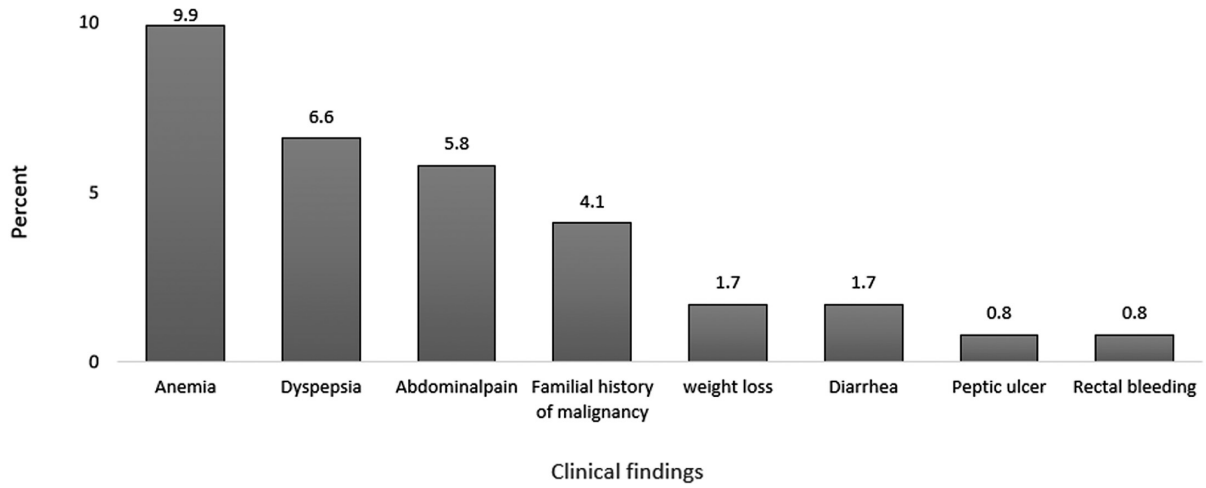


Fig. 1 Frequency of clinical findings of the studied patients.

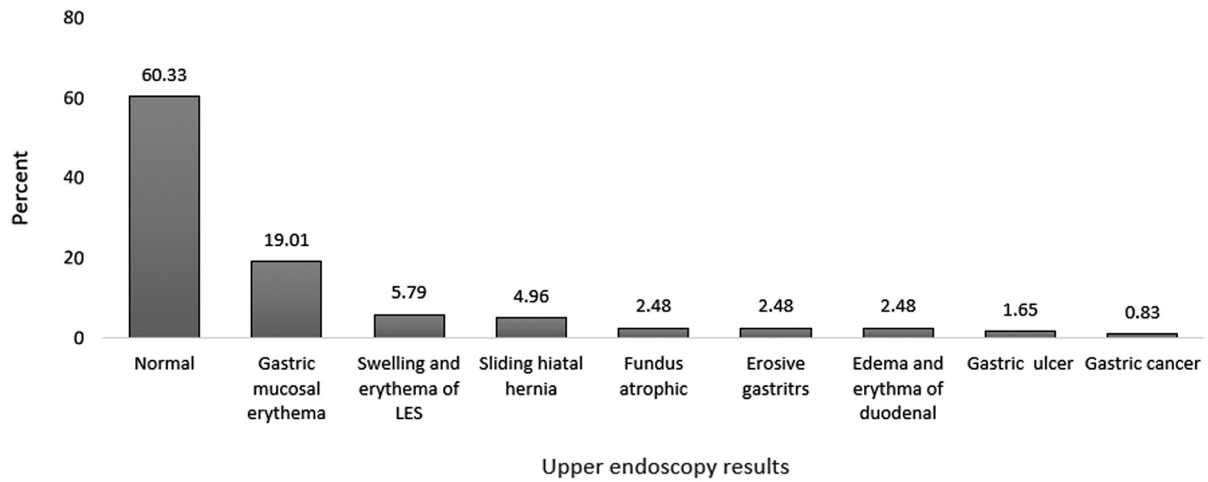


Fig. 2 Frequency of upper gastrointestinal endoscopy results of the studied patients.

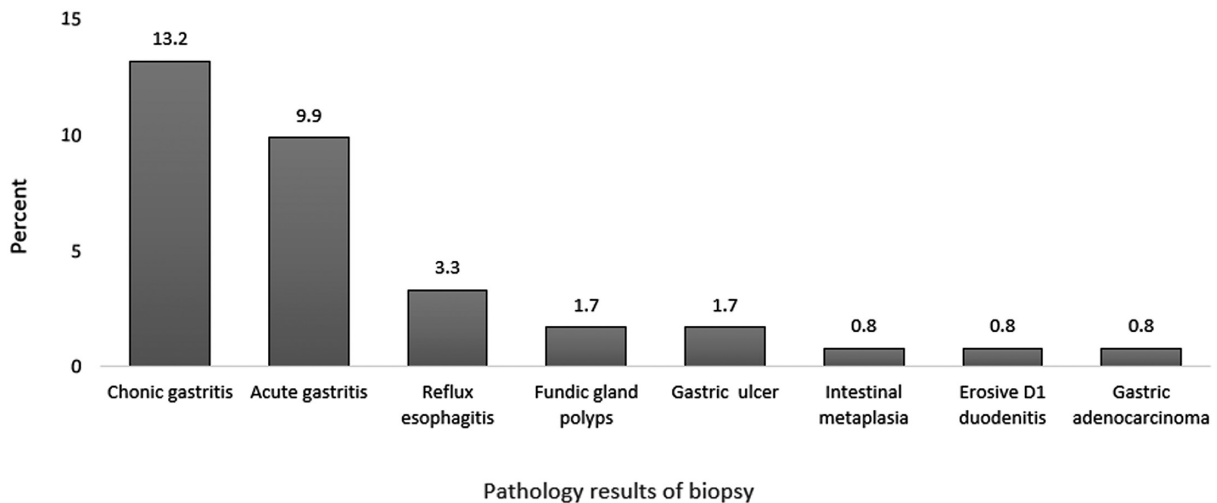


Fig. 3 Frequency of pathology results of upper gastrointestinal endoscopic biopsy of the studied patients.

gastritis (9.9%), and only 1 patient was diagnosed with stomach cancer (adenocarcinoma). The frequency distribution of endoscopy results in relation to *H. pylori* infection demonstrated a statistically significant association between abnormal endoscopy findings and positive *H. pylori* status.

In comparison to previous studies, the results of the current study showed many similar findings. However, it is worth noting that most of these previous studies primarily concentrated on the follow-up of patients within a few years after a positive FIT. In this regard, the current study stands out due to its distinct approach and implementation plan.

In a comparable study<sup>4</sup> conducted in the Netherlands among individuals referred for CRC screening, the authors found that, among 16,165 patients, 52 were diagnosed with UGI cancer within a span of 3 years after receiving a positive FIT result. However, the study did not observe a significant variance in the occurrence of UGI cancers among individuals with positive and negative FIT results. In line with the current research, the authors<sup>4</sup> concluded that routine EGD is not required for patients with a positive FIT result and normal colonoscopy findings.

In another study<sup>5</sup> conducted in Singapore, 523 patients who tested positive on the FIT underwent colonoscopy. Among these patients, 202 individuals also underwent EGD for different reasons, such as dyspepsia, anemia, and weight loss. The findings indicate that EGD in patients with a positive FIT is beneficial in the diagnosis of benign UGI bleeding, which occurs in conditions such as peptic ulcer and erosive gastritis. However, due to the cost of this test, further research is needed to determine the value of EGD in these patients.

In a study<sup>9</sup> conducted in Spain with 120 postmenopausal women and men with iron deficiency anemia with all three methods of the FIT, colonoscopy and endoscopy were evaluated. The authors found that colonoscopy alone based on positive FIT results in patients with anemia is a very effective method to diagnose gastrointestinal pathologies leading to iron deficiency anemia. This approach proves to be advantageous as it accurately identifies the cause of iron deficiency anemia and also provides financial benefits by preventing unnecessary endoscopy procedures.

The findings of a somewhat distinct study,<sup>10</sup> which investigated small bowel lesions using an endoscopic capsule in patients with positive FIT results but no pathological findings during colonoscopy, and the absence of other findings justifying gastrointestinal bleeding, indicated that additional examinations are not recommended for patients without any gastrointestinal symptoms or anemia.

Day et al.<sup>11</sup> reported that, based on endoscopic results, the detection rate of gastric cancer among individuals with positive FIT results is higher in the Asian population compared with the Caucasian population. It appears that the study<sup>11</sup> emphasizes the significance of establishing a regional screening program for cancer screening. And these results are important because, despite the fact that stomach cancer is uncommon in America, this disease presents a high prevalence in Asia, so much so that ~40% of cases of stomach cancer are found in China.<sup>12</sup> In Western societies, one of the

reasons why UGI endoscopy may not be recommended in certain patients is the low incidence of gastric and esophageal malignancies. This decrease in prevalence can be attributed to several factors, including a decline in the prevalence of *H. pylori* infection.<sup>13</sup> In the current study, the prevalence of *H. pylori* among the participants was found to be of 72.7%, which indicates a high occurrence within the geographical area under study. It is important to note that *H. pylori* is a recognized risk factor for the development of UGI malignancies. Considering this, it is possible that the results may vary slightly with the follow-up of these patients in the coming years.

The decision to perform UGI endoscopy as part of a screening program for gastrointestinal tract cancers can vary based on the prevalence of such cancers in different regions. While the overall worldwide prevalence of UGI tract cancers may be low, certain regions may present a higher incidence. In these cases, it may be beneficial to consider adjusting the screening program based on the specific epidemiological and demographic characteristics of those regions. Ultimately, the decision should be based on a thorough assessment of the regional cancer burden and available resources. Another factor that influences the decision to perform UGI endoscopy for cancer screening is the variation across different geographical regions in the prevalence of *H. pylori*, a known risk factor for stomach cancer.

## Conclusion

Considering the low incidence of cancer in UGI endoscopy findings among patients with positive FIT and normal colonoscopy results, performing UGI endoscopy in these cases may not be necessary. It is advisable to reserve this procedure for patients presenting with other symptoms suggestive of malignancy, such as anemia and weight loss.

### Data Reproducibility

The data of the present study are available upon reasonable request from the corresponding author.

### Authors' Contribution

Study concept and design: SR and ABN; data collection: AG; statistical analysis: HM-M; drafting of the manuscript: MT, SR, and HM-M; study supervision: SR and ABN.

### Funding

The authors declare that present study was funded by the Mashhad University of Medical Sciences (research no. 981667).

### Conflict of Interests

The authors have no conflict of interests to declare.

### Acknowledgments

The authors would like to express their gratitude to all of the study participants for their cooperation. The present study was supported by research project no. 981667 as a residency thesis at Mashhad University of Medical

Sciences. We would also like to thank the Clinical Research Development Unit of Ghaem Hospital for their assistance in the present research.

## References

- 1 Mankaney G, Sutton RA, Burke CA. Colorectal cancer screening: Choosing the right test. *Cleve Clin J Med* 2019;86(06):385–392
- 2 O'Connell JB, Maggard MA, Ko CY. Colon cancer survival rates with the new American Joint Committee on Cancer sixth edition staging. *J Nat Cancer Inst* 2004;96(19):1420–1425
- 3 Doubeni CA, Gabler NB, Wheeler CM, et al. Timely follow-up of positive cancer screening results: A systematic review and recommendations from the PROSPR Consortium. *CA Cancer J Clin* 2018;68(03):199–216
- 4 van der Vlugt M, Grobbee EJ, Bossuyt PM, et al. Risk of Oral and Upper Gastrointestinal Cancers in Persons With Positive Results From a Fecal Immunochemical Test in a Colorectal Cancer Screening Program. *Clin Gastroenterol Hepatol* 2018;16(08):1237–1243.e2
- 5 Ng JY, Chan DK, Tan KK. Is gastroscopy for fecal immunochemical test positive patients worthwhile? *Int J Colorectal Dis* 2017;32(01):95–98
- 6 Zappa M, Visioli CB, Ciatto S, et al. Gastric cancer after positive screening faecal occult blood testing and negative assessment. *Dig Liver Dis* 2007;39(04):321–326
- 7 Robertson DJ, Lee JK, Boland CR, et al. Recommendations on fecal immunochemical testing to screen for colorectal neoplasia: a consensus statement by the US Multi-Society Task Force on Colorectal Cancer. *Gastroenterology* 2017;152(05):1217–1237.e3
- 8 Allard J, Cosby R, Del Giudice ME, Irvine EJ, Morgan D, Tinmouth J. Gastroscopy following a positive fecal occult blood test and negative colonoscopy: systematic review and guideline. *Can J Gastroenterol* 2010;24(02):113–120
- 9 Rodriguez-Alonso L, Rodriguez-Moranta F, Ruiz-Cerulla A, et al. The use of faecal immunochemical testing in the decision-making process for the endoscopic investigation of iron deficiency anaemia. *Clin Chem Lab Med* 2020;58(02):232–239
- 10 Chiba H, Sekiguchi M, Ito T, et al. Is it worthwhile to perform capsule endoscopy for asymptomatic patients with positive immunochemical faecal occult blood test? *Dig Dis Sci* 2011;56(12):3459–3462
- 11 Day LW, Cello JP, Somsouk M, Inadomi JM. Prevalence of gastric cancer versus colorectal cancer in Asians with a positive fecal occult blood test. *Indian J Gastroenterol* 2011;30(05):209–216
- 12 Yang L, Parkin DM, Whelan S, et al. Statistics on cancer in China: cancer registration in 2002. *Eur J Cancer Prev* 2005;14(04):329–335
- 13 Franck C, Hoffmann A, Link A, et al. Prevalence of *Helicobacter pylori* infection among blood donors in Saxony-Anhalt, Germany - a region at intermediate risk for gastric cancer. *Z Gastroenterol* 2017;55(07):653–656