



Case Report

Langerhans' cell histiocytosis diagnosed due to dermatological perianal lesion



Bruno Lorenzo Sclaro^{a,b}, Gustavo Becker Pereira^{a,b}, Daniel Cury Ogata^{c,d},
Fernanda Souto Padrón Figueiredo Vieira da Cunha^a, Ana Cristina Martins Effting^{e,*},
Rafael Oselame Guanabara^e

^a Universidade do Vale do Itajaí, Departamento de Cirurgia, Itajaí, SC, Brazil

^b Sociedade Brasileira de Coloproctologia, Brusque, SC, Brazil

^c Universidade do Vale do Itajaí, Disciplina Anatomia Patológica, Itajaí, SC, Brazil

^d Sociedade Brasileira de Patologia, Brusque, SC, Brazil

^e Universidade do Vale do Itajaí, Faculdade de Medicina, Itajaí, SC, Brazil

ARTICLE INFO

Article history:

Received 1 September 2016

Accepted 27 March 2017

Available online 10 May 2017

Keywords:

CD1 antigens

Langerhans' cells

Langerhans' cell histiocytosis

Histiocytosis X

Vinblastine

ABSTRACT

Langerhans' cell histiocytosis is a rare disease characterized by proliferation of Langerhans cells in the body. It affects mainly males, predominantly in childhood. Ulcerated plaques are one of the cutaneous forms of presentation. Diagnostic confirmation is done through immunohistochemistry. As therapeutic options, topical corticosteroids and chemotherapy are good choices. The case is reported of a male patient, aged 14, with perianal ulceration. He consulted a coloproctologist, who performed a biopsy of the region and started local triamcinolone applications. Immunohistochemistry diagnosed Langerhans' cells histiocytosis. Further investigation revealed diabetes insipidus, osteolytic lesions in the skull and lower limbs, enlarged liver, and encephalic alterations. Chemotherapy was started with Vinblastine, with significant improvement of the lesions.

© 2017 Sociedade Brasileira de Coloproctologia. Published by Elsevier Editora Ltda. This is an open access article under the CC BY-NC-ND license (<http://creativecommons.org/licenses/by-nc-nd/4.0/>).

Histiocitose de células de Langerhans diagnosticada por lesão perianal dermatológica

RESUMO

A histiocitose de células de Langerhans é uma doença rara caracterizada pela proliferação de células de Langerhans no corpo. A doença afeta principalmente os homens, predominantemente na infância. Placas ulceradas são uma das formas cutâneas de apresentação. A confirmação diagnóstica é feita através de análise imuno-histoquímica. Como opções terapêuticas, corticosteroides tópicos e quimioterapia são boas escolhas. O caso aqui relatado é de um paciente do sexo masculino, com idade de 14 anos, com ulceração perianal. Ele

Palavras-chave:

Antígenos CD1

Células de Langerhans

Histiocitose de células de

Langerhans

* Corresponding author.

E-mail: cristinaeffting@hotmail.com (A.C. Effting).

<http://dx.doi.org/10.1016/j.jcol.2017.03.007>

2237-9363/© 2017 Sociedade Brasileira de Coloproctologia. Published by Elsevier Editora Ltda. This is an open access article under the CC BY-NC-ND license (<http://creativecommons.org/licenses/by-nc-nd/4.0/>).

Histiocitose X
Vinblastina

consultou um coloproctologista, que realizou uma biópsia da região e iniciou o tratamento com aplicações locais de triancinolona. A análise imunohistoquímica diagnosticou histiocitose de células de Langerhans. Outros exames revelaram diabetes insipidus, lesões osteolíticas no crânio e nos membros inferiores, aumento do fígado e alterações encefálicas. A quimioterapia foi iniciada com vinblastina, com melhora significativa das lesões.

© 2017 Sociedade Brasileira de Coloproctologia. Publicado por Elsevier Editora Ltda. Este é um artigo Open Access sob uma licença CC BY-NC-ND (<http://creativecommons.org/licenses/by-nc-nd/4.0/>).

Introduction

Histiocytosis corresponds to a group of proliferative diseases related to histiocytes, cells originating in the bone marrow. The first description of the disease was in 1939.¹ A rare, little-known disease, it is characterized by proliferation of Langerhans' cells in various tissues. The term histiocytosis X was proposed by Lichtenstein in 1953,² to combine the three forms of the disease that had been described up until then: (1) Eosinophilic Granuloma; (2) Hand-Schüller-Christian disease; and (3) Letterer-Siwe disease. These three forms of the disease exhibit the histiocytes of Langerhans' as a primary proliferative cell in which the Birbeck granule is characteristic, evidenced by electron microscopy. Immunohistochemical analysis of these cells is positive for antigens identical to those found in Langerhans' cells, including the protein S100 and CD1a.³⁻⁵

In 1987, with the creation of the International Histiocyte Society, histiocytosis were grouped into three major classes. Class I was called histiocytosis of Langerhans cells, replacing the different nomenclatures historically used: histiocytosis X, eosinophilic granuloma, Hand-Schüller-Christian syndrome, Letterer-Siwe disease and Hashimoto-Pritzker syndrome.³ The aetiology of Langerhans cell histiocytosis is still uncertain, but some authors have suggested the possibility that it originates in immune hypersensitivity reactions, intestinal malabsorption, or pituitary dysfunction, or autoimmune or inflammatory origin.⁵ Studies differ as to the prevalence of the disease between sexes, and in some studies, a slight predilection for males was observed. It can occur at any age, but the incidence in childhood is higher.^{3,5-7}

During the course of the disease, many organs may be involved, with bone, skin and lymph nodes being most common sites. The treatment varies depending on the extent and severity of the case.⁸ The disease resolve spontaneously, or may evolve, leading to impaired function of vital organs, with severe or fatal consequences. Recent studies have suggested therapeutic regimens involving vinblastine or etoposide, associated with corticosteroid therapy. The lack of response after six weeks of therapeutic treatment is a sign of poor prognosis and of the need for combined therapy with more aggressive regimens.^{3,6,8,9}

In Brazil, reports of Langerhans' cell histiocytosis with perianal margin involvement are rare.¹⁰

The aim of this study is to report a case of Langerhans' cell histiocytosis diagnosed due to perianal skin lesions that presented a favourable outcome after institution of therapy.

Case report

Male patient, aged 14 years, born and raised in Navegantes – Santa Catarina, with symptoms of diffuse abdominal pain and polydipsia. He was taken to the paediatrician, who after examining the patient's medical history and a non-specific physical examination, found no changes. The clinical symptoms persisted for one year, when facial oedema and jaundice were observed. Concomitantly, the patient began to complain of haemorrhoids, and consulted a coloproctology service in his city.

On physical examination, anal inspection showed an ulcerated lesion in the left anal margin, measuring about five centimetres in diameter at its longest axis, with poorly defined edges, erythematous-violaceous, with irregular fundus, and presence of hyaline secretion (Fig. 1). Digital rectal examination and anoscopy showed no changes. There was no inguinal lymphadenopathy. Upon palpation of the jaw, increased angles of irregular size were noted, which were more apparent on the left side. Abdominal examination showed enlarged liver with left hepatic lobe going beyond the midline. There were no other changes in the physical examination.

After clinical examination, and ruling out the possibility of sexually transmitted and other anorectal diseases, biopsy and immunohistochemistry of the lesion was performed in anal margin and therapeutic tests were started with local triancinolone applications, to elucidate the diagnosis.

Pathological biopsy of the ulcerated perianal skin lesion showed infiltrate consisting of a mixture of Langerhans' cells and eosinophils with a histiocytic pattern (Fig. 2). Immunohistochemistry showed positivity in the test for surface antigens CD1a and CD31, and confirmed the diagnosis of Langerhans' cell histiocytosis (Figs. 3 and 4).

Further investigation revealed the following changes:

- Diabetes insipidus and encephalic alterations, evidenced by MRI which resulted in the absence of normal hyperintensity of the posterior lobe of the pituitary gland, marked thickening of the hypothalamic region and some thickening of the proximal portions of the pituitary stalk, with atrophy of the distal portions.

- Osteolytic lesions in the skull and lower limbs, with X-ray of the lower limbs showing hyperdense bone areas in the tibia and tarsal bones; computed tomography of the skull showed diffuse osteolytic lesions.

- Hepatomegaly observed in computed tomography of the abdomen, with increased liver size of the left lobe; extensive micronodular infiltrate diffusely compromising the

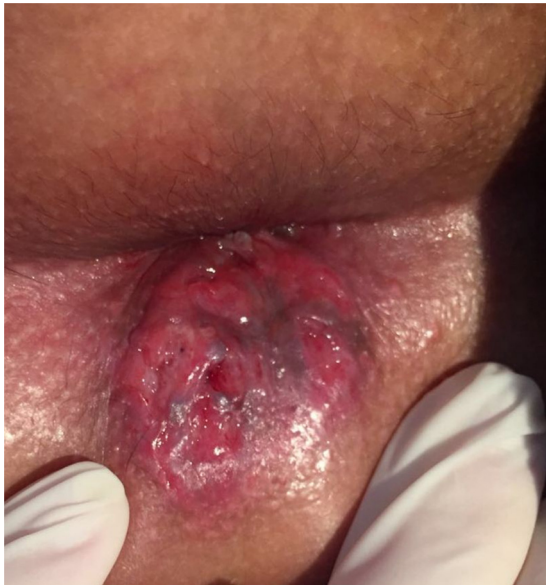

Fig. 1 - Ulceration in the anal margin.

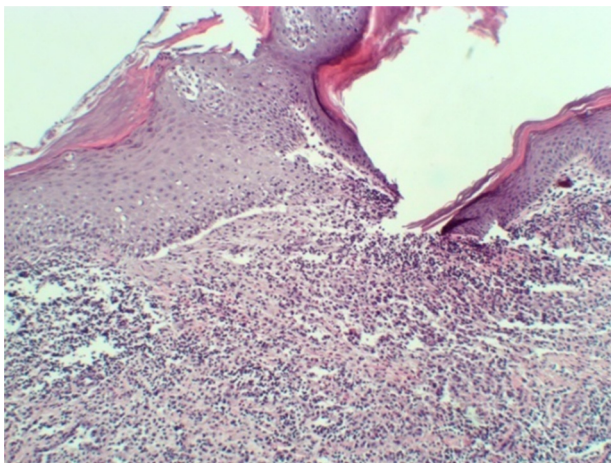


Fig. 2 - Photomicrograph (HE 100x) showing infiltrate consisting of a mixture of Langerhans' cells and eosinophils.

parenchyma; lymphadenopathy in the hepatic hilum, porta-caval chain, and bifurcation of the celiac trunk.

The patient was then referred to the coloproctology service of the University of Vale do Itajaí, where the multidisciplinary care would become more viable. At the service, he underwent assessment by the coloproctology, medical clinic, paediatric endocrinology, dermatology and haematology teams. The latter proposed starting chemotherapy, referring him to the specialized centre. In addition to local triamcinolone applications, the patient began chemotherapy sessions with Vinblastine, showing significant clinical improvement (Fig. 5). On the recommendation of paediatric endocrinology, treatment with Desmopressin (DDAVP) was indicated, with a significant reduction of the urinary symptoms initially presented.

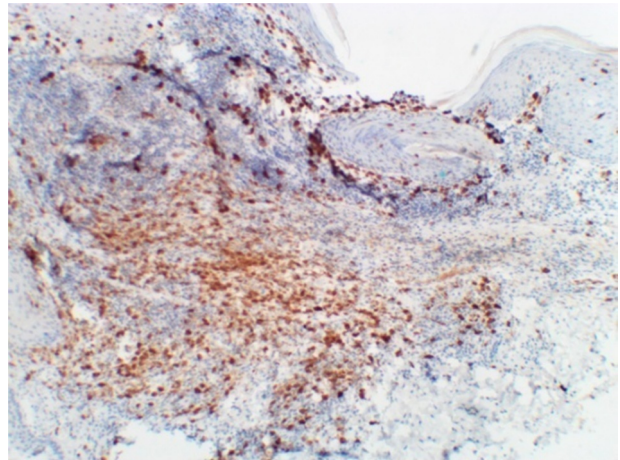


Fig. 3 - Immunohistochemistry (200x) showing membrane pattern reactivity for CD1a.

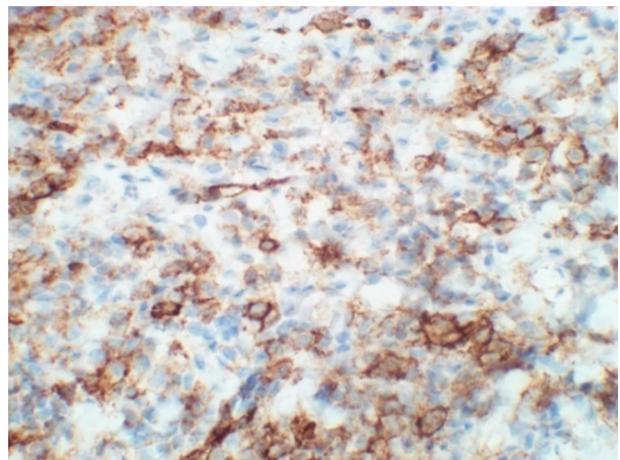


Fig. 4 - Immunohistochemistry (400x) showing membrane pattern reactivity for CD31.

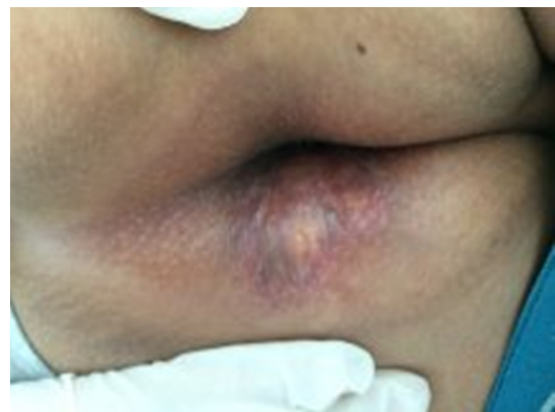

Fig. 5 - Appearance of the lesion after treatment instituted with vinblastine and local triamcinolone applications.

Discussion

The reported case is of a male patient, of school age, whose diagnosis was based on ulcerated skin lesion in the perianal region. The perianal skin disease outbreak reports describe the initial lesion as pruritic erythema, possibly progress to a pink, friable and warty lesion, or a lesion similar to a swollen skin tag. This, in turn, could grow to become an extensive ulceration with infiltrated edges, which could compromise the entire circumference of the anal margin. In the case described, a similar lesion was observed to that reported in the literature.^{4,10,11} Skin lesions of longer evolution are more frequently found in Langerhans' cell histiocytosis with multi-system involvement.¹²

Among the non-skin disorders, diabetes insipidus is observed in approximately 50% of patients; osteolytic changes in 80%, and enlarged liver and spleen in approximately 20%.^{4,13} Osteolytic lesions usually appear at a more advanced stage of disease,¹⁴ inferring a long evolution of the disease described. The involvement of craniofacial bones is associated with increased risk of diabetes insipidus and increased frequency of adenohipophyseal hormone deficiency.⁷ In the above patient, all these signs were present. Furthermore, it is a young, male patient, corroborating in many aspects with the current literature.^{5,6,15}

The diagnosis is often delayed, as the possibility of Langerhans' cell histiocytosis is not usually considered, initially.^{3,5,6,10,16} As described in this case, sexually transmitted diseases and other anorectal disorders should be ruled out, due to their higher prevalence when compared to Langerhans' cells histiocytosis.

Histopathology of the lesion guides the diagnostic suspicion due to visualization of mixed infiltrate in the papillary dermis (Fig. 2). The abnormal proliferation of functionally immature Langerhans' cells, morphologically surrounded by eosinophils, macrophages and occasional multinucleated giant cells, and Birbeck granules (bodies X), are characteristic detections of this pathology.^{3,11,16,17}

The diagnostic confirmation is given by the immunohistochemical study, when positive for CD1a and CD31 antibodies (Figs. 3 and 4), which are highly specific markers for human Langerhans' cell.^{3,10,11,16}

Children and adolescents diagnosed with Langerhans' cell histiocytosis should receive multidisciplinary treatment.⁷ In this study, after detailed evaluation by different professionals, it was decided to continue the local triamcinolone applications, due to the good response shown by the patient. Faced with the pathophysiology of the disease, a proliferation of clonal cells, treatment with chemotherapeutic agents is a good choice. In the case described, Vinblastine was the prescribed medication. In patients with lesions of the bone, skin, lymph nodes, and diabetes insipidus, therapy with Vinblastine and prednisone was effective in preventing reactivation of the disease.¹⁸ In cases of recurrent perianal lesions, radiation therapy may be considered.

Prognostic factors in Langerhans' cell histiocytosis can be divided and arranged by age at diagnosis, response to treatment, and involvement of organs¹⁹; therapeutic response at

6–12 weeks has been shown to be more important prognostic factor than age.²⁰

So far, the patient described in this case is showing favourable development, with significant regression of the initial lesion. A rare disease is observed, with a wide spectrum of clinical manifestations, in a patient with characteristics compatible with the epidemiological profile of the disease, diagnosed based on a dermatological lesion in the perianal region, and who showed satisfactory response to the treatment used.

In view of this case, the importance is highlighted of paying heed to patients' complaints, and of a thorough physical examination. Several diseases have perianal involvement, and a proper investigation, through physical examination and local biopsies, determine the success of the diagnosis in most situations. This report is also important given that the diagnosis of Langerhans' cell histiocytosis is a challenge for the physician, who requires precision and speed, and it should be kept in mind as a differential diagnosis, despite its rare incidence. The importance of disseminating knowledge of the disease is also emphasized, seeking to enable earlier diagnosis.^{3,5,6,10,16}

Conflict of interests

The authors declare no conflicts of interest.

REFERENCES

1. Lane CW, Smith MG. Cutaneous manifestations of chronic (idiopathic) lipoidosis (Hand-Schuler-Christian disease): report of four cases. *Arch Dermatol Syphilol*. 1939;39:617–44.
2. Lichtenstein L. Histiocytosis X: integration of eosinophilic granuloma of bone, "Letterer-Siwe disease" and Schüller-Christian disease as related manifestations of single nosologic entity. *AMA Arch Pathol*. 1953;56:84–102.
3. Campos MK, Viana MB, de Oliveira BM, Ribeiro DD, Silva CM. Histiocitose das células de Langerhans: experiência de 16 anos. *J Pediatr (Rio J)*. 2007;83:79–86.
4. Gama MRVS, Souza HFS, Guerra GMLSR, Fonseca MFM, Balsamo F, Formiga GJS. Histiocitose de células de Langerhans perianal: Relato de caso. *Rev Bras Coloproct*. 2005;25:253–5.
5. Oliveira AJ, Ramos AA, Imparato JCP, Alencar AR, Menezes JFF. Histiocitose de células de Langerhans: revisão de literatura e apresentação de um caso clínico. *R Fac Odonto*. 2004;45:55–9.
6. Ferreira LM, Diniz LM, Redighieri I, Emerich OS, Lage L. Histiocitose de células de Langerhans: doença de Letterer-Siwe—importância do diagnóstico dermatológico em dois casos. *An Bras Dermatol*. 2009;84:405–9.
7. PDQ® - Langerhans Cell Histiocytosis Treatment: Health Professional Version. Available at: http://www.cancer.gov/types/langerhans/hp/langerhans-treatment-pdq#section/_180. [accessed 18 June 2016].
8. Goodman WT, Barret TL. Histiocytoses. In: Bologna JL, Jorizzo JL, Rapini RP, editors. *Dermatology*. Philadelphia: Mosby; 2003. p. 1429–33.
9. Aricó M, Egeler RM. Clinical aspects of Langerhans cell histiocytosis. *Hematol Oncol Clin North Am*. 1998;12:247–58.
10. Magno JCC, D'Almeida DG, Magalhães JP, Pires VJ, Araújo ML, Miranda CB, et al. Histiocitose de células de Langerhans em margem anal: relato de caso e revisão da literatura. *Rev Bras Coloproct*. 2007;27:83–8.

11. Neto MS, Carvalho CH, Fadul JRR, Ambrogini C, Ferreira LM. Histiocitose das células de Langerhans na região anogenital-relato de caso. *Rev Ass Med Brasil*. 1998;44:344-6.
12. Morren MA, Vanden Broecke K, Vangeebergen L, Sillevs-Smitt JH, Van Den Berghe P, Hauben E, et al. Diverse cutaneous presentations of Langerhans cell histiocytosis in children: a retrospective cohort study. *Pediatr Blood Cancer*. 2016;63:486-92.
13. Kader HA, Ruchelli E, Maller ES. Langerhans'cell histiocytosis with stool retention caused by a perianal mass. *J Pediatr Gastroenterol Nutr*. 1998;26:226-8.
14. Kumar V, Abbas AK, Aster JC. *Robbins Patologia Básica*. 9 ed. Rio de Janeiro, 2013.
15. Guyot-Goubin A, Donadieu J, Barkaoui M, Bellec S, Thomas C, Clavel J. Descriptive epidemiology of childhood Langerhans cell histiocytosis in France. 2000-2004. *Pediatr Blood Cancer*. 2008;51:71-5.
16. Rocha MT Jr, Taveira ATA, Dias NA, Reis MF, Ferreira LCL. Histiocitoses de células de Langerhans no paciente pediátrico: apresentação de um caso clínico. *Rev Ciências de Saúde da Amazônia*. 2016;1:1.
17. Laman JD, Leenen PJ, Annels NE, Hogendoorn PC, Egeler RM. Langerhans-cell histiocytosis 'insight into DC biology'. *Trends Immunol*. 2003;24:190-6.
18. Gadner H, Minkov M, Grois N, Pötschger U, Thiem E, Aricò M, et al. Therapy prolongation improves outcome in multisystem Langerhans cell histiocytosis. *Blood*. 2013;121:5006-14.
19. Gadner H, Grois N, Pötschger U, Minkov M, Aricò M, Braier J, et al. Improved outcome in multisystem Langerhans cell histiocytosis is associated with therapy intensification. *Blood*. 2008;111:2556-62.
20. Minkov M, Prosch H, Steiner M, Grois N, Pötschger U, Kaatsch P, et al. Langerhans cell histiocytosis in neonates. *Pediatr Blood Cancer*. 2005;45:802-7.