



## Case Report

# Low digestive hemorrhage caused by a vascular malformation in a patient with Crohn's disease: case report and literature review



Carlos Henrique Marques dos Santos\*, José Valério Librelotto Stefanello II,  
Yuri Maciel Carvalho, Flávio Renato de Almeida Senefonte

Universidade Federal de Mato Grosso do Sul, Campo Grande, MS, Brazil

### ARTICLE INFO

#### Article history:

Received 10 March 2016

Accepted 25 April 2016

Available online 18 June 2016

#### Keywords:

Crohn's disease

Complications

Vascular malformation

### ABSTRACT

The authors report the case of a 19-year-old male patient with Crohn's disease treated with infliximab and azathioprine, with sustained clinical remission; in the course of the evolution, this patient showed a vascular malformation in his rectum, with daily massive bleeding, in need of several blood transfusions and finally with an indication for surgical treatment. Data from the literature on the association of the injury at issue and CD, as well as the drugs used by the patient, are evaluated. The literature lacks information linking this malformation with CD or with the drugs used.

© 2016 Sociedade Brasileira de Coloproctologia. Published by Elsevier Editora Ltda. This is an open access article under the CC BY-NC-ND license (<http://creativecommons.org/licenses/by-nc-nd/4.0/>).

### Hemorragia digestiva baixa por malformação vascular em paciente com doença de Crohn: relato de caso e revisão da literatura

### RESUMO

Os autores relatam o caso de um paciente masculino de 19 anos que apresenta doença de Crohn em tratamento com Infliximabe e Azatioprina com remissão clínica sustentada, o qual apresenta ao longo da evolução uma mal-formação vascular no reto, com sangramento diário volumoso, necessitando de diversas transfusões sanguíneas e finalmente a indicação de tratamento cirúrgico. São avaliados os dados da literatura quanto à associação da lesão apresentada e a DC bem como com os medicamentos em uso pelo paciente. Não há na literatura pesquisada nenhuma informação que associe a mal-formação com a DC nem tampouco os medicamentos utilizados.

© 2016 Sociedade Brasileira de Coloproctologia. Publicado por Elsevier Editora Ltda. Este é um artigo Open Access sob uma licença CC BY-NC-ND (<http://creativecommons.org/licenses/by-nc-nd/4.0/>).

#### Palavras-chave:

Doença de Crohn

Complicações

Mal-formação vascular

\* Corresponding author.

E-mail: [chenriquems@yahoo.com.br](mailto:chenriquems@yahoo.com.br) (C.H. Santos).

<http://dx.doi.org/10.1016/j.jcol.2016.04.011>

2237-9363/© 2016 Sociedade Brasileira de Coloproctologia. Published by Elsevier Editora Ltda. This is an open access article under the CC BY-NC-ND license (<http://creativecommons.org/licenses/by-nc-nd/4.0/>).

## Introduction

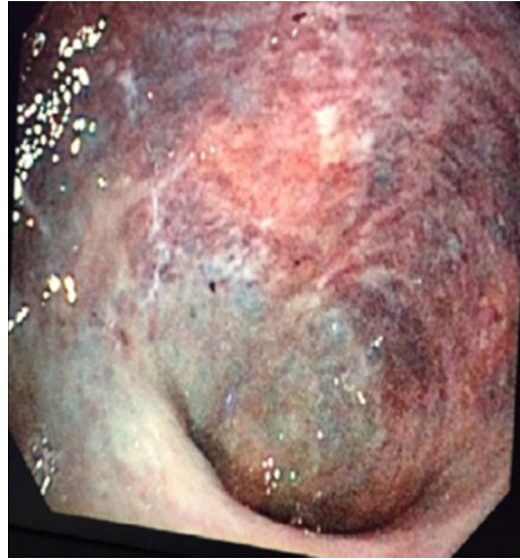Crohn's disease (CD) has become increasingly common in our environment, and in a very special way this condition affects young individuals. Depending on the manner in which DC manifests itself, the disease can cause a departure of the patient from his/her daily activities, which represents great losses, both personally and socially.

Among the various complications that the disease may cause, bowel bleeding is not the most frequent and, when it occurs, this complication tends to be benign, provided that an adjustment of the treatment of the inflammatory process is carried out.

In this case report, we describe an unusual situation, that of a young man with DC in remission who came to us with daily rectal bleeding, an event at first understood as a possible recurrence of the disease. But the investigation found that the cause of the bleeding was a condition of vascular origin in the rectum. The aim of this study was to determine whether there was some relationship of this vascular lesion with DC or with the drugs in use, or whether it was just a coincidence.

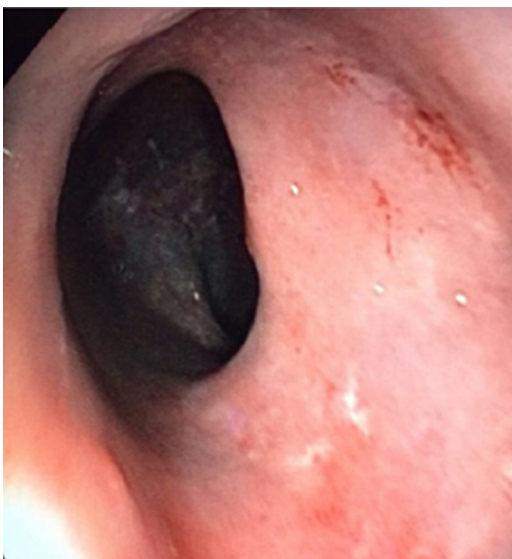
## Case report

A male patient, 19 years old, with a colonoscopy diagnosis of CD established seven years ago, showing chronic, nonspecific ileitis and colitis; at that time, a scheme with prednisone + infliximab (growth deficit) was instituted. The patient showed clinical improvement; thus, prednisone was discontinued and, after six months, a new colonoscopy showed that the disease was in remission. The patient continued the use of infliximab. Four years ago, the patient had a relapse, when azathioprine was prescribed, and an adjustment of infliximab dose was carried out, again with a good response and complete remission. About a year ago, the patient came to us with a new low bleeding picture; the colonoscopy revealed a rectum with an extensive purple/blue subepithelial area

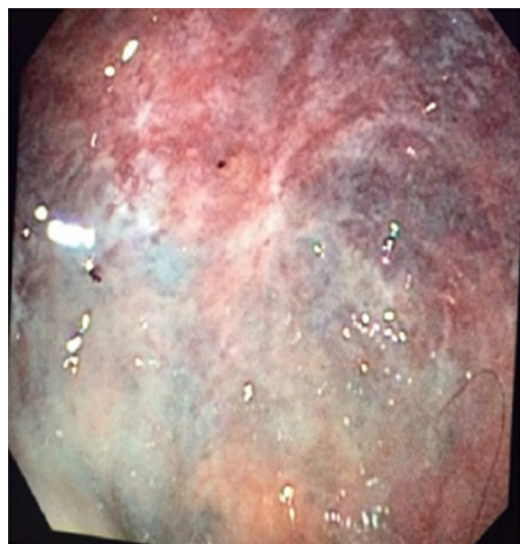


**Fig. 2 – Intermediate portion of the rectum with vascular lesion.**

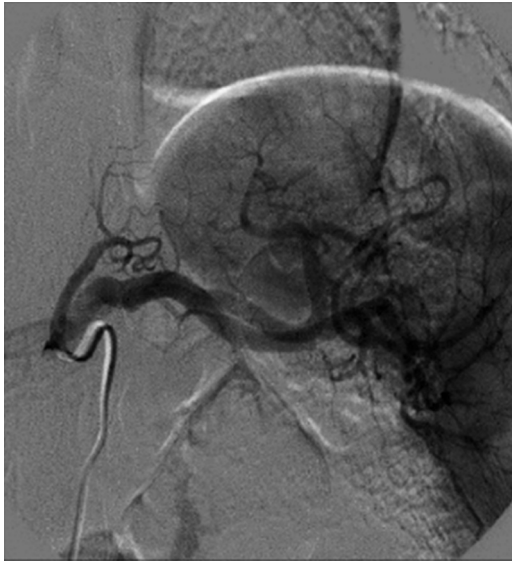
suggestive of ischemia or hemorrhage (Figs. 1-3) with no evidence of an active inflammatory disease. Then, the patient was submitted to a proctology examination under sedation, and dilated hemorrhoidal vessels were found in the entire anal circumference, with a distal rectum without change. A CT scan revealed an abdomen with mild thickening and hypotonia of iliac loops + thickening and hypotonia of the distal sigmoid colon and rectum. A bowel arteriogram demonstrated an arteriovenous malformation in the upper and lower mesenteric arteries (Figs. 4-6) without signs of ischemia. Taking into account that the bleeding persisted for several months, requiring eight blood transfusions, it was decided to perform a surgery. The patient underwent a proctectomy with coloanal anastomosis and a protective ileostomy, with good evolution. The histopathologic examination confirmed that the case was



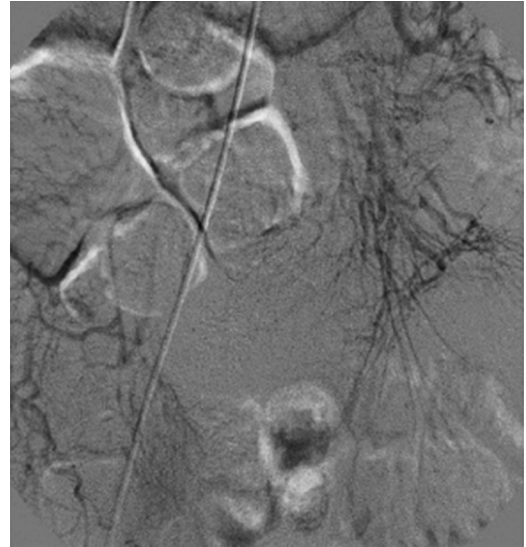**Fig. 1 – Distal portion of the rectum without vascular lesion.**



**Fig. 3 – Intermediate portion of the rectum with vascular lesion.**



**Fig. 4 – MFV in upper mesenteric artery.**



**Fig. 6 – MFV in intermediate portion of the rectum.**

one of a vascular malformation without disease activity in the resected material.

## Discussion

The occurrence of lower gastrointestinal bleeding (LGB) in patients with DC is an infrequent complication. Li et al.<sup>1</sup> evaluated 1374 patients with active disease; 5.31% showed LGB. The authors noted that the recent use of azathioprine and active disease in the left colon were the main factors related to this outcome. The patient here reported had no active disease and was using azathioprine for more than three years.

It is well known that the majority of CD patients require surgical treatment throughout their life, but bowel resections are almost always practiced for the treatment of active disease. Peng et al.<sup>2</sup> evaluated the main indications for surgery

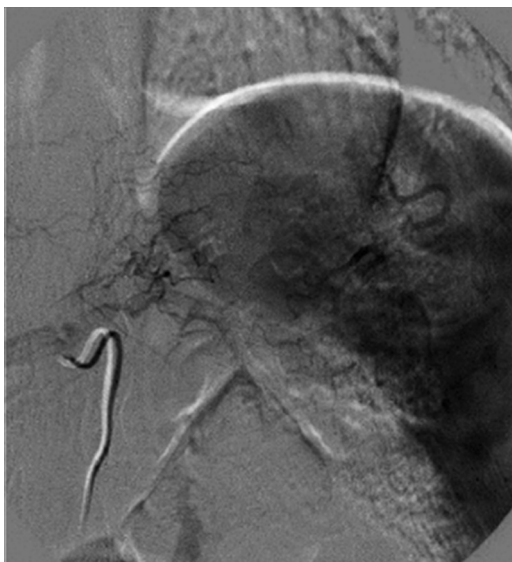in patients with CD and found that obstruction or stenosis ranked first (23.84%), followed by therapeutic failure (14.80%). Intestinal bleeding was only the eighth most frequent indication, with 4.79% of cases; at this point, it should be noted that notwithstanding this finding, this complication was related to disease activity, not to associated disorders, e.g., vascular malformation (as that observed in the present report).

Some authors have reported cases of vascular malformation in the rectum with frequent bleeding (as in the case here presented), and most of these patients also require surgical resection. However, the medical literature surveyed lacks studies in which this fact has occurred in individuals with CD.<sup>3</sup>

Jabłońska et al.<sup>4</sup> reported a case of vascular malformation that occurred in a patient with CD, but it was a case of an injury on the path of an enterocutaneous fistula. The authors emphasized the scarcity of studies with similar cases, which leads us to believe that probably there is no relationship of DC with a vascular malformation. Thus, the question to be answered is whether the treatment used in this case could be in some way associated with vascular malformation, since this complication arose after the use of this therapy.

Sokumbi et al.<sup>5</sup> reviewed cases of vasculitis in CD patients on anti-TNF and observed a prevalence of skin lesions, but these authors also observed systemic and renal lesions, some of them coursing with bleeding episodes. Several other complications have been reported with the use of anti-tumor necrosis factor (TNF) alpha antibodies, including interstitial lung disease, skin lesions, opportunistic infections, etc.; however, no bowel vascular lesion was identified.<sup>6</sup>

Azathioprine has also been extensively studied with respect to its complications and adverse effects in patients with inflammatory bowel disease. Most studies suggest the possibility of infectious complications, and the development of a lymphoma is the most dreaded of all complications, especially when associated with the use of anti-TNF. But the occurrence of vascular malformation has not been linked to this treatment.<sup>7</sup>



**Fig. 5 – MFV in upper mesenteric artery.**

Thus, it can be concluded that neither DC nor its treatment appears to be related to the onset of bowel vascular malformation; however, considering the lack of articles addressing this issue, our report plays a big role, thanks to the documentation of the observed complication, as an eventual contribution to other publications that may arise.

---

### Conflicts of interest

The authors declare no conflicts of interest.

### REFERENCES

---

1. Li GL, Ren J, Wang G, Wu Q, Gu G, Ren H, et al. Prevalence and risk factors of acute lower gastrointestinal bleeding in Crohn disease. *Medicine (Baltimore)*. 2015;94:e804.
2. Peng QH, Wang YF, He MQ, Zhang C, Tang Q. Clinical literature review of 1858 Crohn's disease cases requiring surgery in China. *World J Gastroenterol*. 2015;21:4735–43.
3. Chen ZC, Deng HJ. Laparoscopic diagnosis and treatment of rectum telangiectasia: report of a rare form of lower gastrointestinal hemorrhage. *Nan Fang Yi Ke Da Xue Xue Bao*. 2015;35:1508–10.
4. Jabłońska B, Lekstan A, Lampe P, Pilch-Kowalczyk J. Hemorrhage from the inferior epigastric artery malformation into the external intestinal fistula as an atypical complication of Crohn's disease. *JCC*. 2013:e26–7.
5. Sokumbi O, Wetter DA, Makol A, Warrington KJ. Vasculitis associated with tumor necrosis factor- $\alpha$  inhibitors. *Mayo Clin Proc*. 2012;87:739–45.
6. Curtis JR, Sarsour K, Napalkov P, Costa LA, Schulman KL. Incidence and complications of interstitial lung disease in users of tocilizumab, rituximab, abatacept and anti-tumor necrosis factor  $\alpha$  agents, a retrospective cohort study. *Arthritis Res Ther*. 2015;17:319.
7. Meyer L, Simian D, Kronberg U, Estay C, Lubascher J, Figueroa C, et al. Development of malignant tumors in patients with inflammatory bowel disease. *Rev Med Chil*. 2015;143:834–40.