

Neurovascular Coupling and Functional Neuroimaging in Epilepsy

Valesio Becker Junior*, Lauro Wichert-Ana***, Rhelen Piantino Leitão Ferreira da Silva**, Daniel Giansante Abud**, Sara Escorsi-Rosset***, Rodrigo Romcy-Pereira***, João Pereira Leite***

Serviço de Medicina Nuclear – Hospital das Clínicas da Faculdade de Medicina de Ribeirão Preto – USP

ABSTRACT

Introduction: The neural regulation of the microcirculation is done by the functional neurovascular unit that is composed of vascular, astroglial and neuronal cells. The neurovascular unit represents the interface between the Central Nervous System and the Vascular System. **Objective:** This paper reviews the literature on functional neuroimaging with a particular focus on the mechanisms of the neurovascular coupling. **Conclusions:** Functional neuroimaging techniques as functional MRI, SPECT and PET distinguish metabolic and physiological processes underlying normal and abnormal events, based on neurovascular coupling. Although these techniques still have limitations in temporal and spatial resolution, they have considerably reduced the need for intracranial electrodes or invasive functional tests in the presurgical evaluation for intractable epilepsy. Recently, new techniques as optical approaches (measurement of intrinsic optical signals and near infrared spectroscopy) have increased both temporal and spatial resolutions. The use of such techniques in animal models has yielded experimental evidence for a neurovascular coupling in normal and epileptic conditions.

Key words: Epilepsy, neurovascular coupling, functional neuroimaging, SPECT, PET, fMRI, intrinsic optical signal, near infrared spectroscopy.

RESUMO

Acoplamento neurovascular e neuroimagem funcional em epilepsia

Introdução: A regulação da microcirculação cerebral é realizada pela unidade neurovascular, que é composta por vasos sanguíneos, células astrogliais e neuronais. A unidade neurovascular representa a interface funcional entre o Sistema Nervoso Central e o sistema vascular. **Objetivo:** Este trabalho revisa a literatura sobre técnicas de neuroimagem funcional com especial enfoque nos mecanismos do acoplamento neurovascular. **Conclusão:** Técnicas de neuroimagem como a Ressonância Magnética funcional, SPECT e PET baseiam-se no acoplamento neurovascular para explorarem os processos metabólicos e fisiológicos subjacentes a eventos cerebrais normais e anormais. Embora estas técnicas apresentem limitações de resolução temporal e espacial, sua aplicabilidade em epilepsia tem reduzido consideravelmente a necessidade de eletrodos intracranianos e de outros métodos funcionais invasivos na avaliação pré-cirúrgica de pacientes com epilepsia intratável. Recentemente, novos procedimentos ópticos (mensuração do sinal intrínseco óptico e espectroscopia por raio infravermelho) que possuem excelente resolução espacial e temporal têm fornecido evidências experimentais do acoplamento neurovascular no cérebro normal e epilético.

Unitermos: Epilepsia, acoplamento vascular, neuroimagem funcional, SPECT, PET, fMRI, ressonância magnética funcional, sinal intrínseco óptico, espectroscopia.

* Serviço de Medicina Nuclear.

** Centro de Ciências das Imagens e Física Médica.

*** Departamento de Neurologia, Psiquiatria e Psicologia Médica – Hospital das Clínicas da Faculdade de Medicina de Ribeirão Preto – USP.

Received Oct. 28, 2008; accepted Nov. 29, 2008.

INTRODUCTION

We review here the main literature about the role of the neurovascular coupling upon functional neuroimaging techniques like functional magnetic resonance imaging (fMRI), Single Photon Emission Computed Tomography (SPECT), Positron Emission Tomography (PET) and Optical Intrinsic Signal (OIS) and Near Infrared Spectroscopy (NIRS).

The knowledge about neurovascular coupling is important to understand the application of functional neuroimaging techniques in patients with epilepsy. Each functional neuroimaging technique may explore different metabolic or a particular pathophysiological event during the ictal and interictal periods, but all are based on the principles of the neurovascular coupling.³² Unfortunately a perfect technique does not exist, because they are spatially and temporally limited or much invasive to be largely used.³¹

We review the main articles about techniques based on neurovascular coupling focusing their applications, limitations and future directions in epilepsy.

1 WHAT IS NEUROVASCULAR COUPLING?

The neural regulation of the cerebral microcirculation is done by the functional neurovascular unit, which is composed of vascular, astroglial and neuronal cells. The neurovascular unit represents the interface between the Central Nervous System (CNS) and the vascular system. In addition to its barrier function, it has important roles in the regulation of entry of substrates and exit of waste products as well as the regulation of local microcirculation.³⁰

Some studies have pointed out the crucial role for astrocytes trigger in the dynamic control of the cerebral microcirculation and suggest that one important physiological role of astrocytes is to mediate vasodilation in response to increase neural activity.^{30,36} Astrocyte $[Ca^{++}]$ oscillations may represent thus a neuron-dependent signaling system that allows these cells to work as bridges between neurons and blood vessels.³⁶ The vasodilatation produced by increase of intracellular astrocytic $[Ca^{++}]$ is mediated by the pathway of arachidonic acid metabolic products, primarily on COX-1 metabolites such as PGE2.^{30,36}

The neuronal cells are represented by cortical interneurons and neurons of the intrinsic neural pathways originating from subcortical areas, such as, *nucleus basalis*, *locus coeruleus*, *raphe nucleus*, basal forebrain and thalamus.³⁶ Upon electrical or chemical stimulation, these subcortical areas release neurotransmitters that act on the other components of neurovascular unit and thus elicit increases or decreases in regional cortical cerebral blood flow

(rCBF). When neurons in a specific brain region are highly activated, blood flow increases in a temporally and spatially coordinated manner. Functional hyperemia occurs within seconds after neuronal activation and is spatially coupled to brain areas with increased energy demands. The extensive innervation of cerebral blood vessels suggests that neurons directly control the local changes in rCBF associated with neuronal activity.³⁶ The innervation of extracerebral blood vessels is mainly originated in the superior cervical ganglion (sympathetic innervation), the sphenopalatine and otic ganglia (parasympathetic innervation) and the trigeminal ganglion (sensorial innervation). Upon their entry into the brain parenchyma, cerebral arteries lose their peripheral nerve supply and receive input from neurons located within the brain itself, the “intrinsic innervation” of the cerebral microcirculation.³⁶

Brain perfusion is tightly coupled to neuronal activity and is a direct reflection of the interactions that occur between neuronal signals and blood vessels.³⁶ Areas of the brain undergoing increases in the neuronal activity consume increasing amounts of oxygen, glucose and other metabolites. These areas therefore rapidly undergo a corresponding increase in perfusion. Therefore, image of rCBF reflects indirectly cerebral metabolism.³⁶

The rise in rCBF is mainly achieved by arteriolar dilatation inducing increased perfusion pressure downstream. Blood flow per capillary is increased mainly by an increase in blood flow velocity. These factors result in a local increase in oxygenated-Hemoglobin (oxy-Hb) and drop in deoxygenated-Hemoglobin (deoxy-Hb). The latter is the main basis of the fMRI BOLD (blood oxygenation level-dependence) contrast.³⁶ Activity-dependent changes in the BOLD signal result from increased perfusion and blood volume. In this setting, the neurovascular coupling is the basis for these functional neuroimaging methods. The investigation of epilepsies depends crucially from the knowledge of the physiological principles and of the dynamics of the brain functioning in normal and abnormal conditions. The main objective of this short review is to address the underlying mechanisms related to current functional imaging techniques and the coupling between neuronal and glial metabolism and the vascular responses to blood supply demand.

2 NEUROVASCULAR COUPLING AND FUNCTIONAL NEUROIMAGING

2.1 Single Photon Emission Tomography (SPECT)

The brain SPECT evaluates the distribution of perfusion tracers throughout the cerebral parenchyma enabling us to document the rCBF changes in normal and abnormal conditions. It uses low dose of radiation, is widely available, and it is the only technique that makes

possible to noninvasively study an epileptic event by doing a “photograph” of the ictal cerebral function at the time of tracer injection. This is possible due to the high first pass extraction of the tracer by the brain. As a consequence, the increase in tracer uptake may reflect the increase in rCBF in the epileptogenic zone.

Different images of the same patient are possible, such as interictal, ictal or post-ictal images. Recent studies correlating the chronology of the ictal semiological and electroencephalographic findings with perfusion patterns demonstrated that atypical and postictal findings can be just detected when the tracer is injected before the seizure end.³⁶ The acknowledgement of epileptic events as a dynamic and complex process where time for tracer injection is a factor that directly contributes to interpret the SPECT images justifies the use of serial SPECTs in some particular cases, which is a common practice at different centers.³³

Studies have suggested the role for the thalamus in consciousness mechanisms,^{20,36} and that the extension of the epileptogenic network to the thalamus is a potential important factor determining surgical prognosis.¹² The brain contains multiple reciprocal excitatory and inhibitory interconnections on both levels of local microcircuits, and of long range network interactions.³ These network interactions were recently suggested in a study using SPECT data and SPM.⁵ Simple partial seizures were associated with more limited changes confined mainly to the temporal lobes. Complex partial seizures were associated with marked rCBF decrease in regions of association cortex, including the lateral prefrontal, anterior cingulate, orbital frontal, and lateral parietal cortex. There is preliminary evidence indicating that abnormal increased activity in fronto-parietal association cortex may cause loss of consciousness in generalized seizures,⁵ while abnormal decreased activity in these same networks may cause loss of consciousness in complex partial seizures.⁴ A similar result has been previously suggested in an animal model.²⁷

The existence of positive and negative networks within the brain that are activated during seizures and inhibited in the interictal period is widely supported by many studies on cerebral SPECT by using the principles of the neurovascular coupling.

2.2 Positron Emission Tomography (PET)

Interictal Fluor-18-Fluorodeoxyglucose Positron Emission Tomography (FDG-PET) has high sensitivity and specificity^{7,35} and is first-line noninvasive investigation in patients with refractory partial epilepsy undergoing presurgical evaluation.^{2,31} It has been known that in normal brain, both brain perfusion and metabolism are tightly coupled to neuronal activity.²² There is high agreement

between interictal PET and invasive ictal EEG in the localization of the EZ, so a PET finding concordant with the localization of surface EEG with sphenoid electrodes can avoid invasive evaluation and, in case of disagreement, interictal PET can guide the localization of the region to be investigated with invasive electrodes.⁷ However, concerns regarding the precision of the interictal FDG-PET findings have been reported. First, the hypometabolic areas on FDG-PET are larger than the irritative zones observed by EEG and the anatomical lesions observed by MRI.^{7,11} Probably, the functional lesion is larger than the anatomical one, either due to the secondary inhibition in the areas surrounding the EZ³¹ or due to the loss of adjacent neuronal tissue.³⁴ Second, evidences of patients with localized hypometabolism in the contralateral temporal lobe.^{18,29} These findings lead to false localization of the EZ and may be explained by the synergistic activation of glucose transport and metabolism in astrocytes, rather than in neurons.¹

New tracers for the study of the gabaergic, cholinergic and serotonergic systems are available.^{8,11} Using the 11C-flumazenyl and 11C-Iomazenyl it is possible to study the cerebral distribution of benzodiazepine receptors.¹⁸ The exam reveals a well-delimited area of low uptake, which reflects a significant decrease in benzodiazepine receptors in the EZ.^{16,19} Because of the large number of cortical gabaergic synapses, these studies permit the detection of the integrity of functional neuronal structures, differentiating them from structural alterations. A potential application is the monitoring of the pharmacological effect of different substances that interact with GABA receptors.¹⁹ Another PET tracer, 11C-methionine (MET) has useful positive and negative findings in lesion-related epilepsy. Conversely to the high MET uptake over the brain region with focal cortical dysplasia²⁴ and angiomas (eg., Sturge-Weber syndrome),¹⁵ patients with temporal lobe epilepsy associated with dysembryoplastic neuroepithelial tumors (DNETs) presents negative MET uptake over the lesion, which helps to differentiate the tumor from other lesions.²¹

In the future, new tracers with more specificity to the EZ should be developed, but this perspective depends on enhancement in the comprehension of epilepsy pathophysiological phenomena such as neurovascular coupling, metabolism and neuroreceptors.

2.3 Functional Magnetic Resonance Imaging

fMRI is a technique that analyzes the brain function not using radiopharmaceuticals, like PET and SPECT. The aim of fMRI is to indirectly measure neuronal activity, based on the variations in rCBF during specific tasks. Since neuronal activity comprises a complex metabolic process dominated by synaptic transmission

and consequent rise in energy demand and flow elevation, the neuronal activity is tightly coupled with changes in rCBF, demonstrated in experimental conditions.⁹

The brain activation, dependent of the task execution, increases not only the rCBF but also the deoxy-Hb over oxy-Hb ratio. Paramagnetic deoxy-Hb disturbs the magnetic field and produces a drop in signal on susceptibility-weighted (T2*) MR sequences, while oxy-Hb is magnetically “neutral” (diamagnetic). These sequential events cause a regional heterogeneity in the magnetic field detectable by the MRI that is used to label the brain activity. This method is named BOLD (Blood-oxygenation-level dependent).

Thus, fMRI detects brain activity by using the BOLD effect. Unfortunately, the signal produced by BOLD is very tiny, which implies the use of statistical methods and task repetition many times in one section. This method is used to compare many activity periods over many rest periods generating a color coded statistical map of the relevant difference between brain areas with and without BOLD effect. This statistical map is superimposed over a high-resolution MR image (See Figure 1).²³

The task can be alternated with rest in one-by-one symmetric pattern, what is named block paradigm. This is the most frequent method used in fMRI. The alternative technique is an event-related paradigm, which utilizes not symmetric block of task-rest.

fMRI has been used for a long period only for research. Nowadays it is also used for clinical purposes as in presurgical evaluation of medically intractable epilepsy. In this setting, fMRI is used to localize primary functional areas, like language, motor or vision areas, in patients with lesions near one of these eloquent regions. Of course, one must be very cautious with rCBF changes caused by diseases on fMRI. Nevertheless, the method might be helpful in pre surgical planning.^{10,14}

The use of fMRI for research purposes allows a much more flexible protocol and several papers have been published analyzing a broad range of brain functions like mapping memory, ambitious and moral dilemmas. Again, caution is necessary using fMRI for complexes behaviors localization. Different from primary areas related with simple functions, more complex brain functions are believed to be dependent of brain circuits and not a specific brain area.

2.4 Optical Intrinsic Signal Imaging (OIS)

Seizures are caused by the synchronous, rhythmic firing of a population of neurons and can last from seconds to minutes. The population of neurons responsible for each epileptic event varies in shape and size over

a short period of time and this organization lasts as one of the most important questions in the field of epilepsy.²⁵

Electrophysiological recordings from surface field and extra-cellular single-unit electrodes have been considered the gold standard for monitoring epileptiform activity. Functional noninvasive techniques have been introduced into clinical practice and experimental studies, such as fMRI, SPECT and PET. These techniques are promising but still lack in temporal resolution to analyze and distinguish brief interictal paroxysmal epileptiform events and to differentiate ictal onsets from areas of early spread.¹¹

The analysis of OIS is a technique under evaluation based on light absorption and reflectance of the active neural tissue caused by the transformation from oxy-Hb into deoxy-Hb, associated to local changes in CBV and rCBF.⁶ These minimal changes of the optical properties of the neural tissue can be detected by special cameras with high sensitivity and appropriated software of analysis.

The technique consists in the illumination of the cerebral tissue to be analyzed by one halogen lamp. The optical reflectance signal is recorded by a system of high sensitivity cameras with a very rapid image acquisition. These images are then digitalized, processed by software and transformed into maps and graphics showing the variations of the optical signal over time.

The OIS mapping have been used to create neuronal activity maps with high spatial resolution in experiments using animal models to study functional somato-sensorial areas of the brain and in epilepsy to evaluate spontaneous epileptic events as interictal spikes, ictal and homotopic secondary foci in vivo. Studies using OIS to map epileptiform events in brain cortex of ferrets during simulated ictal events or during interictal spikes and homotopic secondary foci have produced a real-time focal raise in blood flow and metabolism associated with each of these events.^{13,26} Besides, it also demonstrated an inhibitory circuit around the interictal foci, through an inverted variation of the optical signal around those areas, probably explained by the drop of O₂ delivery, reflecting a low blood flow, deviated to areas of higher activity²⁸ (See Figure 2). Interestingly, rapid decrease in tissue and blood oxygenation and an increase in deoxy-Hb have been reported preceding the increase in rCBF. These findings imply that for a brief period of time after neurons discharge, the brain is mildly ischemic until cerebrovascular autoregulation dilates arterioles to increase rCBF. For interictal events, oxy-Hb drops for ~3 s, whereas at the beginning of a seizure, the drop in oxygenation can last for tens of seconds.²⁶

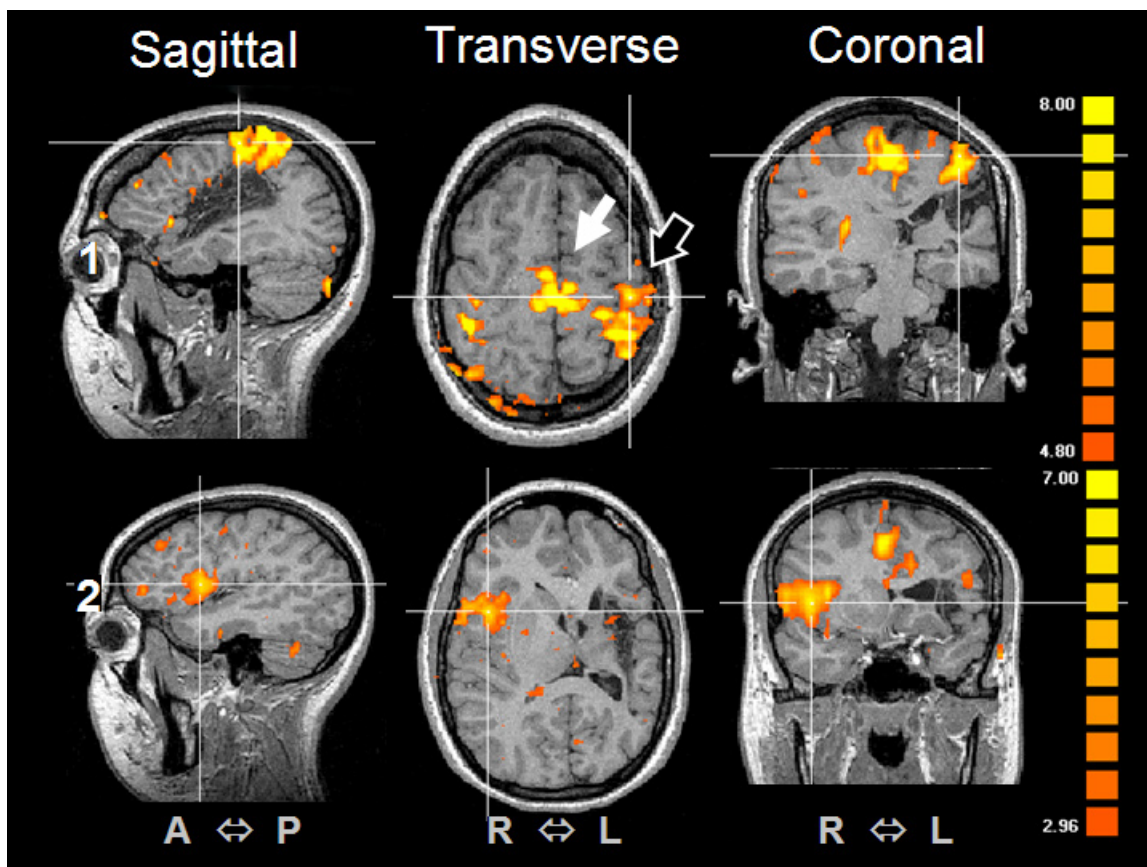


Figure 1. Functional MRI showing on the roll 1 a finger typing motor task with primary motor cortex (Brodmann area 4, Outlined White Arrow) and supplementary motor area activation (Brodmann area 6, Bold White Arrow). There is a tiny activation on the contralateral primary motor cortex, either. On the roll 2 one can see a robust activation on the homolog Broca area, on the right inferior frontal gyrus. Note the destructive lesion on the left frontal lobe.

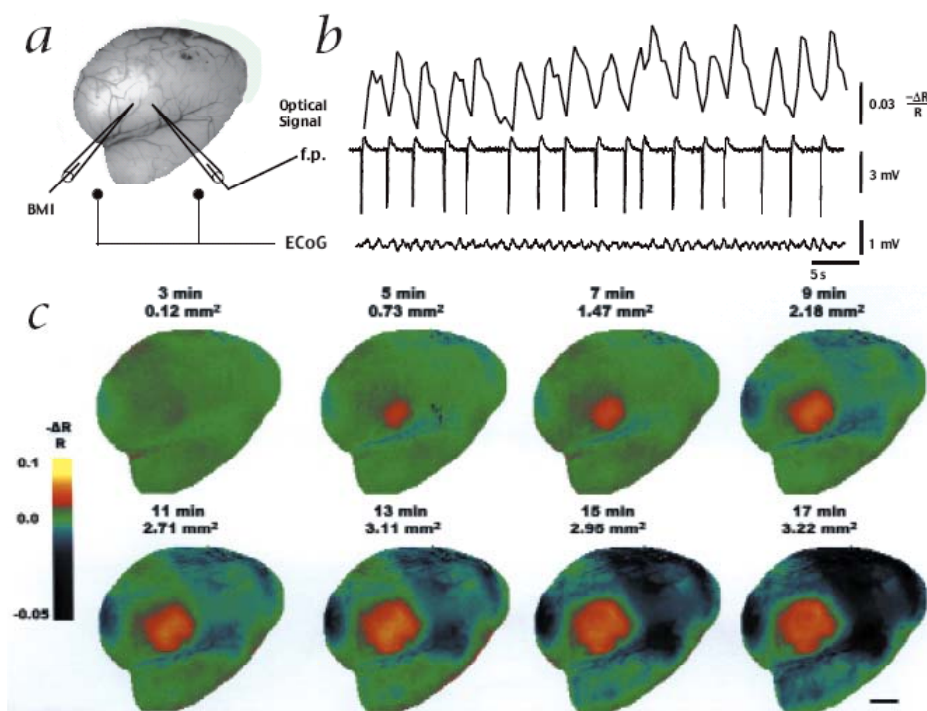


Figure 2. Optical recording of intrinsic signals demonstrate the topography of an interictal focus. (a) Blood vessel pattern of the imaged region. (b) Simultaneous optical signal, field potential (f.p.) and ECoG recording show that each interictal spike has a discrete optical correlate. (c) The areas stimulated in (a) presents a progressive increase in the optical intrinsic signal. Notice that the negative optical signal in the surrounding cortex also increases in intensity and area as the focus develops. (Figure extracted from Reference 27)

CONCLUSION

Since 1892, when Victor Horsley noted an increase in rCBF during induced seizures, scientists had the idea to study these phenomena by means of neuroimage. Increase of rCBF during spontaneous epileptic seizures was first demonstrated in humans by GIBBS et al. in 1934 using a thermoelectric blood flow sensor placed in the external jugular vein.³³

The incorporation of neuroimaging techniques such as SPECT, PET and fMRI in the last decade into the protocol for EZ localization has considerably reduced the need for intracranial electrodes. These functional neuroimaging techniques reports the understanding of the underlying physiological events based on neurovascular coupling.³² Unfortunately, an ideal method does not exist. Different tools to solve this problem have been made, including the development of software of fusion of images. Several methods are currently available for the co-registration of SPECT and MRI images and for the subtraction of interictal SPECT from ictal SPECT. The fusion image thus permits minimizing the intrinsic limitations of each imaging modality and highlighting the specific advantages of the various methods.^{17,33} More recently, the application of OIS to map the human epileptic cortex in the operating room²⁶ associated to neuronavigation surgical techniques may be a great advance in the functional neurosurgery.

ACKNOWLEDGEMENTS

Funding Sources: “The State of São Paulo Research Foundation” – FAPESP (Grant 04/14004 – CInAPCe Program) and FAEPA/HCFMRP.

REFERENCES

- Barros LF, Porras OH, Bittner CX. Why glucose transport in the brain matters for PET. *Trends Neurosci* 2005;28(3):117-9.
- Blum DE, Ehsan T, Dungan D, Karis JP, Fisher RS. Bilateral temporal hypometabolism in epilepsy. *Epilepsia* 1998;39(6):651-9.
- Blumenfeld H. From molecules to networks: cortical/subcortical interactions in the pathophysiology of idiopathic generalized epilepsy. *Epilepsia* 2003;44(Suppl 2):7-15.
- Blumenfeld H, McNally KA, Vanderhill SD, Paige AL, Chung R, Davis K et al. Positive and negative network correlations in temporal lobe epilepsy. *Cereb Cortex* 2004;14(8):892-902.
- Blumenfeld H, Westerveld M, Ostroff RB, Vanderhill SD, Freeman J, Necochea A et al. Selective frontal, parietal, and temporal networks in generalized seizures. *Neuroimage* 2003;19(4):1556-66.
- Bonhoeffer T, Grinvald A. The Methods. In: Toga AW, Mazziotta J, editors. *Brain Mapping*. San Diego: Academic; 1996. p. 55-99.
- Borbely K. [Functional imaging (PET and SPECT) in epilepsy]. *Orv Hetil* 2001;142(44):2405-14.
- Carreras JL, Perez-Castejon MJ, Jimenez AM, Domper M, Montz R. [Neuroimaging in epilepsy. Advances in SPECT and PET in epilepsy]. *Rev Neurol* 2000;30(4):359-63.
- Delmaire C, Krainik A, Lethuc V, Reynolds N, Duffau H, Capelle L et al. [Functional magnetic resonance imaging: physiopathology, techniques and applications]. *J Radiol* 2007;88(3 Pt 2):497-509.
- Detre JA. Clinical applicability of functional MRI. *J Magn Reson Imaging* 2006;23(6):808-15.
- Duncan JS. Imaging and epilepsy. *Brain* 1997;120(Pt 2):339-77.
- Guye M, Regis J, Tamura M, Wendling F, McGonigal A, Chauvel P et al. The role of corticothalamic coupling in human temporal lobe epilepsy. *Brain* 2006;129(Pt 7):1917-28.
- Hamel E. Perivascular nerves and the regulation of cerebrovascular tone. *J Appl Physiol* 2006;100(3):1059-64.
- Hirsch J, Ruge MI, Kim KH, Correa DD, Victor JD, Relkin NR et al. An integrated functional magnetic resonance imaging procedure for preoperative mapping of cortical areas associated with tactile, motor, language, and visual functions. *Neurosurgery* 2000;47(3):711-21.
- Ichinose T, Tsuyuguchi N, Morino M, Sunada I, Ohata K, Takami T et al. Discrepancy between [18F]fluorodeoxyglucose and 11C-methionine positron emission tomography findings in Sturge-Weber syndrome--case report. *Neurol Med Chir (Tokyo)* 2003;43(9):461-4.
- Juhasz C, Chugani DC, Muzik O, Watson C, Shah J, Shah A et al. Relationship between EEG and positron emission tomography abnormalities in clinical epilepsy. *J Clin Neurophysiol* 2000;17(1):29-42.
- Kaiboriboon K, Lowe VJ, Chantarujikamong SI, Hogan RE. The usefulness of subtraction ictal SPECT coregistered to MRI in single- and dual-headed SPECT cameras in partial epilepsy. *Epilepsia* 2002;43(4):408-14.
- Kaneko K, Sasaki M, Morioka T, Koga H, Abe K, Sawamoto H et al. Pre-surgical identification of epileptogenic areas in temporal lobe epilepsy by 123I-iomazenil SPECT: a comparison with IMP SPECT and FDG PET. *Nucl Med Commun* 2006;27(11):893-9.
- Lamusio S, Pitkanen A, Jutila L, Ylinen A, Partanen K, Kalviainen R et al. [11C]Flumazenil binding in the medial temporal lobe in patients with temporal lobe epilepsy: correlation with hippocampal MR volumetry, T2 relaxometry, and neuropathology. *Neurology* 2000;54(12):2252-60.
- Lee KH, Meador KJ, Park YD, King DW, Murro AM, Pillai JJ et al. Pathophysiology of altered consciousness during seizures: Subtraction SPECT study. *Neurology* 2002;59(6):841-6.
- Machara T, Nariai T, Arai N, Kawai K, Shimizu H, Ishii K et al. Usefulness of [11C]methionine PET in the diagnosis of dysembryoplastic neuroepithelial tumor with temporal lobe epilepsy. *Epilepsia* 2004;45(1):41-5.
- Magistretti PJ, Pellerin L. Cellular mechanisms of brain energy metabolism and their relevance to functional brain imaging. *Philos Trans R Soc Lond B Biol Sci* 1999;354(1387):1155-63.
- Norris DG. Principles of magnetic resonance assessment of brain function. *J Magn Reson Imaging* 2006;23(6):794-807.
- Sasaki M, Kuwabara Y, Yoshida T, Fukumura T, Morioka T, Nishio S et al. Carbon-11-methionine PET in focal cortical dysplasia: a comparison with fluorine-18-FDG PET and technetium-99m-ECD SPECT. *J Nucl Med* 1998;39(6):974-7.
- Schwartz TH. Optical imaging of epileptiform events in visual cortex in response to patterned photic stimulation. *Cereb Cortex* 2003;13(12):1287-98.
- Schwartz TH. Neurovascular coupling and epilepsy: hemodynamic markers for localizing and predicting seizure onset. *Epilepsy Curr* 2007;7(4):91-4.
- Schwartz TH, Bonhoeffer T. In vivo optical mapping of epileptic foci and surround inhibition in ferret cerebral cortex. *Nat Med* 2001;7(9):1063-7.
- Schwarz AJ, Gozzi A, Reese T, Bifone A. In vivo mapping of functional connectivity in neurotransmitter systems using pharmacological MRI. *Neuroimage* 2007;34(4):1627-36.
- Sperling MR, Alavi A, Reivich M, French JA, O'Connor MJ. False lateralization of temporal lobe epilepsy with FDG positron emission tomography. *Epilepsia* 1995;36(7):722-7.
- Takano H, Kato M, Inagaki A, Watanabe K, Kashima H. Time course of cerebral blood flow changes following electroconvulsive therapy in depressive patients--measured at 3 time points using single photon emission computed tomography. *Keio J Med* 2006;55(4):153-60.
- Van Paesschen W, Dupont P, Sunaert S, Goffin K, Van Laere K. The use of SPECT and PET in routine clinical practice in epilepsy. *Curr Opin Neurol* 2007;20(2):194-202.

32. Villringer A. Understanding functional neuroimaging methods based on neurovascular coupling. *Adv Exp Med Biol* 1997;413:177-93.
33. Wichert-Ana L, Santos AC, Marques PMA, Oliveira LF, Simões MV, Guarnieri R et al. SPECT and PET in Epilepsy: Principles and Clinical Applications. *Journal of Epilepsy and Clinical Neurophysiology* 2005;11(1):19-30.
34. Wolf HK, Aliashkevich AF, Blumcke I, Wiestler OD, Zentner J. Neuronal loss and gliosis of the amygdaloid nucleus in temporal lobe epilepsy. A quantitative analysis of 70 surgical specimens. *Acta Neuropathol (Berl)* 1997;93(6):606-10.
35. Won HJ, Chang KH, Cheon JE, Kim HD, Lee DS, Han MH et al. Comparison of MR imaging with PET and ictal SPECT in 118 patients with intractable epilepsy. *AJNR Am J Neuroradiol* 1999; 20(4):593-9.
36. Zonta M, Angulo MC, Gobbo S, Rosengarten B, Hossmann KA, Pozzan T et al. Neuron-to-astrocyte signaling is central to the dynamic control of brain microcirculation. *Nat Neurosci* 2003;6(1):43-50.

Address correspondence to:

Lauro Wichert-Ana
Serviço de Medicina Nuclear – Hospital das Clínicas da
Faculdade de Medicina de Ribeirão Preto – USP
Av. Bandeirantes, 3900 – Monte Alegre
CEP: 14.048-900, Ribeirão Preto, SP, Brazil
Phone: (+55-16) 3602-2596, 3602-2613 – Fax: (+55-16) 633-0760
E-mail: lwichert@rnp.fmrp.usp.br