

## The Rare Association of Leukoencephalopathy, Cerebral Calcifications, and Cysts: Case Report

Gustavo Rassier Isolan<sup>a</sup>, Lucas Scotta Cabral<sup>b</sup>, Cláudio Galvão de Castro Júnior<sup>c</sup>, Ápio Cláudio Antunes<sup>d</sup>, Gilberto Schwartzmann<sup>e</sup>, Frederico Soares Falcetta<sup>e</sup>

Medical School – HCPA/UFRGS

### ABSTRACT

Although basal ganglia calcifications were described a long time ago,<sup>1,3,11</sup> the association of leukoencephalopathy, cerebral calcifications, and cysts (LCC) is a very rare entity described in 1996.<sup>5</sup> We present a new case of LCC and discuss clinical, neuroradiologic, and histopathologic findings regarding this association.

**Keywords:** Leukoencephalopathy, cerebral calcifications, brain cysts, epilepsy.

### RESUMO

*A associação rara de leucoencefalopatia, calcificações cerebrais e cistos: relato de caso*

Mesmo que as calcificações dos núcleos da base tenham sido descritas há muito tempo atrás<sup>1,3,11</sup> a associação com leucoencefalopatia, calcificações cerebrais e cistos (LCC) é uma entidade muito rara descrita em 1996.<sup>5</sup> Nós apresentamos um caso novo de LCC e discutimos os achados clínicos, neurorradiológicos e histopatológicos relacionados a essa entidade.

**Unitermos:** Leucoencefalopatia, calcificação cerebral, cisto cerebral, epilepsia.

### CASE REPORT

A 9-year-old male was admitted to our hospital for the evaluation of generalized tonic-clonic seizures, one year ago, and for a balance disorder one month ago. There were no complications during pregnancy. His parents were healthy and not consanguineous. No abnormality was found on general physical and ophthalmologic examinations. Neurologic evaluation showed dysbasia. Complete blood count, sedimentation rate, liver and renal function tests, serum thyroid and parathyroid hormones, calcium,

phosphate, alkaline phosphatase, and lactate levels were within normal limits. Serological tests for cytomegalovirus, *Toxoplasma gondii*, and HIV 1 and 2 were all negative. Cervical, thoracic, and abdominal CT examinations showed no abnormality. Interictal Scalp EEG was normal. The initial CT showed numerous foci of calcifications scattered through the basal ganglia. In MRI, abnormally increased signal intensity was noted in the left temporal and occipital lobes white matter whereas the cortical gray matter was spared. A large pontine cyst was present. Cyst intensity was higher than that of the CSF on T2-weighted, T1-

<sup>a</sup> Division of Neurosurgery, Division of Neurology HCPA/UFRGS. Graduate Program: Surgery, HCPA/UFRGS.

<sup>b</sup> Division of Neurology, HCPA/UFRGS.

<sup>c</sup> Division of Oncology, HCPA/UFRGS.

<sup>d</sup> Division of Neurosurgery, HCPA, UFRGS.

<sup>e</sup> Medical School, UFRGS.

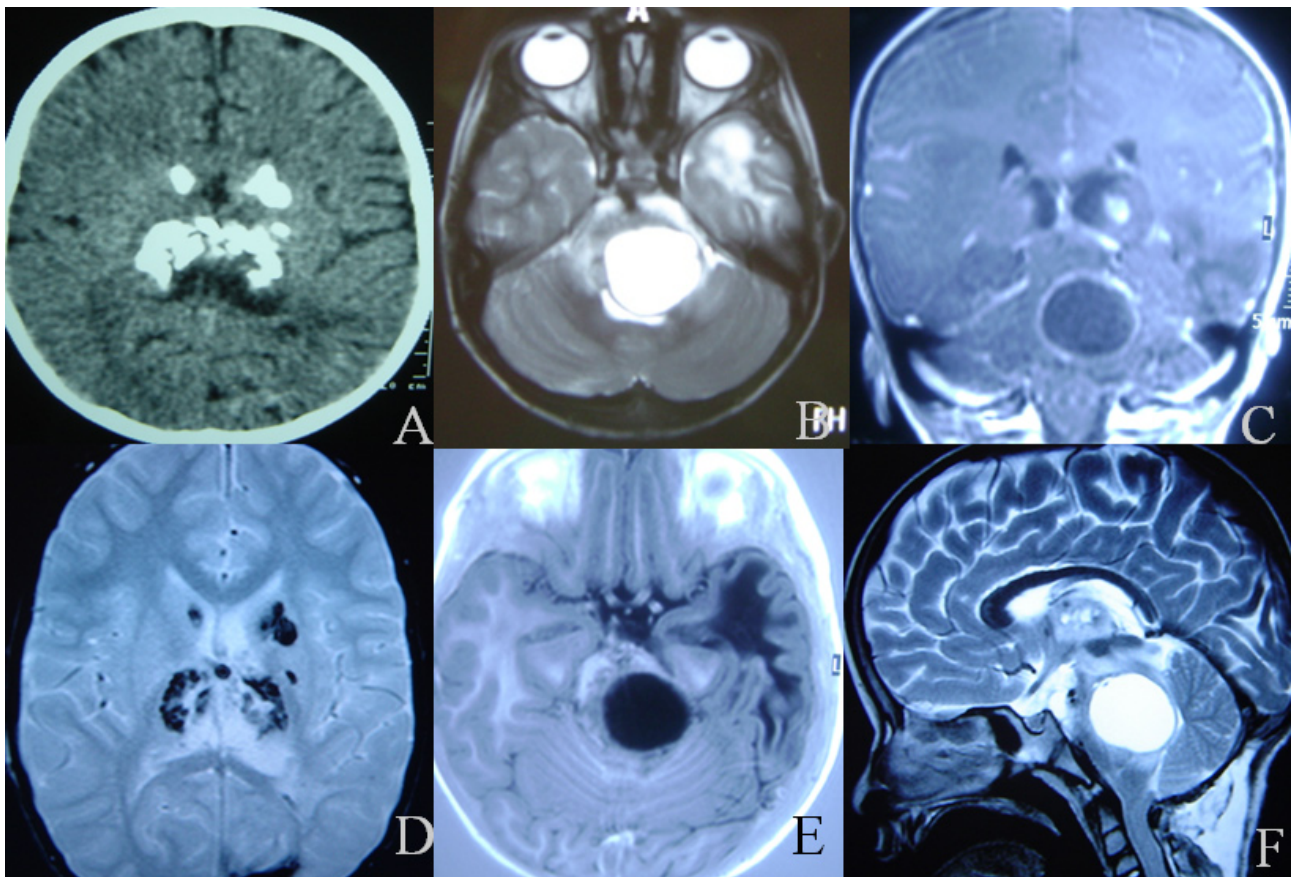
Received June 11, 2010; accepted July 16, 2010.

weighted and fluid-attenuated inversion recovery images. Contrast-enhanced scans showed ring enhancement of the cyst wall. A telovelar approach to the fourth ventricle was performed and a supracollicular puncture was done and the intracystic xanthochromic fluid drained. The balance disturbance improved in the immediate postoperative period. Two months later the patient was readmitted to our clinic because of a CSF leak. A new MRI showed enlargement of the cyst and hydrocephalus. Based on these new findings a ventricular-peritoneal shunt was performed and one week later the pontine cyst was reoperated, but this time with aggressive resection of part of this wall, which was very adherent to the brainstem tissue, followed by cyst drainage. The intra-operative facial nerve monitoring with mapping of the floor of the fourth ventricle was used in this second operation and a supracollicular approach was performed. A shunt was introduced into the cystic cavity communicating it with the subdural space. The CSF leak resolved and the symptoms improved. The histopathologic examination of the cyst wall was inconclusive. The seizures are controlled with carbamazepine.

## DISCUSSION

Leukoencephalopathy, cerebral calcifications and cysts (LCC) is a relatively new entity described in the medical literature. Regarding the clinical significance of each component of this syndrome, it has only really been realized that the triad might have distinct radiopathologic features. Despite the pioneering description of perivascular calcifications in the basal ganglia by Virchow,<sup>11</sup> Bamberger,<sup>1</sup> and Frietzche's<sup>3</sup> first ever radiologic characterization of cysts, LCC only came to our attention after MRI became widely used. LCC was originally described by Labrune et al. in 1996;<sup>5</sup> since then, approximately a dozen cases have been reported in the current medical literature.<sup>2,4,6,7,8,9</sup>

Reinterpretations of older reports linked this entity to Coats' disease, and raised the hypothesis that it would have to be inherited in autosomal recessive fashion.<sup>10</sup> Later it was reported that at least some patients with Coats' disease can present brain calcifications, bringing these entities even closer.<sup>4</sup> However, there is consistent evidence of the post-natal development of pathological hallmarks.<sup>7</sup>



**Figure 1.** Radiological aspects of the association of leukoencephalopathy, cerebral calcification, and cyst. **A.** CT showing basal ganglia calcifications. **B.** Axial T2-weighted MRI image through the brainstem shows the pontine cyst. **C.** Coronal T1-weighted MRI image shows the pontine cyst and its ring enhancement. The same findings shown in Axial T2 MRI (**D**), Axial T1 IR MRI (**E**) and sagittal T2 MRI (**F**).

There have been quite a few advances in the pathological characterization of LCC. On histopathological examination, angiomatous-like rearrangements of the microvessels are prominent. They are associated with Rosenthal fibers, intense gliosis, and microcalcifications; these were hypothesized by Labrune et al as secondary changes.

There is some predilection for the development of parenchymal cysts in the supratentorial compartment and cerebellum. As other pathological conditions – like leukoencephalopathies and tumors – the expanding structure could be the sum of various fluid-containing small cysts,<sup>2</sup> or simply the end effect of increased fluid content on the white matter.<sup>6</sup> This is supported by ADC studies showing increased diffusibility and no diffusion restriction.<sup>8</sup>

It is suggested that an energy dysfunction stimulates cyst formation. This is indicated by spectroscopy studies performed by Nagae-Poetscher et al, which revealed an isolated lactate peak. The presence and significance of demyelization, however, remain controversial. Their study also showed reduced N-acetylaspartate and choline content. Nonetheless, the small sample size, the discordant creatine levels and the acquisition protocols preclude a clear answer to this question.<sup>7</sup>

In the great majority of reported cases, the onset was in childhood and adolescence. However, an adult-onset form is also suggested.<sup>9</sup> The recognized clinical manifestations of LCC include cognitive decline, cerebellar signs and convulsive seizures, although any combination of pyramidal, extrapyramidal and cerebellar signs is possible according to lesion topography.

Overall, progressive calcifications in the basal nuclei, cerebellum and subcortical white matter are very accurately outlined by computed tomography. Diffuse white matter abnormalities and cysts are best appreciated on T2-weighted sequences; there is relative sparing of U-shaped fibers. Contrast-enhanced MRI presents with high signal intensities adjacent to cysts and calcifications,

sometimes with mass effect, suggesting blood-brain barrier disruption.<sup>9</sup>

Little is known about the prognosis; the clinical course is thought to be slowly progressive. There is no proven specific therapy for LCC, other than the suggested symptomatic approach.

## REFERENCES

1. Bamberger PH. Beobachtungen und Bemerkungen bei Hirnkrankheiten. *Verh Phys Med Gesellsch Würzburg* 1855;6:325-8.
2. Ben-Zeev B, Gross V, Kushnir T, et al. Vacuolating megalencephalic leukodystrophy in 12 Israel patients. *J Child Neurol* 2001;16:93-9.
3. Fritzsche R. Eine familiär auftretende Form von Oligophrenie mit röntgenologisch nachweisbaren symmetrischen Kalkablagerungen im Gehirn, besonders in den Stammganglien. *Schweiz Arch Neural Psych.* 1935;35:1-29.
4. Goutieres F, Dollfus H, Becquet F, Dufier JL. Extensive brain calcification in two children with bilateral Coats' disease. *Neuropediatrics* 1999;30:19-21.
5. Labrune P, Lacroix C, Goutieres F, et al. Extensive brain calcifications, leukodystrophy, and formation of parenchymal cysts: a new progressive disorder due to diffuse cerebral microangiopathy. *Neurology* 1996;46:1297-301.
6. Lohle PNM, van Mameren H, Zwindermann KH, et al. On the pathogenesis of brain tumour cysts: a volumetric study of tumour, oedema and cyst. *Neuroradiology* 2000;42:639-42.
7. Nagae-Poetscher LM, Bibat G, Philippart M, et al. Leukoencephalopathy, cerebral calcifications, and cysts: New observations. *Neurology* 2004;62:1206-9.
8. Pierpaoli C, Righini A, Linfante I, Tao-Cheng JH, Alger JR, Di Chiro G. Histopathologic correlates of abnormal water diffusion in cerebral ischemia: diffusion-weighted MR imaging and light and electron microscopic study. *Radiology* 1993;189:439-48.
9. Sener U, Zorlu Y, Men S et al. Leukoencephalopathy, Cerebral Calcifications, and Cysts. *AJNR Am J Neuroradiol.* 2006;27:200-3.
10. Tolmie JL, Browne BH, McGettrick PM, Stephenson JB. A familial syndrome with Coats' reaction retinal angiomas, hair and nail defects and intracranial calcification. *Eye* 1988;2:297-303.
11. Virchow R. Kalk metastases. *Virchows Arch Path Anat.* 1855;8: 103-13.

### Corresponding author:

Gustavo Rassier Isolan  
Hospital de Clínicas de Porto Alegre  
Departamento de Neurologia  
Rua Ramiro Barcelos, 2350  
CEP 90440-050, Porto Alegre, RS, Brasil  
Tel.: (+55) (51) 2101-8182 – Fax: (+55) (51) 3388-5085  
E-mail: gisolan@yahoo.com.br