



## Use of posterior fontanelle in the ultrasound diagnosis of intraventricular/periventricular hemorrhage

Luciana D. V. Gauzzi,<sup>1</sup> Eduardo C. Tavares,<sup>2</sup> César C. Xavier,<sup>3</sup> Flávia F. Corrêa<sup>4</sup>

### Abstract

**Objective:** To evaluate the use of the posterior fontanelle in premature neonates (< 37 weeks) with a birth weight < 1,500 g in the ultrasound diagnosis of intraventricular/periventricular hemorrhage and to assess whether the use of the anterior fontanelle associated with the posterior fontanelle changes the interrater agreement.

**Methods:** Eighty-five premature neonates were evaluated in this prospective study. Ultrasound was performed using the anterior fontanelle, and later, the posterior fontanelle. A consensus diagnosis between two raters was used to analyze the agreement between the anterior fontanelle alone and in association with the posterior fontanelle. If there was no consensus, a third observer was involved to decide.

**Results:** Agreement between the first two raters had a kappa of 0.80 (95%CI 0.76-0.84). However, when the anterior fontanelle was evaluated alone, kappa was 0.74 (95%CI 0.70-0.78). Thirty-seven hemispheres had grade II hemorrhage, of which 17 (45.9%) had their diagnosis performed using the anterior fontanelle; in 10 (27%), diagnosis was suspected by the anterior fontanelle and confirmed by the posterior fontanelle; and in 10 (27%), diagnosis was exclusively performed using the posterior fontanelle. Of the 454 hemispheres, in 20 (4.4%) the diagnosis of intraventricular hemorrhage was performed exclusively by the posterior fontanelle ( $p < 0.001$ ).

**Conclusions:** In this study, the anterior fontanelle associated with the posterior fontanelle was better than the use of the anterior fontanelle alone in the identification of intraventricular/periventricular hemorrhage. Ultrasound using the posterior fontanelle allowed diagnosis of unsuspected grade II hemorrhage by the anterior fontanelle. Use of the posterior fontanelle was also useful to clarify presence of hemorrhage in inconclusive examinations by the anterior fontanelle.

*J Pediatr (Rio J). 2008;84(6):503-508: Brain hemorrhage, ultrasound, premature.*

### Introduction

Accuracy of an examination refers to the agreement it has with a gold standard test. In neurosonography the gold standard is the histopathological examination (necropsy). Therefore, accuracy of cranial ultrasound cannot be evaluated directly in live patients. In addition, another difficulty in its evaluation is the need of a short interval between the ultrasound and the necropsy examination. The longer this inter-

val, the higher the possibility of lesions after performing the examination. Studies correlating ultrasound and necropsy findings found errors in 8-34% of cases of intraventricular hemorrhage in neonates.<sup>1-3</sup>

The anterior fontanelle is a commonly used window for ultrasound; when used alone, it has some limitations in the assessment of the occipital region and posterior fossa. Small blood clots may be located in the occipital horn of the lateral

1. Mestre. Universidade Federal de Minas Gerais (UFMG), Belo Horizonte, MG, Brazil.
2. Doutor. UFMG, Belo Horizonte, MG, Brazil.
3. Doutor. Universidade de São Paulo (USP), São Paulo, SP, Brazil.
4. Doutora. Universitat Autònoma de Barcelona, Barcelona, Spain.

The ultrasound device employed in this study was provided by Hospital das Clínicas, Universidade Federal de Minas Gerais (UFMG), Belo Horizonte, MG, Brazil.

No conflicts of interest declared concerning the publication of this article.

**Suggested citation:** Gauzzi LD, Tavares EC, Xavier CC, Corrêa FF. Use of posterior fontanelle in the ultrasound diagnosis of intraventricular/periventricular hemorrhage. *J Pediatr (Rio J)*. 2008;84(6):503-508.

Manuscript received Jun 25 2008, accepted for publication Oct 01 2008.

doi:10.2223/JPED.1855

ventricle, tending to adhere to the choroid plexus and ventricular wall. With the aim of improving accuracy of neurosonography, some authors described other windows to perform the neurosonographic examination, such as the posterior and posterolateral or mastoid fontanelle.<sup>4-9</sup> The posterior fontanelle is usually open until the third month of life and is located at the junction of sagittal and lambdoid sutures.<sup>10</sup> Use of posterior fontanelle allows for diagnosis of intraventricular/periventricular hemorrhage (IPH), in which examination using the anterior fontanelle does not detect any changes.<sup>9,11</sup>

This study aims at evaluating the role of the posterior fontanelle in the diagnosis of IPH in premature neonates with birth weight < 1,500 g and verifying whether use of the anterior fontanelle associated with the posterior fontanelle changes interrater agreement.

## Methods

This is a prospective study of a convenience sample conducted at the neonatal unit of Hospital das Clínicas, Universidade Federal de Minas Gerais, Brazil. Inclusion criteria were premature neonates with weight < 1.500 g, born at Hospital das Clínicas, Universidade Federal de Minas Gerais and that were admitted at the neonatal unit in the first day of life from August 2004 to July 2005. Exclusion criteria were the neonates that were sent to other units in the same hospital in the first day of life (for example, pediatric intensive care unit), or transferred to other hospitals.

Examinations in which the posterior fontanelle was not accessible in the following conditions were also excluded: inadequacy of the acoustic window, impossibility of proper placement due to severity of clinical status and also in neonates that, due to the patient's clinical severity, prolonged procedure time could be harmful.

The study using the posterior fontanelle was added to the neurosonography, commonly performed using the anterior fontanelle. Adding this approach increases procedure time in only a few minutes, and does not bring additional risks to the neonate.

The protocol to perform neurosonographic examinations follows the routine proposed by Perlman & Rollins<sup>12</sup>: for all premature neonates with birth weight < 1.500 g, the first examination should be performed between 3-5 days of life and another examination close to hospital discharge; for the neonates with birth weight < 1,250 g an examination at 28 days of life was recommended; and for those with birth weight < 1,000 g an examination was suggested at 14 days of life. The ultrasounds were also requested by the pediatrician or neurologist, whenever there was clinical indication, such as, for example, in the presence of fontanelle bulging, or sudden fall in hematocrit. In case of performing more than one ultrasound per neonate, all the examinations were included.

Neurosonographic examinations were performed by the first rater, initially using the anterior fontanelle, and next the posterior fontanelle. The second rater reevaluated the ultrasounds using video recordings, which were further digitalized, without previous knowledge of the first rater's impressions. The calculation of interrater agreement was performed based on this double-blind evaluation.

The criteria to define ultrasound diagnosis used in the evaluation of interrater agreement between the examinations performed using the anterior fontanelle alone and in association with the posterior fontanelle were as follows: initially the examinations that were in agreement between the first and second raters; next, the examinations that were in disagreement between the first and second raters were reviewed by both raters with the previous knowledge of each rater's result, and a diagnostic consensus was reached after such review; a third rater defined the diagnosis for the ultrasounds in which it was not possible to have a consensus after review by the first and second raters. The raters had no access to the patient's clinical history.

A Digital Gaia MT device was used in real time with a sector transducer with frequency of 5.5-7.5 MHz. The examinations were recorded in an LG videocassette recorder, model LG67SB, in EMETC-EQ T-160 tapes using SP quality. Later, the examinations were digitalized using MPEG-4 (Motion Picture Experts Group) video quality.

The examinations were performed by placing the child in the prone position with lateral or prone head in the incubator or heated cradle. In some cases, when the child's clinical status allowed, the examination was performed in the mother's lap.

The examinations using the anterior fontanelle were initially performed by anterior (in front of the foramen of Monro), medium (immediately posterior to the foramen of Monro), and posterior coronal sections; midline sagittal section; and bilateral parasagittal section.<sup>13</sup>

Using the posterior fontanelle, parasagittal sections were obtained to show the occipital horn; coronal sections were obtained at the supraventricular level, of the trigone and occipital horn at the calcarine fissure level to show the posterior occipital horn to the choroid plexus.<sup>9,14</sup> Examinations were considered satisfactory when both occipital horns were properly seen in coronal, sagittal sections or in both.<sup>11</sup> Hemorrhages were described using Papile's classification based on a prospective study with brain computed tomography, which further also proved to be adequate to the ultrasound study.<sup>15</sup>

A sample calculation was performed using the Epi Info software, version 6.04, considering expected frequency of the event in the study of 17.5% with accuracy of 2.5% (frequency between 15-20%) and 95% confidence interval, with target population of 85 corresponding to a sample of 77.

**Table 1** - Distribution of intraventricular/periventricular hemorrhage identified by the anterior fontanelle alone vs. anterior and posterior fontanelle\*

| Anterior fontanelle<br>IPH – grade | Anterior fontanelle associated with posterior fontanelle |    |    |            |    |    | Total |
|------------------------------------|--|----|----|------------|----|----|-------|
|                                    | Absent   | 1  | 2  | 2 doubtful | 3  | 4  |       |
| Absent                             | 267  | 0  | 0  | 0          | 0  | 0  | 267   |
| 1                                  | 0  | 59 | 10 | 0          | 0  | 0  | 69    |
| 2                                  | 0  | 0  | 17 | 0          | 0  | 0  | 17    |
| 2 doubtful                         | 15   | 4  | 10 | 0          | 0  | 0  | 29    |
| 3                                  | 0  | 0  | 0  | 0          | 50 | 0  | 50    |
| 4                                  | 0  | 0  | 0  | 0          | 0  | 22 | 22    |
| Total                              | 282  | 63 | 37 | 0          | 50 | 22 | 454   |

\* Kappa = 0.86,  $p < 0.001$ .

For the statistical analysis, hemorrhages were also described as present, dubious or absent for each fontanelle. The calculations were also performed using the Epi Info, version 6.04. Kappa's coefficient was used for agreement analysis. Agreement was classified as poor when kappa coefficient was lower than 0.4, good between 0.41-0.75, and excellent when higher than 0.75.

Agreement between the first and second raters was initially compared using only the anterior fontanelle. Next, it compared with the agreement obtained from both fontanelles. Evaluation was performed considering conclusion of each brain hemisphere alone.

Agreement between reviewed results obtained by anterior fontanelle alone and anterior fontanelle combined with posterior fontanelle was evaluated using kappa's test. Analysis was also stratified according to grade of hemorrhage. McNemar's chi-square test was used to evaluate the proportion in which diagnosis of IPH was equal for each fontanelle.

The research project was approved by the Research Ethics Committee at UFMG (299/04), Belo Horizonte, MG, Brazil. The examinations were performed according to the protocol used at the institution. Therefore, unnecessary ultrasounds without clinical indication were not performed, preserving the neonates.

## Results

The initial sample was comprised of 88 children. One was not included in the study because her parents did not consent to her participation. There were two (2.4%) losses because the examination was not performed in the first week of life. The three children had normal ultrasound results.

Of 85 children, 48 (56.5%) were female. Mean birth weight was 1,111±253 g, ranging between 500 and 1,490 g. Thirty neonates (35.3%) had birth weight lower than 1,000 g. Mean gestational age at birth was 29.3±2.3 weeks, ranging between 25 and 35 weeks.

The first examination was performed in all neonates from the first to the sixth day of life, mean 3.7±1.1 days. Mean number of neurosonographic examinations per patient was 2.8, resulting in a total of 236 examinations. Of these, ultrasound was performed using the anterior fontanelle alone in nine patients (3.8%). The posterior acoustic window was considered dissatisfactory in two neurosonographic examinations, both performed in neonates older than 30 days of chronological age. The reason for not performing the examinations using the posterior fontanelle in the other seven patients was clinical instability, which was already present before starting the ultrasound. Therefore, 227 examinations were performed using the posterior fontanelle. As each brain hemisphere was analyzed individually, there were 454 evaluations in total. Occurrence of IPH was 48.2%. Incidence according to grade of hemorrhage following Papile's classification was grade I, 23.5%; grade II, 12.9%; grade III, 4.7%; and grade IV, 7.1%.

Interrater agreement assessing only the results obtained by the anterior fontanelle had kappa coefficient of 0.74 (95%CI 0.70-0.78,  $p < 0.001$ ). When the fontanelles were assessed in association, kappa was 0.80 (95%CI 0.76-0.84,  $p < 0.001$ ).

Agreement between the examination using the anterior fontanelle alone and associated with the posterior fontanelle in the entire sample was 91%, and kappa index was 0.86, with  $p < 0.001$  (Table 1). When it was performed in hemispheres diagnosed with grade I and II IPH using the anterior fontanelle, agreement was 64% and kappa coefficient was 0.47 (95%CI 0.38-0.56,  $p < 0.001$ ). In hemispheres with final diagnosis of grade II IPH, agreement was 32.7% and kappa coefficient was 0.05 (95%CI 0.01-0.16,  $p = 0.19$ ) (Table 2).

In 39 hemispheres (8.6%) the posterior fontanelle was useful to clarify diagnosis of IPH. In 10 (2.2%) hemispheres diagnosis of grade II IPH was only possible using the posterior fontanelle, since impression was of grade I hemorrhage

**Table 2** - Description of agreement between the anterior fontanelle compared with the anterior fontanelle associated with the posterior fontanelle

|                    | Agreement (%) | Kappa | p       |
|--------------------|---------------|-------|---------|
| All patients       | 91            | 0.86  | < 0.001 |
| Grade I and II IPH | 64            | 0.44  | < 0.001 |
| Grade II IPH       | 33            | 0.05  | 0.19    |

IPH = intraventricular/periventricular hemorrhage.

using the anterior fontanelle. In 19 (4.2%) hemispheres there was doubt as to diagnosis of grade II IPH, which was discarded with the aid of the posterior fontanelle. In 10 (2.2%) hemispheres there was suspicion of grade II hemorrhage using the anterior fontanelle, confirmed by the posterior fontanelle.

Thirty-seven hemispheres had grade II IPH, of which 17 (46%) had their diagnosis performed using the anterior fontanelle; in 10 (27%), diagnosis was suspected by the anterior fontanelle and confirmed by the posterior fontanelle; and in 10 (27%), diagnosis was exclusively performed using the posterior fontanelle (Fig. 1). Of the 454 brain hemispheres evaluated, use of the posterior fontanelle allowed diagnosis of grade II IPH to be performed in 20 (4.4%).

McNemar's chi-square was 18.5,  $p < 0.001$ .

The third rater assessed the examinations of 85 patients that had no consensus between the first and second raters. In this assessment, for two patients diagnosed with grade II IPH by the first rater had this diagnosis discarded by the second and third raters. In two more patients, the first rater diagnosed grade II hemorrhage, and the third rater confirmed this diagnosis, opposing the second rater's opinion, who had considered it as normal.

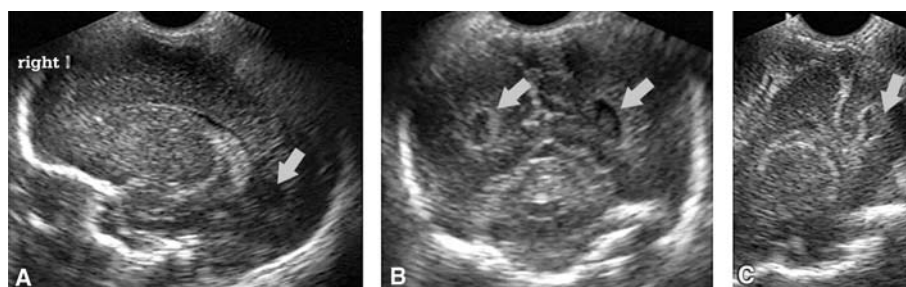
With the aim of evaluating the real benefit of routine indication of the posterior fontanelle in the examination of all children with birth weight < 1,500 g, evaluations were performed only in cases in which there were unsuspected changes in the

examination using the anterior fontanelle. In 10 (2.2%) hemispheres diagnosis of grade II IPH was only possible using the posterior fontanelle, since impression was of grade I hemorrhage using the anterior fontanelle. McNemar's chi-square test was 8.10,  $p = 0.004$ . However, in all hemispheres in which grade II IPH was detected only using the posterior fontanelle, result of the examination using the anterior fontanelle was of grade I hemorrhage. There were no normal examinations using the anterior fontanelle diagnosed with grade II hemorrhage by the posterior fontanelle.

### Discussion

Agreement between the examinations obtained by the anterior fontanelle alone and in association with the posterior fontanelle evaluating the entire sample was excellent (kappa > 0.75). Agreement was lower when only patients diagnosed with grade I and II IPH were assessed.

In the group of patients with grade II hemorrhage, kappa had poor agreement, but p value was not significant. The small number of hemispheres with grade II IPH could be a justification for such finding. Because of the reduction in agreement in the group of patients with hemorrhage without ventricular dilatation, it could be assumed that use of the posterior fontanelle is particularly useful in this group as it could improve the rater's evaluation. Use of the posterior fontanelle contributed to detection of hemorrhage in nine (10.6%) out of 85 children in whom the examination was performed by the posterior fontanelle.



**Figure 1** - A) Image using the anterior fontanelle, right parasagittal section, no presence of intraventricular blood; B) image using the posterior fontanelle, coronal section performed at the occipital horn level, presence of blood clots bilaterally (arrows); C) image using the posterior fontanelle, right parasagittal section, blood clot seen in the occipital horn (arrow)

Correa et al.<sup>9</sup> described use of the posterior fontanelle in 164 premature neonates with birth weight lower than 2,000 g. Use of the posterior fontanelle increased detection of grade II hemorrhage in 32%. There was an increase in ultrasound accuracy to detect IPH in patients that had no ventricular dilatation. Anderson et al.<sup>5</sup> studied 259 neonates; of these, 34 had IPH. Presence of hemorrhage was detected by the posterior fontanelle, but not by the anterior fontanelle in 14 patients.<sup>11</sup>

Identification of IPH without ventricular dilatation is more difficult due to the fact that the choroid plexus and bleeding during acute stage are hyperechogenic.<sup>16</sup> The blood clot may adhere to the choroid plexus, which makes diagnosis difficult with a bifurcated choroid plexus.

The calcar avis, which forms the medial wall of the lateral ventricle occipital horn, when prominent can also be mistaken by a blood clot reabsorption located in the posterior horn.<sup>17</sup> False-positive results of grade II hemorrhage can also be due to presence of choroid plexus congestion.<sup>18</sup> In the presence of large amounts of blood in the ventricle, with secondary ventricular dilatation, grade III hemorrhage, there is a lower interrater disagreement rate and a higher ultrasound sensitivity in its diagnosis.<sup>19</sup>

Interrater agreement increased when use of the posterior fontanelle alone was compared with the anterior fontanelle in association with the posterior fontanelle. However, there was overlapping of 95% confidence intervals, but such difference was not statistically different.

The need of improving the accuracy of diagnostic methods to detect grade I and II IPH comes from a higher incidence of cognitive changes and cerebral palsy in this group of premature patients, when compared with those of cranial ultrasound with no changes.<sup>20,21</sup> A study with three-dimensional magnetic resonance of the brain found volumetric reduction in cortical gray matter in children with non-complicated IPH (without ventricular dilatation, without parenchymal lesion).<sup>22</sup>

Convenience sample and lack of a gold standard are the main limitations of this study. In addition, disagreeing studies between the first and second raters were reviewed together. Therefore, a bias might have been created in the interpretation of disagreeing examinations. Only disagreeing examinations in which no final conclusion was reached were evaluated by a third rater. It would have been more adequate if all examinations had been evaluated by the third rater.

High rate of hemorrhage in the sample could be explained because it is a convenience sample. Furthermore, the higher the prematurity level, the higher the risk of IPH. Mean gestational age of the population was 29 weeks.

In this study the anterior fontanelle associated with the posterior fontanelle was better than use of the anterior fontanelle alone in the identification of IPH. Ultrasound using the

posterior fontanelle in neonates with birth weight lower than 1,500 g allowed diagnosis of unsuspected grade II IPH by the anterior fontanelle. Use of the posterior fontanelle was also useful to clarify presence of grade II hemorrhage in inconclusive examinations by the anterior fontanelle.

## References

- Adcock LM, Moore PJ, Schlesinger AE, Armstrong DL. [Correlation of ultrasound with postmortem neuropathologic studies in neonates](#). *Pediatr Neurol*. 1998;19:263-71.
- Pape KE, Bennett-Britton S, Szymonowicz W, Martin DJ, Fitz CR, Becker L. [Diagnostic accuracy of neonatal brain imaging: a postmortem correlation of computed tomography and ultrasound scans](#). *J Pediatr*. 1983;102:275-80.
- Trounce JQ, Fagan D, Levene MI. [Intraventricular haemorrhage and periventricular leucomalacia: ultrasound and autopsy correlation](#). *Arch Dis Child*. 1986;61:1203-7.
- Cohen HL, Haller JO. [Advances in perinatal neurosonography](#). *AJR Am Roentgenol*. 1994;163:801-10.
- Anderson NG, Hay R, Hutchings M, Whitehead M, Darlow B. [Posterior fontanelle cranial ultrasound: anatomic and sonographic correlation](#). *Early Hum Dev*. 1995;42:141-52.
- de Vries LS, Eken P, Beek E, Groenendaal F, Meiners LC. [The posterior fontanelle: a neglected acoustic window](#). *Neuropediatrics*. 1996;27:101-4.
- Enriquez G, Correa F, Aso C, Carreño JC, Gonzalez R, Padilla NF, et al. [Mastoid fontanelle approach for sonographic imaging of the neonatal brain](#). *Pediatr Radiol*. 2006;36:532-40. Epub 2006 Apr 7.
- Luna JA, Goldstein RB. [Sonographic visualization of neonatal posterior fossa abnormalities through the posterolateral fontanelle](#). *AJR Am Roentgenol*. 2000;174:561-7.
- Correa F, Enriquez G, Rosselló J, Lucaya J, Piqueras J, Aso C, et al. [Posterior fontanelle sonography: an acoustic window into neonatal brain](#). *AJNR Am J Neuroradiol*. 2004;25:1274-82.
- Adeyemo AA, Omotade OO. [Variation in fontanelle size with gestational age](#). *Early Hum Dev*. 1999;54:207-14.
- Anderson N, Allan R, Darlow B, Malpas T. [Diagnosis of intraventricular hemorrhage in the newborn: value of sonography via the posterior fontanelle](#). *AJR Am Roentgenol*. 1994;163:893-6.
- Perlman JM, Rollins N. [Surveillance protocol for detection of intracranial abnormalities in premature neonates](#). *Arch Pediatr Adolesc Med*. 2000;154:822-6.
- Cremin BJ, Chilton SJ, Peacock WJ. [Anatomical landmarks in anterior fontanelle ultrasonography](#). *Br J Radiol*. 1983;56:517-26.
- Di Salvo DN. [A new view of the neonatal brain: clinical utility of supplemental neurologic US imaging windows](#). *Radiographics*. 2001;21:943-55.
- Papile LA, Burstein J, Burstein R, Koffler H. [Incidence and evolution of subependymal and intraventricular hemorrhage: a study of infants with birth weights less than 1,500 g](#). *J Pediatr*. 1978;92:529-34.
- Fiske CE, Filly RA, Callen PW. [The normal choroid plexus: ultrasonographic appearance of the neonatal head](#). *Radiology*. 1981;141:467-71.

17. DiPietro MA, Brody BA, Teele RL. [The calcar avis: demonstration with cranial US](#). *Radiology*. 1985;156:363-4.
18. Szymonowicz W, Schafner K, Cussen LJ, Yu VY. [Ultrasound and necropsy study of periventricular haemorrhage in preterm infants](#). *Arch Dis Child*. 1984;59:637-42.
19. O'Shea TM, Volberg F, Dillard RG. [Reliability of interpretation of cranial ultrasound examinations of very low-birthweight neonates](#). *Dev Med Child Neurol*. 1993;35:97-101.
20. Ment LR, Schneider KC, Ainley MA, Allan WC. [Adaptive mechanisms of developing brain. The neuroradiologic assessment of the preterm infant](#). *Clin Perinatol*. 2000;27:303-23.
21. Patra K, Wilson-Costello DW, Taylor HG, Mercuri-Minich N, Hack M. [Grades I-II intraventricular hemorrhage in extremely low birth weight infants: effects on neurodevelopment](#). *J Pediatr*. 2006;149:169-73.
22. Vasileiadis GT, Gelman N, Han VK, Williams LA, Mann R, Bureau Y, et al. [Uncomplicated intraventricular hemorrhage is followed by reduced cortical volume at near-term age](#). *Pediatrics*. 2004;114:e367-72.

Correspondence:

Luciana Dolabela Velloso Gauzzi  
Rua Padre Rolim, 515/505  
CEP 30130-090 - Belo Horizonte, MG - Brazil  
Tel.: +55 (31) 3241.8284  
Fax: +55 (31) 3241.8284  
E-mail: lgauzzi@yahoo.com.br