



REVIEW ARTICLE

Assessment of acute motor deficit in the pediatric emergency room[☆]



Marcio Moacyr Vasconcelos^{a,*}, Luciana G.A. Vasconcelos^b, Adriana Rocha Brito^a

^a Universidade Federal Fluminense (UFF), Hospital Universitário Antônio Pedro, Departamento Materno Infantil, Niterói, RJ, Brazil

^b Associação Brasileira Beneficente de Reabilitação (ABBR), Divisão de Pediatria, Rio de Janeiro, RJ, Brazil

Received 21 May 2017; accepted 28 May 2017

Available online 27 July 2017

KEYWORDS

Acute weakness;
Motor deficit;
Guillain–Barré
syndrome;
Transverse myelitis;
Child

Abstract

Objectives: This review article aimed to present a clinical approach, emphasizing the diagnostic investigation, to children and adolescents who present in the emergency room with acute-onset muscle weakness.

Sources: A systematic search was performed in PubMed database during April and May 2017, using the following search terms in various combinations: “acute,” “weakness,” “motor deficit,” “flaccid paralysis,” “child,” “pediatric,” and “emergency”. The articles chosen for this review were published over the past ten years, from 1997 through 2017. This study assessed the pediatric age range, from 0 to 18 years.

Summary of the data: Acute motor deficit is a fairly common presentation in the pediatric emergency room. Patients may be categorized as having localized or diffuse motor impairment, and a precise description of clinical features is essential in order to allow a complete differential diagnosis. The two most common causes of acute flaccid paralysis in the pediatric emergency room are Guillain–Barré syndrome and transverse myelitis; notwithstanding, other etiologies should be considered, such as acute disseminated encephalomyelitis, infectious myelitis, myasthenia gravis, stroke, alternating hemiplegia of childhood, periodic paralyses, brainstem encephalitis, and functional muscle weakness. Algorithms for acute localized or diffuse weakness investigation in the emergency setting are also presented.

Conclusions: The clinical skills to obtain a complete history and to perform a detailed physical examination are emphasized. An organized, logical, and stepwise diagnostic and

[☆] Please cite this article as: Vasconcelos MM, Vasconcelos LG, Brito AR. Assessment of acute motor deficit in the pediatric emergency room. J Pediatr (Rio J). 2017;93:26–35.

* Corresponding author.

E-mail: mmdvascon@gmail.com (M.M. Vasconcelos).

PALAVRAS-CHAVE

Fraqueza aguda;
Déficit motor;
Síndrome de
Guillain–Barré;
Mielite transversa;
Criança

therapeutic management is essential to eventually restore patient's well-being and full health.

Published by Elsevier Editora Ltda. on behalf of Sociedade Brasileira de Pediatria. This is an open access article under the CC BY-NC-ND license (<http://creativecommons.org/licenses/by-nc-nd/4.0/>).

Avaliação do déficit motor agudo no ambiente de pronto socorro pediátrico**Resumo**

Objetivos: O objetivo deste artigo de revisão é apresentar uma abordagem clínica, enfatizando a investigação diagnóstica, voltada para crianças e adolescentes no pronto socorro com fraqueza muscular de surgimento agudo.

Fontes: Foi realizada uma pesquisa sistemática na base de dados PubMed entre abril e maio de 2017, utilizando os seguintes termos de pesquisa em várias combinações: "agudo", "fraqueza", "déficit motor", "paralisia flácida", "criança", "pediátrico" e "emergência". Os trabalhos escolhidos para esta revisão foram publicados nos últimos dez anos, de 1997 a 2017. Este trabalho aborda a faixa etária pediátrica, de 0 a 18 anos.

Resumo dos dados: O déficit motor agudo é uma causa razoavelmente comum para crianças e adolescentes procurarem o pronto socorro. Os pacientes podem ser classificados como apresentando deficiência motora localizada ou difusa, e uma descrição precisa das características clínicas é essencial para possibilitar um diagnóstico diferenciado completo. As duas causas mais comuns de paralisia flácida aguda no pronto socorro pediátrico são síndrome de Guillain-Barré e mielite transversa, independentemente de outras etiologias serem consideradas, como encefalomielite disseminada aguda, mielite infecciosa, miastenia grave, derrame, hemiplegia alternante da infância, paralisia periódica, encefalite do tronco encefálico e fraqueza muscular funcional. Os algoritmos da investigação de fraqueza aguda localizada ou difusa na configuração de emergência também são apresentados.

Conclusões: São enfatizadas as habilidades clínicas para obter um histórico completo e realizar um exame físico detalhado. Um manejo diagnóstico e terapêutico organizado, lógico e por etapas é essencial para eventualmente restaurar o bem-estar e a saúde total do paciente.

Publicado por Elsevier Editora Ltda. em nome de Sociedade Brasileira de Pediatria. Este é um artigo Open Access sob uma licença CC BY-NC-ND (<http://creativecommons.org/licenses/by-nc-nd/4.0/>).

Introduction

Acute motor deficit or weakness is a fairly common presentation in the pediatric emergency room (ER). Across all age ranges, 5% of all patients visiting the ER have neurologic symptoms.¹ In this setting, the pediatrician must be comfortable in performing the initial workup, as some etiologies may be life-threatening and demand urgent care. Timely interventions are likely to restore patient's well-being and full health.

Weakness is categorized as a negative motor sign, as well as ataxia and apraxia. It is valuable to have a firm grasp on the definition of these three negative motor signs. *Weakness* is defined as the inability to generate normal voluntary *force* in a muscle or normal voluntary *torque* in a joint, while *ataxia* is the inability to generate a normal voluntary movement *trajectory* that cannot be attributed to weakness or involuntary muscle activity in the affected joints.² Ataxic movements are uncoordinated and clumsy, but there is no underlying weakness of the

involved muscles. *Apraxia* is the inability to perform *previously learned* complex movements, which is not explained by weakness, ataxia, or involuntary motor activity, *i.e.*, the motor, sensory, basal ganglia, and cerebellar functions are intact.² It is noteworthy that sensory weakness does not exist.

For the purpose of this study, plegia will be used to denote complete or partial weakness,³ but the reader is informed that strictly speaking *plegia* means complete paralysis and *paresis* implies that muscle strength is only partially affected. A common descriptor of acute weakness is *acute flaccid paralysis*, meaning that in the ER setting, paralysis is usually not accompanied by spasticity or other abnormal signs of central nervous system (CNS) motor tracts, *e.g.*, hyperreflexia, clonus, or Babinski reflex.⁴

This study aimed to present a clinical diagnostic approach to children and adolescents who present with an acute motor deficit in the ER and to review the most frequent etiologies.

Methods

A systematic search was performed in PubMed database during April and May 2017, using the following search terms in various combinations: “acute,” “weakness,” “motor deficit,” “flaccid paralysis,” “child,” “pediatric,” and “emergency”. The articles chosen for this review were published over the past ten years, from 1997 through 2017. This study assessed the pediatric age range, from 0 to 18 years.

Clinical features and differential diagnosis

Acute weakness may present either as a localized or diffuse impairment. A precise description of the motor deficit

— its mode of onset, duration, and progression — is essential to allow a complete differential diagnosis. In this sense, a detailed history and a full physical examination, including an objective neurologic examination, provide the best opportunities to expedite etiology identification. [Table 1](#) outlines the essential information to be compiled during the initial approach of a patient presenting with acute weakness.

The pattern through which weakness extends to other body parts may offer clues to diagnosis. For example, a relatively symmetric, ascending deficit suggests Guillain-Barré syndrome (GBS), while a descending paralysis raises suspicion of botulism.⁵

Some patients will present to the ER with what appears to be acute weakness, but a thorough assessment will

Table 1 History and physical examination of a patient with acute motor deficit.

History

- Is this the first time the child presents with weakness?
- Onset – where was the child and what was he/she doing when the deficit was detected?
- Rhythm – abrupt, rapidly or slowly progressing, fluctuating or remitting–recurring?
- Is the weakness associated with any precipitating factors, such as a place, a person, a food, a medication, or a time of the day?
- Does the weakness improve with rest and worsen with activity (fatigability)?
- Has there been an increased frequency of falls in the recent past?
- Has the weakness progressed in an ascending or descending mode?
- Associated symptoms of infection (fever, headache, vomiting, diarrhea) or of a concurrent disease
- Preceding or concomitant sensory symptoms, such as pain/tenderness, dysesthesias, numbness, headache, or visual disturbances
- Changes in urination and bowel habits
- Mental status changes – has there been any impairment in patient’s mental status?
- History of recent infections and other illnesses
- Use of all medications, including herbal medicine, eye drops, *etc.*
- Developmental history – ages of motor skills acquisition, any regression, other areas of development
- History of trauma, especially to the head and back
- History of seizures
- Contact with other ill individuals
- Psychosocial history – recent stress, interactions with peers, school performance, behavioral issues, death or departure of loved ones
- Contact with pets and other animals

Physical and neurologic examination

- Vital signs
- Head circumference
- Growth parameters
- Body symmetry
- Nuchal rigidity and other meningeal signs
- Respiratory distress signs
- Mental status – alertness, irritability, orientation to time and place, language skills
- Cardiovascular and respiratory systems and abdomen examination
- Cranial nerve examination – pupils’ size and reaction to light? Visual acuity? Funduscopy? Facial weakness? Extraocular muscle movements? Palate and tongue movements?
- Motor examination – muscle tonus and strength, deep tendon reflexes, ankle clonus, pronator-drift test
- Babinski sign
- Sensory examination searching for a sensory level
- Coordination – finger-to-nose test, diadochokinesia
- Gait – is the child able to sit or to walk without/with support? Walking on tiptoes, on ankles
- Signs of a chronic muscle disease, *e.g.*, muscle atrophy, fasciculations, myotonia, Gowers’ sign

Table 2 Etiologies of an acute diffuse motor deficit.

<i>Most common etiologies</i>
Guillain–Barré syndrome
Transverse myelitis
<i>Other etiologies</i>
Acute disseminated encephalomyelitis (ADEM)
Alternating hemiplegia of childhood
Atlantoaxial dislocation
Botulism
Brain abscess
CNS infections, e.g., acute meningitis
CNS mass lesions
Chronic inflammatory demyelinating polyneuropathy (CIDP)
Complicated migraine
Congenital myopathies
Epilepsy, i.e., Todd's palsy
Familial spastic paraplegia
Functional muscle weakness (formerly called conversion disorder)
Hypoglycemia
Hypophosphatemia
Hopkins syndrome (associated with acute asthma)
Infectious myelitis (e.g., by enterovirus)
Intracranial hemorrhage
Kawasaki disease
Metabolic disease
Myasthenia gravis
Periodic paralyses
Spinal cord compression
Vaccine-associated poliomyelitis
Vasculitis
Stroke

CNS, central nervous system.

reveal that in fact he/she has *pseudoparalysis*, i.e., muscle strength is preserved and the motor function is impaired by another mechanism, most often severe pain. Common pediatric examples of this situation are inability to walk due to calf pain secondary to acute viral myositis, pyogenic arthritis-related arthralgia (e.g., gonococcal arthritis in teenagers), nursemaid's elbow, or bone pain secondary to osteomyelitis, bone fracture, or dislocation.

Since the eradication of poliomyelitis, the two most common causes of acute flaccid paralysis in the ER are GBS and acute transverse myelitis.⁶ Among other etiologies (Table 2), the most relevant for the pediatric age group are acute disseminated encephalomyelitis (ADEM), infectious myelitis, myasthenia gravis (MG), stroke, alternating hemiplegia of childhood, periodic paralyses, brainstem encephalitis, and functional muscle weakness.

Guillain–Barré syndrome

GBS, or acute inflammatory demyelinating polyradiculoneuropathy (AIDP), is an autoimmune disease that usually

presents with acute onset of a rapidly progressive, essentially symmetric weakness and areflexia in a previously well child.⁷ The acute weakness in GBS tends to begin distally and to progress rostrally, and in 50–70% of cases it is preceded within four weeks by an acute respiratory or gastrointestinal infection. The etiologic agents most frequently involved are *Campylobacter jejuni* and *Helicobacter pylori* in the gastrointestinal tract, and *Mycoplasma pneumoniae* in the respiratory tract. An annual incidence of 0.5–2 cases per 100,000 individuals has been reported in the age range <18 years.⁸ In less than 10% of cases, GBS is associated with vaccination in the preceding 30 days.⁹

AIDP is actually a descriptive term for the most common clinical presentation of GBS, while in 10–15% of cases, the clinical features comprise variant GBS forms, such as acute motor axonal neuropathy (AMAN, more rapidly evolving and more severe motor deficits, no sensory deficits), acute motor and sensory axonal neuropathy (AMSAN, reported nearly exclusively in adults), Miller-Fisher syndrome (ataxia, ophthalmoplegia, and areflexia without peripheral weakness), pharyngeal-cervical-brachial motor variant (ptosis, facial, pharyngeal, neck flexor muscle weakness), acute pandysautonomia, and acute ophthalmoplegia.^{8,10,11} AMAN is due to axonal damage and is more frequently diagnosed in Asia and South America.¹¹

Clinical onset is characterized by limb pain, limb weakness, and in a few cases ataxia. Physical examination usually shows a preserved mental status or irritability and decreased or abolished deep tendon reflexes in weak limbs.^{7,8} Weakness progresses in a caudo-cranial direction, but there are exceptions to this pattern. Peak weakness is usually reached after seven to ten days, but no later than four weeks. The severity of arm weakness is the most reliable factor to predict respiratory insufficiency.¹¹

The diagnosis is based on clinical findings, and supported by albuminocytologic dissociation in cerebrospinal fluid (CSF), that is, an increased protein level despite normal leukocyte count, a spine magnetic resonance imaging (MRI) showing contrast-enhancement of nerve roots, and/or demyelination or axonal damage findings in electromyography with nerve conduction studies (EMG). Some patients have normal EMG studies in the first two weeks of illness, but later on all patients show abnormal results.⁶

Transverse myelitis

Acute transverse myelitis (ATM) accounts for one fifth of acquired demyelinating events in children; it has an estimated annual incidence in children aged <16 years of 2 per 1,000,000, and its male:female ratio is 1.1–1.6:1.¹² There are two peaks of pediatric incidence, at the age ranges 0–2 years and 5–17 years, with the highest incidence in the former.¹³ In two-thirds of cases, there was a prodromal infection within the past 30 days.

Affected children develop an acute onset of symmetric paraplegia or tetraplegia, decrease or loss of sensation, and sphincter dysfunction, and their clinical course extends over three phases: acute (usually two to

Table 3 Diagnostic criteria for transverse myelitis.**Inclusion criteria**

- Development of sensory, motor, or autonomic dysfunction attributable to the spinal cord
- Bilateral symptoms
- Clearly defined sensory level
- Exclusion of compressive causes by MR imaging or CT myelography
- Spinal cord inflammation demonstrated by cerebrospinal fluid pleocytosis, elevated IgG, or gadolinium enhancement
- Progression to clinical nadir between 4 h and 21 days from onset of symptoms

Exclusion criteria

- History of irradiation to the spine within 10 years
- Clinical findings consistent with anterior spinal artery occlusion
- Abnormal flow voids on the surface of the cord consistent with arteriovenous malformation
- Serologic or clinical evidence of connective tissue disease (sarcoidosis, Behçet disease, Sjögren syndrome, systemic lupus erythematosus, or mixed connective tissue disorder)
- Central nervous system manifestations of syphilis, Lyme disease, HIV, HTLV-1, *Mycoplasma*, or other viral infection
- Brain abnormalities suggestive of multiple sclerosis
- History of clinically apparent optic neuritis

Source: Transverse Myelitis Consortium Working Group. Proposed diagnostic criteria and nosology of acute transverse myelitis.¹⁴

seven days), plateau (1–26 days), and recovery phases (months to years). In some patients, pain is the presenting feature.⁶

ATM is a diagnosis of exclusion; therefore, it is important to carefully consider its differential diagnoses. In this regard, the diagnostic criteria established by the Transverse Myelitis Consortium Working Group may be valuable (Table 3).¹⁴

Children will benefit from a favorable motor outcome, with up to 56% having complete recovery; one study found that the mean time to recover the ability to walk independently was 56 days.⁶

Acute disseminated encephalomyelitis (ADEM)

ADEM is an inflammatory, demyelinating disease that typically occurs within two days to four weeks following a viral infection or, less commonly, vaccination.¹⁵ It presents with multifocal neurologic deficits accompanied by encephalopathy, and its mean age of onset is 5.7 years, with a male:female ratio of 2.3:1.^{15,16}

Clinical features may include fever, headache, vomiting, meningeal signs, visual loss, seizures, cranial nerve palsies, and mental status changes, ranging from lethargy to coma.¹⁵ There is an ongoing controversy on whether ADEM and multiple sclerosis (MS) belong to the same disease spectrum or are completely distinct entities.¹⁶ Although ADEM usually follows a monophasic course, its recurring and multiphasic variants blurs the distinction from MS. Brain MRI may be the most valuable tool to accomplish such distinction, as ADEM cases exhibit large areas of increased signal intensity on T2 and FLAIR-weighted images, with ill-defined borders, distributed bilaterally in the cerebral white matter (WM) and often affecting the basal ganglia, brainstem, and cerebellar and cerebral cortex gray matter, while MS cases usually show

well-defined lesions that are confined to the periventricular WM.¹⁷ Absence of encephalopathy, age above 10 years, presence of optic neuritis, and intrathecal oligoclonal bands during an acute CNS demyelination event increase the risk of MS development.¹⁵

CSF may be normal or may display mild pleocytosis, with or without elevated protein levels.¹⁵

Early and aggressive treatment may attain good recovery with minimal or no deficit in over half the patients.¹⁸

Infectious myelitis

Acute flaccid paralysis can result from spinal cord infection with a number of pathogens, e.g., West Nile virus, nonpolio enteroviruses, dengue virus, syphilis, Lyme disease, human immunodeficiency virus (HIV), cytomegalovirus, Epstein-Barr virus, HTLV-1, and *Mycoplasma*.^{14,19} Its main distinctive feature from transverse myelitis is that the majority of children have focal, poliomyelitis-like spinal cord paralysis with minimal or no sensory symptoms.²⁰

Acute viral myositis

Acute viral myositis manifests as muscle pain and lower-limb weakness, especially in the calves and thighs.²¹ It is most commonly associated with influenza virus infection. Accordingly, its prodromal symptoms include fever, headache, cough, and other respiratory signs. Affected children may refrain from moving their legs secondary to pain, or may indeed have weakness related with rhabdomyolysis.²² Among 35 cases with median age of 7.5 years, muscle weakness lasted one to eight days, and mean serum creatine-kinase was 5507 U/L.²¹

Myasthenia gravis

MG is a relatively rare autoimmune neuromuscular disorder, and its presentation in childhood is divided into transient neonatal MG and juvenile MG. The former is due to transplacental transfer of acetylcholine receptor (AChR) antibodies and usually recovers within two months of life.²³

Clinical presentation is characterized by fatigability and fluctuating weakness of ocular, facial, limb, bulbar, and respiratory muscles. Antibodies against AChR, muscle-specific kinase (MuSK), and lipoprotein receptor-related protein 4 (LRP4) may participate in its pathogenesis.²⁴

A study compared 114 Chinese juvenile MG patients with 207 young adults MG patients. AChR antibodies were found in 77%, 80%, and 81% of the 0–8 years, 8–18 years, and adult age ranges, respectively. Only one out of six patients that tested positive for MuSK and LRP4 antibodies was not an adult. Repetitive nerve stimulation during electromyography (EMG) may be useful for diagnosis, as well as the neostigmine test, but this should be performed only in a controlled and monitored setting, in the presence of staff who are skilled in cardiopulmonary resuscitation. Atropine should be immediately available.²³

Stroke

Stroke may occur in children older than one month as frequently as 13/100,000 per year. Its incidence is higher in neonates (25 to 40/100,000) and is highest among premature infants (up to 100/100,000).²⁵ The underlying mechanisms in pediatric patients include ischemic stroke, sinovenous thrombosis, and hemorrhagic stroke.²⁶ Affected patients usually present with an acute-onset focal neurological deficit, *e.g.*, hemiplegia, hemianesthesia, hemiataxia, unilateral facial palsy, and/or aphasia.²⁷ Newborns may present with seizures.²⁶

Of the children with arterial ischemic stroke, 20–30% will have recurrent strokes; therefore, early diagnosis is paramount.²⁶ Appropriate investigation with neuroimaging should not be delayed.

Alternating hemiplegia of childhood

Alternating hemiplegia of childhood is a rare developmental disorder that is caused, in 75% of cases, by a mutation in the *ATP1A3* gene of neuronal Na⁺/K⁺ ATPase.²⁸ Its onset is before 1.5 years of age and its clinical features consist of episodic unilateral hemiplegia, dystonia, quadriplegia, and abnormal eye movements. Each episode lasts for minutes, hours, or longer, and frequently recurs. Affected children may have developmental delay and epilepsy.²⁸ The calcium channel blocker flunarizine can reduce frequency, severity, and duration of dystonic and hemiplegic spells.²⁸

Periodic paralyses

Periodic paralyses are associated with mutations in the sodium channel gene *SCN4A*, the calcium channel gene

CACNA1S, or the potassium channel gene *KCNJ2*, and should not be confused with secondary causes of episodic paralysis, such as drug toxicity.²⁹ Patients present with episodic attacks of flaccid muscle weakness, typically associated with hypo- or hyperkalemia. Episodes can be triggered by carbohydrate- or potassium-rich foods, or by rest after exercise. Treatment with acetazolamide may decrease the frequency and severity of episodes.²⁹

Brainstem encephalitis

Bickerstaff's brainstem encephalitis (BBE) and Miller-Fisher syndrome form a continuous spectrum, both with ataxia and external ophthalmoplegia, but only those patients with BBE develop impaired consciousness.³⁰ BBE is an uncommon disorder of unknown etiology; however, it is often associated with CNS cell surface antibodies, particularly anti-GQ1b antibodies.³¹ The most common initial symptoms are diplopia and gait disturbance; CSF albuminocytological dissociation is found in half the patients during the second week of illness, and facial or limb weakness may be observed.³⁰

Spinal cord infarction

It is rare in children, and may mimic other common entities, such as ATM. Absence of CSF pleocytosis and a normal protein level help to differentiate between these two entities. It usually involves the anterior spinal artery. Risk factors are minor spinal trauma, parainfectious vasculopathies, and surgery.³² Children present with the typical spinal cord signs, such as a sensory level, bladder and/or bowel dysfunction, as well as paraplegia or tetraplegia.

Functional muscle weakness

Acute weakness may be caused by functional neurological disorder (FND), a condition that was formerly called hysteria and conversion disorder, and children as young as 5 years of age may be affected.³³ In a British study of 204 children, whose ages ranged from 7 to 15 years, the most common presentation was weakness (63%) and abnormal movements (43%), and the most frequent antecedent stressor was bullying at school (81%).³⁴ These authors estimated that the annual incidence of FND in the age range <15 years was 1.30/100,000. A sharp observer will detect a few incongruous findings during physical examination of a patient presenting with weakness due to FND^{6,33,35}:

- monocular diplopia – the child complains of double vision which persists when one eye is closed. Nevertheless, monocular diplopia may also be caused by a refractive error, particularly astigmatism
- the child is unable to walk but can lift his/her legs against gravity when lying on a bed. The rest of the motor examination is normal.

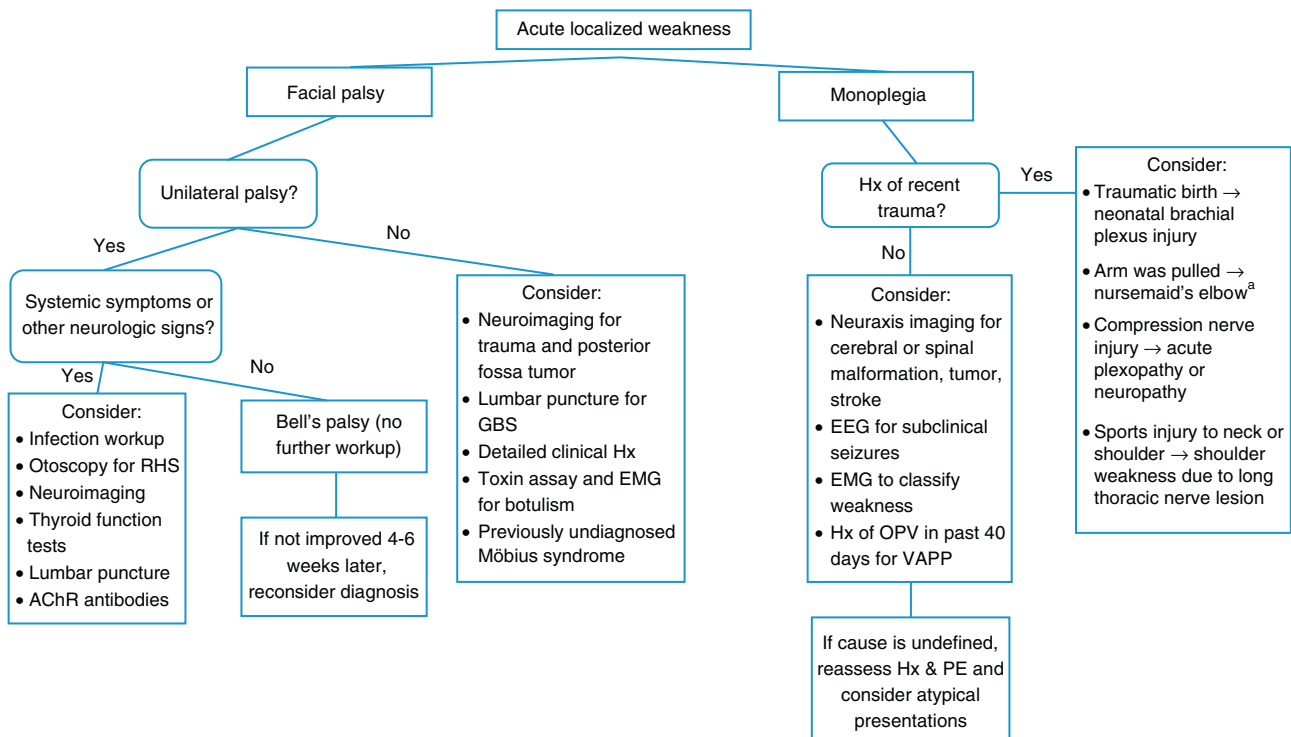


Figure 1 Algorithm for acute localized weakness investigation in the emergency setting.

AChR, acetylcholine receptor; CNS, central nervous system; EEG, electroencephalography; EMG, electromyography; GBS, Guillain-Barré syndrome; Hx, history; OPV, oral polio vaccine; PE, physical examination; RHS, Ramsay-Hunt syndrome; VAPP, vaccine-associated paralytic poliomyelitis. ^aA cause of pseudoparalysis.

- give-way weakness – sudden loss of tone after an initial good/normal strength response when a muscle is tested against resistance
- co-contraction – effortful contraction of one muscle and its agonist, resulting in almost no movement at the joint
- motor inconsistency – significant differences in motor performance under different testing conditions.
- Hoover sign – the examiner places a hand under the heel of the “good” leg and asks the patient to lift the weak leg against resistance. A patient with FND will not exert downward pressure with the “good” leg.

Diagnostic workup

When a pediatric patient presents at the ER with a main complaint of acute motor deficit, it is worthwhile to pay close attention to a few key aspects of history and physical examination (Table 1). Figs. 1 and 2 suggest algorithms for investigating acute localized and diffuse weakness in the ER setting, respectively.

A localized deficit, such as facial palsy (Table 4)³⁶ or monoplegia (Table 5),³ tends to have a smaller list of etiologies, while a more diffuse deficit, e.g., paraplegia,

hemiplegia, or tetraplegia, will require consideration of many etiologies (Table 2). A word of caution is in order, as a thorough physical examination of a patient who complains of monoplegia may reveal inconspicuous weakness of an additional limb, so the patient is actually affected by hemiplegia or paraplegia.³⁷

When a patient presents with acute-onset diffuse weakness, the presence or absence of mental status changes, *i.e.*, encephalopathy, will guide the diagnostic workup. In encephalopathic patients, CNS infection becomes a pressing hypothesis to be addressed by appropriate studies. Other entities need to be considered as well, such as seizures, mass lesions, dysfunction in other organ systems, trauma, and metabolic disturbances.

Great part of the neurologic examination deals with lesion localization, and the authors believe that a general pediatrician working in the ER should master the basic examining skills to ascertain whether an acute motor deficit stems from the brain, brainstem, spinal cord, neuromuscular junction, skeletal muscle, or peripheral nerves.

A large number of tests and procedures are available to investigate an acutely weak patient. As in similar situations, initial priority should be given to rule out life-threatening and treatable conditions. A stepwise, cost-effective, and timely workup is strongly recommended, as outlined in Figs. 1 and 2.

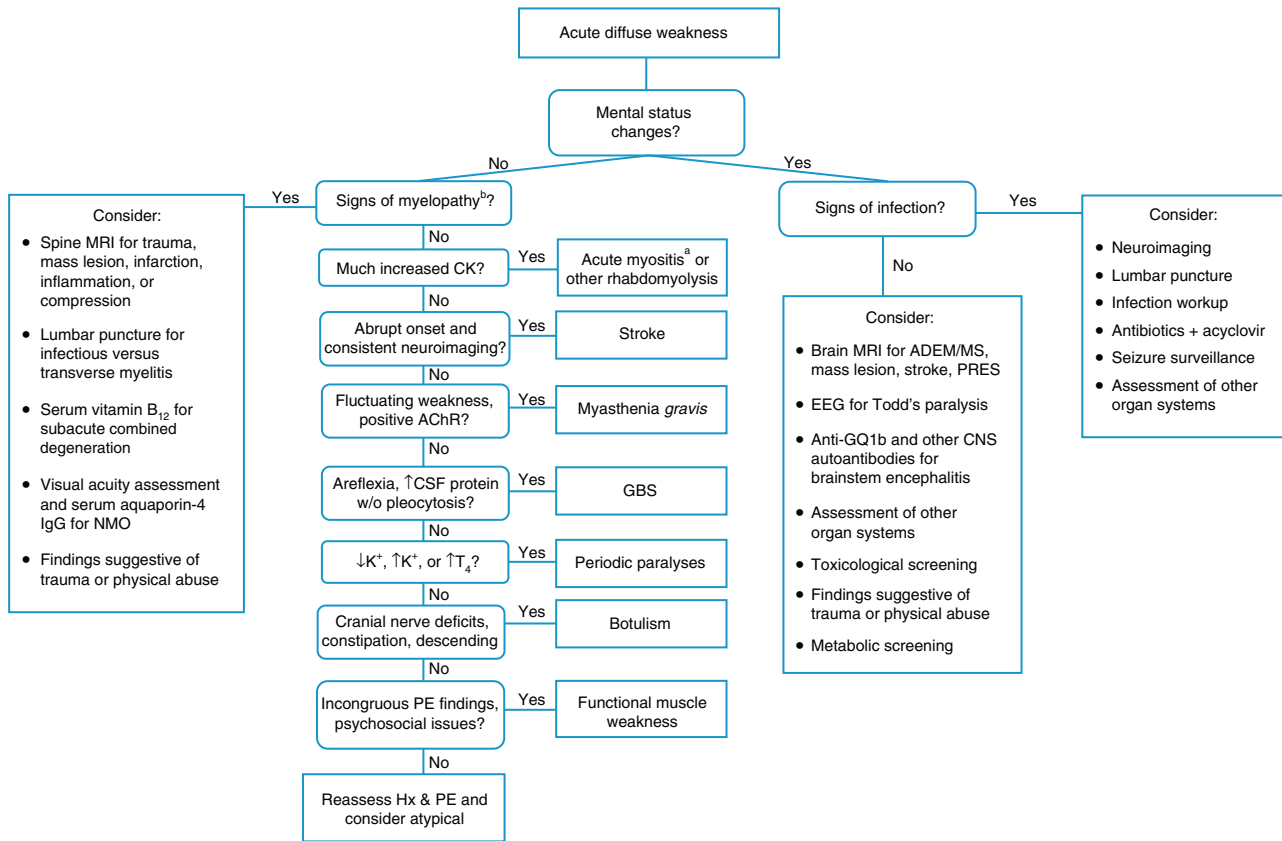


Figure 2 Algorithm for acute diffuse weakness investigation in the emergency setting.

AChR, acetylcholine receptor; CK, serum creatine-kinase; CNS, central nervous system; CSF, cerebrospinal fluid; EEG, electroencephalography; EMG, electromyography; GBS, Guillain-Barré syndrome; Hx, history; IgG, immunoglobulin G; K⁺, serum potassium; MS, multiple sclerosis; NMO, neuromyelitis optica; PE, physical examination; PRES, posterior reversible encephalopathy syndrome; RHS, Ramsay-Hunt syndrome; T₄, thyroxine; w/o, without.

^aA cause of pseudoparalysis.

^bMyelopathy signs include a sensory level, bladder and/or bowel dysfunction, and paraplegia or tetraplegia.

Table 4 Etiologies of facial paralysis.

Congenital	Acquired
Birth trauma	<i>The most common cause</i> Bell's palsy
Congenital bilateral perisylvian syndrome	<i>Other causes</i>
Congenital myasthenia	Acute otitis media
Congenital myotonic dystrophy	Brainstem mass lesion (e.g., pontine glioma)
Facial muscle aplasia	Drugs: interferon, ribavirin
Facioscapulohumeral muscular dystrophy	Facial canal anomalous narrowing
Möbius syndrome	Facial nerve schwannoma
Transient neonatal myasthenia	Hypoparathyroidism
	Hypothyroidism
	Herpes simplex virus infection
	Lyme's disease
	Melkersson-Rosenthal syndrome
	Mumps
	Myasthenia gravis
	Other infections
	Ramsay-Hunt syndrome
	Stroke

Source: Used with permission from Vasconcelos.³⁶

Table 5 Etiologies of monoplegia.

Central nervous system mass lesion, including tumor, hematoma or abscess
Complicated migraine
Epilepsy
Head or spinal trauma
Hereditary brachial neuritis
Hereditary neuropathy with liability to pressure palsy
Neonatal brachial plexus paralysis
Neuropathy
Plexopathy
Stroke
Traumatic peroneal neuropathy
Vaccine-associated paralytic poliomyelitis

Source: Adapted from Fenichel.³

Conclusions

Most patients arriving in the ER with an acute motor deficit will benefit from a practical investigative approach and timely interventions based upon history, physical examination, and a few diagnostic tests, and will be able to eventually recover their well-being and full health.

Conflict of interests

The authors declare no conflicts of interest.

References

- Pope JV, Edlow JA. Avoiding misdiagnosis in patients with neurological emergencies. *Emerg Med Int.* 2012;2012:949275.
- Sanger TD, Chen D, Delgado MR, Gaebler-Spira D, Hallett M, Mink JW. Definition and classification of negative motor signs. *Pediatrics.* 2006;118:2159–67.
- Fenichel GM. Paraplegia and quadriplegia. In: Fenichel GM, editor. *Clinical pediatric neurology: a signs and symptoms approach.* 6th ed. Philadelphia: Saunders Elsevier; 2009. p. 267–83.
- Marx A, Glass JD, Sutter RW. Differential diagnosis of acute flaccid paralysis and its role in poliomyelitis surveillance. *Epidemiol Rev.* 2000;22:298–316.
- Barnes M, Britton PN, Singh-Grewal D. Of war and sausages: a case-directed review of infant botulism. *J Paediatr Child Health.* 2013;49:E232–4.
- Morgan L. The child with acute weakness. *Clin Pediatr Emerg Med.* 2015;16:19–28.
- Ryan MM. Pediatric Guillain-Barré syndrome. *Curr Opin Pediatr.* 2013;25:689–93.
- Devos D, Magot A, Perrier-Boeswillwald J, Fayet G, Leclair-Visonneau L, Ollivier Y, et al. Guillain-Barré syndrome during childhood: particular clinical and electrophysiological features. *Muscle Nerve.* 2013;48:247–51.
- Top KA, Desai S, Moore D, Law BJ, Vaudry W, Halperin SA, et al. Guillain-Barré syndrome after immunization in Canadian children (1996–2012). *Pediatr Infect Dis J.* 2015;34:1411–3.
- Dimachkie MM, Barohn RJ. Guillain-Barré syndrome and variants. *Neurol Clin.* 2013;31:491–510.
- Korinthenberg R. Acute polyradiculoneuritis: Guillain-Barré syndrome. In: Dulac O, Llassonde M, Sarnat HB, editors. *Handb Clin Neurol*, vol. 112. 2013. p. 1157–62.
- Absoud M, Greenberg BM, Lim M, Lotze T, Thomas T, Deiva K. Pediatric transverse myelitis. *Neurology.* 2016;87:546–52.
- Wolf VL, Lupo PJ, Lotze TE. Pediatric acute transverse myelitis overview and differential diagnosis. *J Child Neurol.* 2012;27:1426–36.
- Goh C, Phal PM, Desmond PM. Neuroimaging in acute transverse myelitis. *Neuroimag Clin N Am.* 2011;21:951–73.
- Alper G. Acute disseminated encephalomyelitis. *J Child Neurol.* 2012;27:1408–25.
- Wender M. Acute disseminated encephalomyelitis (ADEM). *J Neuroimmunol.* 2011;231:92–9.
- Tenembaum SN. Pediatric multiple sclerosis distinguishing clinical and MR imaging features. *Neuroimag Clin N Am.* 2017;27:229–50.
- Tenembaum S, Chitnis T, Ness J, Hahn JS. Acute disseminated encephalomyelitis. *Neurology.* 2007;68:523–36.
- Román GC. Tropical myelopathies. *Handb Clin Neurol*, vol. 121; 2014. p. 1521–48.
- Nelson GR, Bonkowsky JL, Doll E, Green M, Hedlund GL, Moore KR, et al. Recognition and management of acute flaccid myelitis in children. *Pediatr Neurol.* 2016;55:17–21.
- Cardin SP, Martin JG, Saad-Magalhães C. Clinical and laboratory description of a series of cases of acute viral myositis. *J Pediatr (Rio J).* 2015;91:442–7.
- Chen CY, Lin YR, Zhao LL, Yang WC, Chang YJ, Wu KH. Clinical spectrum of rhabdomyolysis presented to pediatric emergency department. *BMC Pediatr.* 2013;13:134.
- Liew WK, Kang PB. Update on juvenile myasthenia gravis. *Curr Opin Pediatr.* 2013;25:694–700.
- Hong Y, Skeie GO, Zisimopoulou P, Karagiorgou K, Tzartos SJ, Gao X, et al. Juvenile-onset myasthenia gravis: autoantibody status, clinical characteristics and genetic polymorphisms. *J Neurol.* 2017;264:955–62.
- Rivkin MJ, Bernard TJ, Dowling MM, Amlie-Lefond C. Guidelines for urgent management of stroke in children. *Pediatr Neurol.* 2016;56:8–17.
- Bowers KJ, deVeber GA, Ferriero DM, Roach ES, Vexler ZS, Maria BL. Cerebrovascular disease in children: recent advances in diagnosis and management. *J Child Neurol.* 2011;26:1074–100.
- Bernard TJ, Friedman NR, Stence NV, Jones W, Ichord R, Amlie-Lefond C, et al. Preparing for a ‘‘pediatric stroke alert’’. *Pediatr Neurol.* 2016;56:18–24.
- Masoud M, Prange L, Wuchich J, Hunanyan A, Mikati MA. Diagnosis and treatment of alternating hemiplegia of childhood. *Curr Treat Options Neurol.* 2017;19:8.
- Statland JM, Barohn RJ. Muscle channelopathies: the nondystrophic myotonias and periodic paralyses. *Continuum (Minneapolis).* 2013;19:1598–614.
- Ito M, Kuwabara S, Odaka M, Misawa S, Koga M, Hirata K, et al. Bickerstaff’s brainstem encephalitis and Fisher syndrome form a continuous spectrum: clinical analysis of 581 cases. *J Neurol.* 2008;255:674–82.
- Hacohen Y, Nishimoto Y, Fukami Y, Lang B, Waters P, Lim MJ, et al. Paediatric brainstem encephalitis associated with glial and neuronal autoantibodies. *Dev Med Child Neurol.* 2016;58:836–41.
- Sorte DE, Poretti A, Newsome SD, Boltshauser E, Huisman TA, Izbudak I. Longitudinally extensive myelopathy in children. *Pediatr Radiol.* 2015;45:244–57.
- Stone J, Aybek S. Functional limb weakness and paralysis. *Handb Clin Neurol*, vol. 139; 2016. p. 213–28.

34. Ani C, Reading R, Lynn R, Forlee S, Garralda E. Incidence and 12-month outcome of non-transient childhood conversion disorder in the UK and Ireland. *Br J Psychiatry*. 2013;202: 413–8.
35. Grattan-Smith PJ, Dale RC. Pediatric functional neurologic symptoms. *Handb Clin Neurol*, vol. 139; 2016. p. 489–98.
36. Vasconcelos MM. Acute motor deficit. In: Vasconcelos MM, editor. *GPS pediatrics*. Rio de Janeiro: Guanabara Koogan; 2017. p. 823–8 [in press].
37. Ropper AH, Samuels MA. Motor paralysis. In: Ropper AH, Samuels MA, editors. *Adams and Victor's principles of neurology*. 9th ed. New York: McGraw Hill; 2009. p. 43–60.