

## **Infants choking following blind finger sweep**

**Hasan A. Abder-Rahman\***

### **Abstract**

**Objective:** In stressful situations, people usually use finger sweep to remove pharyngeal foreign bodies from the mouth. This article reports on three cases of death of infants following the use of this technique.

**Method:** A total of 26 cases of choking caused by foreign bodies aspiration in the upper and lower respiratory passages involving children younger than 11 years of age autopsied at the Forensic Department of University of Jordan between 1996 and 2006 were reviewed.

**Results:** Blind finger sweep to remove pharyngeal foreign bodies were reported in three crying infants. All of these cases were younger than 1 year of age and choked on a chickpea, a marble and a short pencil. Diversity, size, shape and smoothness of the surface are the main characteristics that render the foreign bodies less easily caught by fingers and make them easily enter the respiratory passage.

**Conclusion:** These cases showed that blind finger sweep in crying infants is not only dangerous but can be a fatal maneuver.

*J Pediatr (Rio J). 2009;85(3):273-275: Choking, infant, death.*

### **Introduction**

More than 90% of deaths due to foreign body aspiration in children occur in those younger than 5 years old, and most of these cases affect children younger than 1 year of age. Therefore, toys, balloons, small objects and foods may cause foreign body aspiration and account for a significant number of preventable childhood deaths.<sup>1-4</sup>

A foreign body causing obstruction of the larynx is usually removed by coughing, blows to the back, chest thrusts or abdominal compression.<sup>1</sup> Failure of these techniques should lead to attempts to remove the objects using the finger sweep maneuver only when the child is unconscious and the object is visible.<sup>1,5-7</sup> Laypersons, such as concerned parents, may use this technique to remove pharyngeal foreign bodies from the infants' mouth. No studies have reported on the mechanism of death from the use of finger sweep to rescue a child from choking; and only four case

reports have documented harm to the victim's mouth or biting of the rescuer's finger.<sup>6</sup>

Therefore, the objective of this study is to describe the use of finger sweep and its relation to the mechanism of choking among infants and young children based on data on choking fatalities available at the Forensic Department of University of Jordan.

### **Methods**

The study population included all children who died from choking on foreign bodies between 1996 and 2006 and were autopsied at the Forensic Department of University of Jordan. Details of the circumstances of each case were provided by the public prosecutor and close relatives and were used to understand the cause, manner and mode

\* PhD, JMC. Forensic Medicine and Pathology Department, Faculty of Medicine, University of Jordan, Amman, Jordan.

No conflicts of interest declared concerning the publication of this article.

**Suggested citation:** Abder-Rahman HA. Infants choking following blind finger sweep. *J Pediatr (Rio J)*. 2009;85(3):273-275.

Manuscript received Oct 10 2008, accepted for publication Jan 21 2009.

doi: 10.2223/JPED.1892

of death. Data regarding the choking cases included age, gender, child's place of residence, time of the incident, type of foreign body, circumstances of the incident, resuscitation measures, in addition to detailed autopsy data regarding the type, number and anatomical site of foreign body.

## Results

A search of the autopsy reports of cases of choking on foreign bodies that obstructed the respiratory passage revealed 26 cases among children aged  $\leq 11$  years. Sixteen (61.5%) of them were children and infants below 2 years old. Most of the choking victims were males, and the male to female ratio was 1.6:1. Choking on foods occurred in 17 (65.4%) cases, and nine cases (34.6%) occurred due to non-food materials. The choking period in all cases occurred between 10 a.m. and 7 p.m., with 69.2% of the cases occurring between 10 a.m. and 3 p.m. In general, obstructing foods were of a solid consistency, rounded or oval in shape, of moderate size and with smooth skinned surface, such as pieces of edible skinned food and fruit or vegetable seeds. The non-food items were mostly of rubber or plastic materials and had smooth surfaces in addition to a few cases of choking on marble and metallic or plastic pieces.

The collected data were compared with other data sources in order to identify specific behavior causing choking. Clear injury circumstances causing acute episode of choking by finger sweep were reported in three cases. All of these cases involved infants younger than 1 year of age. They constituted (three out of eight) 37.5 % of the cases in this age group. The following is a detailed description of the cases.

### Case no. 1

A 12-month-old male infant put some chickpeas inside his mouth and had a paroxysm of cough. His father slapped the infants back, and he succeeded to eject some chickpeas. However, the baby started to cry, so the father inserted his finger into the infant's mouth and few chickpeas were removed. The condition suddenly became worse and the infant collapsed dead at home. At autopsy, one relatively large chickpea was found inside the lower third of the trachea. The stomach contained semisolid materials with few intact chickpeas.

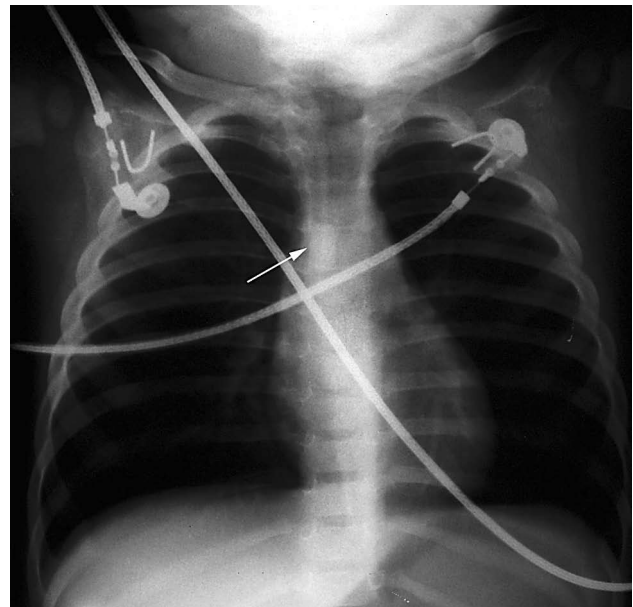
### Case no. 2

A 7-year-old girl was looking after her brother who was only 27 days old. Their mother heard the infant crying so she rushed toward him and saw the girl putting her fingers inside the infant's mouth. He suddenly stopped crying and his body turned blue. He was dead when he arrived at a nearby hospital. Autopsy revealed a normal sized marble (5/8" in diameter) inside the larynx and just above the vocal cords. Multiple erythematous areas and numerous closely

related petechial hemorrhages were seen in the inner part of the cheeks, pharynx and epiglottis.

### Case no. 3

A mother tried to open the mouth of her 11-month-old male infant to remove a small pencil. The child resisted and started to cry loudly. Then he began to choke and had difficulty in breathing. The infant was taken to a nearby pediatric emergency department, where he was found to be cyanotic, irritable, with a palpable pulse of 40 beats/min. Intubation was tried in the emergency room, but attempts failed. Plain X-ray revealed a radio-opaque material inside the trachea (Figure 1). The infant was then taken to the surgery room for urgent tracheostomy, after which he suffered cardiac arrest and was pronounced dead. At autopsy, a 5 cm in length, 7 mm in diameter pencil was found in the subglottic region inside the trachea reaching the tracheal bifurcation, with its tip pointed upwards and the metal-rubber part downwards.



**Figure 1** - Plain X-ray showing radio-opaque part of the pencil inside the trachea

## Discussion

Choking on foreign bodies is an extremely urgent condition. It needs immediate interference by a nearby person.<sup>7,8</sup> Inappropriate behavioral interference is very dangerous because of the relatively high risk of death due to choking.<sup>9</sup>

The occurrence of an alarming sign of choking such as paroxysm of coughing (case no. 1) may lead surprised

and concerned parents to do anything to rescue the infant. Finger sweep is one of the maneuvers used by parents in an automatic natural behavior as a reflex to danger.

Removal of foreign bodies from the mouth of an infant by blind finger sweep is not just a dangerous maneuver as reported elsewhere,<sup>8,10,11</sup> but, according to this study, it can be fatal. The present study highlights the importance of the following factors to the precipitation of death: age of the affected child, level of consciousness, occurrence of crying, and characteristics of the foreign bodies.

All reported cases are younger than 1 year of age. Prevalence of finger sweep in this age group may be due to close supervision of infants by their parents, who can easily notice any sudden change in infants' breathing. Moreover, conscious infants are more prone to interferences and can be overcome more easily than older children because of their relatively weak bodies.

The aspirated objects in these cases were similar to other choking objects reported in the literature.<sup>1-4</sup> They are smooth skinned objects of relatively small size and oval or round shape (cases no. 1 and no. 2). In addition, finger sweep may render any other objects quite dangerous, as seen in case no. 3, where a piece of pencil was pushed deeply into the trachea. The multiplicity of foreign bodies, as seen in case no. 1, adds to the uncertainty of the rescuer about the number of objects inside the mouth. The aforementioned criteria seen in cases no. 1 and no. 2 render aspirated objects less easily caught by fingers and make them easily enter the respiratory passage.

Crying may increase infant's or child's risk of choking on foreign bodies. This may be related to the wide opening of the larynx by crying. Crying in infants younger than 1 year old, as can be assumed based on this study, may be caused by the frightened caregivers' attempt to remove the foreign bodies from the mouth.

Blind finger sweeps in conscious infants has proven to be a dangerous and fatal maneuver. It is difficult to imagine a pencil of 5 cm in length to enter the respiratory passage of an 11-month-old child without it actually being pushed by the sweeping finger. This can be true also for case no. 2 involving a neonate baby. Accordingly, any object can be slipped into the larynx and can be fatal if improper finger sweep is used. This may be facilitated by the infant's uncoordinated movements and crying. We agree with the other authors' recommendation to keep using finger sweep

for objects that can be seen and in unconscious and non-responsive cases only.<sup>1,5,6</sup>

Finally, these cases showed the need of health education in dealing safely with life threatening cases, especially regarding child caregivers.

## References

1. American Heart Association. 2005 American Heart Association (AHA) guidelines for cardiopulmonary resuscitation (CPR) and emergency cardiovascular care (ECC) of pediatric and neonatal patients: pediatric basic life support. *Pediatrics*. 2006;117:e989-1004.
2. Rovin JD, Rodgers BM. Pediatric foreign body aspiration. *Pediatr Rev*. 2000;21:86-90.
3. Enwo ON, Wright M. Sausage asphyxia. *Int J Clin Pract*. 2001;55:723-4.
4. Abdel-Rahman HA. Fatal suffocation by rubber balloons in children: mechanism and prevention. *Forensic Sci Int*. 2000;108:97-105.
5. Australian Resuscitation Council. *Airway: Australian Resuscitation Council Guideline 2006*. *Emerg Med Australas*. 2006;18:325-7.
6. Handley AJ, Koster R, Monsieurs K, Perkins GD, Davies S, Bossaert L; European Resuscitation Council. *European Resuscitation Council guidelines for resuscitation 2005*. Section 2. Adult basic life support and use of automated external defibrillators. *Resuscitation*. 2005;67 Suppl 1:S7-23. Review. Erratum in: *Resuscitation*. 2006;69:351.
7. Vilke GM, Smith AM, Ray LU, Steen PJ, Murrin PA, Chan TC. Airway obstruction in children aged less than 5 years: the prehospital experience. *Prehosp Emerg Care*. 2004;8:196-9.
8. Guidelines 2000 for Cardiopulmonary Resuscitation and Emergency Cardiovascular Care. Part 9: pediatric basic life support. The American Heart Association in collaboration with the International Liaison Committee on Resuscitation. *Circulation*. 2000;102: I253-90.
9. Warda L, Briggs G. Choking & suffocation: CHIRPP Report: March 2005:5-6.
10. International Liaison Committee on Resuscitation. 2005 International Consensus on Cardiopulmonary Resuscitation and Emergency Cardiovascular Care Science with Treatment Recommendations. Part 2: Adult basic life support. *Resuscitation*. 2005;67:187-201.
11. International Liaison Committee on Resuscitation. 2005 International Consensus on Cardiopulmonary Resuscitation and Emergency Cardiovascular Care Science with Treatment Recommendations. Part 6: Adult basic life support. *Resuscitation*. 2005; 67: 271-91.

## Correspondence:

Hasan A. Abder-Rahman  
Forensic Medicine and Pathology Department  
Faculty of Medicine  
University of Jordan, Amman, Jordan -11942  
Tel.: (962) 07.9906.0812  
Fax: (962) 6-535.6746  
E-mail: toxico@ju.edu.jo