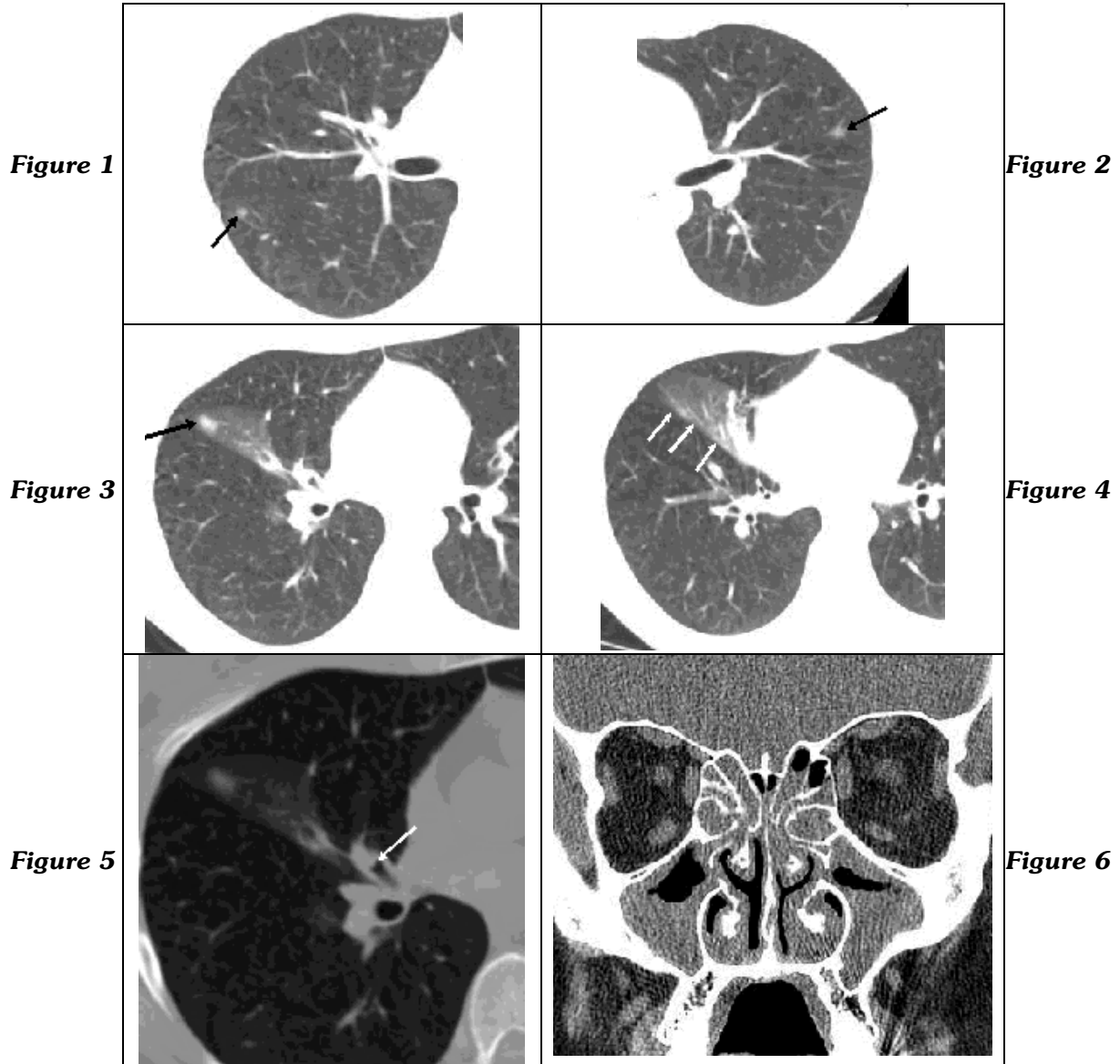


RADIOLOGICAL DIAGNOSIS

The purpose of this section is to stimulate the reasoning from radiological data. We would like the participation of the whole community. Send your diagnostic to the e-mail diagnostico.jpneumo@terra.com.br (do not forget to identify yourself, the right answers will be announced). These are the most important images of the case that may be seen in more detail in jornaldepneumologia.com.br. CHECK THE DIAGNOSIS IN THE NEXT ISSUE.

White female, 30 years-old.
Three years ago presented an episode of feet swelling, which lasted five days.
In the last month, coughing with green catarrh and coryza.



JORGE KAWAKAMA
Radiologist of the Imaging Diagnosis of the
Heart Institute – InCor of the HCFMUSP, São Paulo, SP

NESTOR MÜLLER
St. Paul's Hospital, Vancouver, BC, Canada