

***In vivo* and *in vitro* effects of scorpion venoms in Turkey: a mini-review**

Adiguzel S (1)

(1) Refik Saydam National Public Health Agency, Ankara, Turkey.

ABSTRACT: Scorpion stings constitute a common type of accident in Turkey due to the geographic location, climate and socioeconomic structure of this country. Moreover, envenomation cases are considered a public health problem throughout Turkey. Based on data in the literature, the main clinical features of scorpion envenomations are defined as systemic manifestations including sweating, hypertension and vomiting, and among prominent causes of death are cardiorespiratory manifestations, toxic myocarditis and pulmonary edema. The most important health-threatening scorpions found in Turkey are: *Androctonus crassicauda*, *Leiurus quinquestriatus*, *Mesobuthus gibbosus* and *Mesobuthus eupeus*, all of which belong to the Buthidae family. This study indicates that there is no data related to venom toxicity and *in vivo* effects of other scorpions found in Turkey – such as *Mesobuthus caucasicus*, *Mesobuthus nigrocinctus* and *Hottentotta saulcyi* – and that further research should be performed to determine their health effects.

KEY WORDS: scorpions, venom, envenomation, *in vivo* and *in vitro* effects, Turkey.

CONFLICTS OF INTEREST: There is no conflict.

CORRESPONDENCE TO:

SUHENDAN ADIGUZEL, Refik Saydam National Public Health Agency, Cemal Gürsel Cad. No:18 06100 Sıhhiye, Ankara, Turkey. Phone: +90 312 458 2145. Fax: +90 312 458 2383. Email: suhendan.adiguzel@rshm.gov.tr.

INTRODUCTION

Of an estimated 1,500 distinct scorpion species found worldwide, only 30 types of scorpion venoms have been characterized. Although about 100,000 different polypeptides constituting the venoms of all these species have been estimated, only 0.02% have been defined (1). Scorpion venom contains simple proteins with short neurotoxin and low-molecular-weight polypeptides; it also presents lethal and paralytic effects. The scorpion toxins that affect sodium channels (NaCh) gating in excitable cells are divided into α and β classes. Alpha-toxins have been found in scorpions throughout the world, whereas anti-mammalian β -toxins have been assigned to New World scorpions and anti-insect selective β -toxins (depressant and excitatory) have been described only in the Old World (1-4).

Scorpions can cause serious health problems by stinging humans; most of the time they use their venom to protect themselves. Several studies on scorpion sting cases have emphasized various clinical pictures, ranging from local to serious autonomic and central nervous system symptoms, including death due to cardiac and respiratory failure, especially in children (5). However, scorpions do not harbor any agent capable of causing disease.

In spite of the limitations on epidemiological and clinical data, in this paper we inform about both *in vitro* and *in vivo* effects of scorpionism in Turkey, based on previously conducted studies.

SCORPIONS

Turkey commonly presents scorpions and human envenomation cases due to its geographical location, climate and socioeconomic structure (5, 6). Therefore, important scorpion species threatening the public health in Turkey include *L. quinquestriatus*, *A. crassicauda*, *M. gibbosus*, *M. eupeus*, *M. caucasicus*, *M. nigrocinctus* and *Hottentotta saulcyi* (Figure 1), which belong to the Buthidae family (6-13).




Figure 1. Medically important scorpion species in Turkey. (A) *Hottentotta saulcyi*, (B) *Mesobuthus gibbosus*, (C) *Androctonus crassicauda* and (D) *Leiurus abduallahbayrami*.

On the other hand, *M. caucasicus*, *M. nigrocinctus* and *H. saulcyi* are also part of the Turkish scorpiofauna. Since there are no data about their lethality and envenomation, more epidemiological and clinical studies should be conducted involving their effects on the population's health. Recently, Yağmur *et al.* (14) have described *Leiurus abduallahbayrami*, which had been previously identified as *L. quinquestriatus* in the Turkish scorpiofauna.

Peptides from Anatolian Scorpion Venoms

Androctonus crassicauda

The species *A. crassicauda* from Turkey has been studied for toxin determination, and five toxins were described by Caliskan *et al.* (15), two of which (Acra 1, 6496.8 Da and Acra 2, 7848.6 Da) were lethal to mice (15). Furthermore, Ozkan *et al.* (16) employed high-performance liquid chromatography (HPLC) to obtain the

chromatographic profile of *A. crassicauda* venom and about 25 compounds were separated. Forty-two major components in the venom were within 437 to 44.737 Da according to mass spectrometry (LC-ESI-HRMS) of [MH]⁺ (16).

Mesobuthus gibbosus

Ucar *et al.* (17) analyzed a peptide from *Mesobuthus gibbosus* venom and described two of its five fractions and their lethality on mice and *Musca domestica* larvae by using *in vivo* toxicity tests (fractions 4 and 5).

EFFECTS OF SCORPION VENOM

***In vivo* and *in vitro* effects**

The same species present a range of LD₅₀ values in the lethality test of venoms. Signs and symptoms depend on various factors including genus, species, age, weight, feeding state and structure of the scorpion, as well as the amount of venom injected, the number of stings, the stung site, the patient's susceptibility, the time spent between the sting and the first medical aid, and the climate of the region (18, 19).

Scorpion toxins can change neuronal action potentials and cause the release of neurotransmitters from cholinergic and adrenergic neurons (4, 19-24). Neurotoxins also disrupt synaptic vesicles, leading to the cessation of acetylcholine (ACh) release and to the blockage of neuromuscular transmission (18, 23, 25). In vertebrates, ACh is the major transmitter at neuromuscular junctions, autonomic ganglia, parasympathetic effector junctions, sympathetic effector junctions, and at many sites in the central nervous system. It is released by motor nerve cells and once attached to its receptors on muscle fibers, stimulates the fibers to contract. The glands that receive impulses from the parasympathetic part of the autonomic nervous system are stimulated in the same way (18, 21).

Scorpion venom stimulates neuronal sodium channels, resulting thus in autonomic storm. Stimulation of both branches of the autonomic system leads to sweating, salivation, vomiting, fasciculation, hypotension, hypertension, bradycardia or tachycardia, ventricular premature contraction, cool extremities, pulmonary edema, shock, and priapism in men. The majority of envenomation symptoms are due to a massive release of catecholamines, which play an important role in the pathogenesis of scorpion sting; they are released from the adrenal glands and postganglionic nerve

endings and act either on β -adrenergic receptors, increasing the peripheral resistance, or on α -adrenergic receptors, increasing the cardiac contractility or causing renin release from the kidneys. Pulmonary edema, as a result of scorpion envenomation, is due to myocardial dysfunction. Bradykinin-induced secretory pulmonary edema is secondary and results of kallikrein stimulation due to the tissue damage caused by anoxia and accumulation of oxygen free radicals when cardiogenic manifestations are not managed early enough with prazosin, which enhances insulin secretion by blocking α -receptors on β cells in the pancreas. Hyperkalemia and hyperglycemia are other symptoms which may occur as a consequence of the autonomic storm in the victim (19, 21, 22, 25-27).

Rats experimentally envenomed with *A. crassicauda* venom developed acute renal failure, liver dysfunction and cell destruction. *Androctonus crassicauda* venom showed its toxicity by altering the electrolyte balance, especially sodium and chlorine ion levels in the serum, rather than by inhibiting AchE activity (28).

Sahin *et al.* (29) emphasized that the levels of aspartate aminotransferase, gamma-glutamyl transpeptidase, malondialdehyde, reduced glutathione and blood urea nitrogen notably increased in rats after experimental envenomation with *M. eupeus* venom in a province of eastern Turkey.

Mice experimentally envenomed with *M. gibbosus* venom manifested tremor, hypersalivation, mouth and nose bleeding, paralysis and death (30). Ucar and Tas (31) indicated that *M. gibbosus* scorpion venom contains peptides with specific cholinesterase inhibitory activities, which may be responsible for some of the neurotoxic effects of the venom on animals and humans. However, those authors also demonstrated that *M. gibbosus* venom has a peptide showing specific MAO-A inhibitory activity, which may be responsible for the anxiogenic effects of the scorpion venoms (31).

Epidemiological and Clinical Data on Scorpionism in Turkey

There are only a few epidemiological and clinical records of case reports involving *Mesobuthus eupeus* and *Androctonus crassicauda*, as well as scorpionism in children in the western and southeastern parts of Turkey (5, 32-37).

Epidemiological aspect

In Turkey, epidemiological studies have shown that most scorpion stings affect females. The highest incidence of scorpion stings was recorded for the warmest months of the year since scorpions become more active in the warm season. Scorpion sting was mostly seen in extremities, especially upper limbs. Such a high ratio of scorpion sting in extremities is due to the country's socioeconomic structure, which depends on agriculture in rural areas, where people wear sandals or walk barefoot (especially children), put on shoes without pre-shaking them, hand search for scorpions in their homes, lift up stones in a non-controlled manner and move their hands during sleep or rest to get away of scorpions. Stings in the head, neck and other body sites mostly occur at sleep because bed mattresses are not checked and sleeping clothes are put on without checking (5, 32, 33, 35, 37).

Clinical aspect

Based on recent data in the literature on scorpionism and its clinical aspects in Turkey, envenomation has been characterized by local and systemic symptoms. Such effects could be related to the scorpion species and its feeding state; the venom structure and amount; the number of stings; sensitivity, age and weight of the patient; the time of admission to the hospital; and the climate of the region (20, 22, 38).

The local symptoms most commonly reported included local pain, edema, hyperemia, swelling, burning, numbness and itching, whereas systemic symptoms consisted of dry mouth, thirst, sweating, hypotension, hypertension, cramps, tremor, nausea, vomiting, breathing difficulty, tachycardia, sialorrhea, restlessness, hemolytic-uremic syndrome, cyanosis, cardiac failure and/or acute pulmonary edema, and death (33-37, 39-42). In a study carried out in 2005, a total of 24,261 cases of scorpion sting were reported (42). As shown in Figure 2, scorpion envenomation is an important health problem in all regions of Turkey.

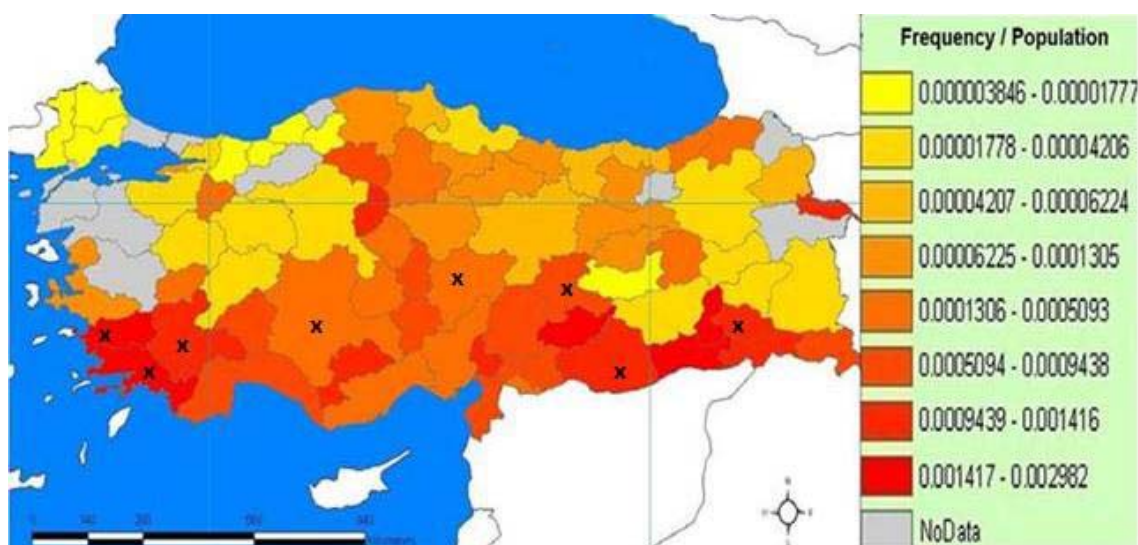


Figure 2. Overall annual incidence is about 36 scorpion stings per 100,000 inhabitants and the estimated annual mortality is 0.01 death per 100,000 inhabitants (42).

X: Location of previously designed studies or case reports.

Envenomation by *Androctonus crassicauda*

Venoms from species of the *Androctonus* genus are highly toxic (10). *Androctonus crassicauda* venom has a 0.32 mg/kg LD₅₀ (dose killing 50% of animals) when intravenously injected into mice, which makes this scorpion species one of the most toxic in the world (21, 43). In addition, *Androctonus crassicauda* venom can specifically stimulate acetylcholine receptors throughout the body; therefore, it can be considered neurotoxic. Similarly to the venoms of other scorpion species from different parts of the world, *A. crassicauda* venom can directly increase ACh concentration (18, 20, 44, 45). Radmanesh (20) noticed adrenergic signs, pain and no clinical symptoms using low concentrations of this venom, which cannot reach a threshold to stimulate ACh receptors. On the other hand, cholinergic signs only occur when high venom concentrations are used. Most symptoms are caused either by the release of catecholamines from adrenal glands (sympathetic nerves) or by the release of acetylcholine from postganglionic parasympathetic neurons (18, 20, 44, 45).

Soker and Haspolat (32) reported 64 cases of scorpion sting in children admitted to the Pediatric Emergency Department in Dicle University Hospital at Diyarbakir from the provinces of Mardin, Sirnak, Batman and Siirt in the southeastern part of Turkey from 1995 to 1999. Those authors also recorded eight lethal cases (12.5%) which

were due to cardiac and respiratory failure during the first 24 hours of hospitalization. Ozkan *et al.* (35) noticed that, in *A. crassicauda* toxicity cases, the patients had parasympathetic and local failures, which are characterized by pain, hyperemia and edema. Bosnak *et al.* (37) stated that pulmonary edema developed in 9.6% and dyspnea in 23.0% of the victims; the predominant signs of cardiovascular system compromising were tachycardia (36.5%), dyspnea (23.0%), paleness (15.3%), hypertension (7.6%) and hypotension (3.8%), and manifestations of cholinergic stimulation, including excessive sweating (32.6%) and vomiting (3.8%), were seen after scorpion sting in children in southeast Turkey. In addition, Al *et al.* (39) reported 120 cases of scorpion envenomation in Batman province.

The most common symptoms observed for these cases were local pain (97.5%), red mark/redness (65%), tenderness (40%), numbness (51.7%), edema (25.8%) and sweating (16.7%), which were determined as systemic effects. In those investigations, cardiac dysfunction, myocardial damage and death were not recorded as secondary symptoms to the major systemic envenomations. However, Ozkan *et al.* (35) observed systemic effects in 17.7% cases of *A. crassicauda* envenomation. Moreover, parasympathetic effects were more common than sympathetic effects and no deaths were reported. This species plays a major role in 50.8% of scorpionism cases in Sanliurfa province in Turkey (35). On the other hand, Adiguzel *et al.* (5) stated that child patients presented signs of local and autonomic nervous system failures, but no lethality.

Envenomation by *Mesobuthus* sp.

In Turkey, stings by *Mesobuthus* species are more frequent than those by other scorpion species since one of their most common habitats is from the west to the east of Anatolia (46, 42). *Mesobuthus gibbosus* is generally seen from the Aegean region of Central Anatolia to the middle parts of East Anatolia (6, 8, 9).

Suzek *et al.* (47) stated that 262 patients stung by scorpions (*M. gibbosus*) required the Emergency Service of the State Hospital in Mugla province between 1999 and 2001. Those authors also reported that two cases (1.17%) resulted in death in 1999. Akcay *et al.* (48) investigated envenomation cases in Denizli including the previous five years and reported that 1.5% of these cases were scorpionisms. Altinkaynak *et al.* (33) investigated 24 children stung by scorpions in Marmaris, district of Mugla province, and stated that the patients had clinical symptoms such as abdominal pain,

muscle contractions, nausea, hypertension, hypotension, bradycardia, dyspnea, pulmonary edema, convulsion, and shock; they also reported 8.3% lethality due to cardiac and respiratory failure. Dayar *et al.* (41) presented a case of a five-year-old girl who was stung by a scorpion and admitted to the hospital with generalized muscle contraction, pulmonary edema, tachypnea, serious arrhythmia, tachycardia, abnormal electrocardiography findings and increased cardiac enzymes. Those authors reported that the patient died due to myocardial ischemia. In one of their clinical studies carried out in Central Anatolia, Kekec *et al.* (49) recorded that scorpion stings were the most common cases (43%) in all animal-originated envenomation cases reported to the Medical School Department of the Emergency Service, Erciyes University of Kayseri, between January and December 1999. Karakurt and Kocak (36) reported two cases of children who developed myocarditis and pulmonary edema after scorpion stings. Mocan *et al.* (50) presented a case of a 28-year-old man admitted to the Faculty of Medicine, Black Sea Technical University, with a history of pain in the right leg, vomiting, diarrhea, agitation, restlessness, blurred vision, peripheral cyanosis, increased lacrimation, salivation and oliguria following a scorpion sting which had occurred two days before. Thus, those authors suggested that scorpion stings should be added to the ever-growing list of causes of hemolytic-uremic syndrome.

M. eupeus is widely spread from central to eastern Anatolia, Turkey (9). Ozkan and Kat (34) showed that 25.8% of all cases of scorpion stings were caused by *M. eupeus* in Sanliurfa province, Turkey. In a clinical study involving cases of *M. eupeus* toxicity, patients had local (severe pain, hyperemia and edema) and systemic effects (dry mouth, thirst, sweating, nausea, hypotension, hypertension, increased bronchial secretion, breathing difficulty, tachycardia and cyanosis) but no death occurred (34). Scorpion stings also lead to electrocardiographic abnormalities. The most common changes have included ST changes, sinus tachycardia, atrial ectopic beat, bradycardia, and ventricular ectopic beat (36, 40, 41, 49, 51, 52).

Analysis of data in the literature indicates that the main clinical features of scorpion envenomation are systemic manifestations including sweating, hypertension, vomiting and cardiorespiratory manifestations, whereas toxic myocarditis and pulmonary edema are the predominant causes of death. Although scorpion sting is a public health problem in Turkey, there are still doubts about the treatment for the clinical manifestations of scorpion envenomation. Important health-threatening

scorpions in Turkey are *Androctonus crassicauda*, *Leiurus quinquestriatus* (recently described as *L. abduallahbayrami*), *Mesobuthus gibbosus* and *M. eupeus*, all of which belong to the Buthidae family. The toxicity and the *in vivo* effects of *M. caucasicus*, *M. nigrocinctus* and *H. saulcyi* venoms should be determined experimentally since there are no data related to their health effects in Turkey.

REFERENCES

1. Possani LD, Becerril B, Delepierre M, Tytgat J. Scorpion toxins specific for Na⁺-channels. Review article. Eur J Biochem. 1999;264(2):287-300.
2. Possani LD, Merino E, Corona M, Bolivar F, Becerril B. Peptides and genes coding for scorpion toxins that affect ion-channels. Biochimie. 2000;82(9-10):861-8.
3. Martin-Eauclaire MF, Ceard B, Bosmans F, Rosso JP, Tytgat J, Bougis PE. New "Birtoxin analogs" from *Androctonus australis* venom. Biochem Biophys Res Commun. 2005;333(2):524-30.
4. Gordon D, Ilan N, Zilberberg N, Gilles N, Urbach D, Cohen L, et al. An 'Old World' scorpion beta-toxin that recognizes both insect and mammalian sodium channels. Eur J Biochem. 2003;270(12):2663-70.
5. Adiguzel S, Ozkan O, Inceoglu B. Epidemiological and clinical characteristics of scorpionism in children in Sanliurfa, Turkey. Toxicon. 2007;49(6):875-80.
6. Ozkan O, Karaer Z. The scorpions in Turkey. Turk Bull Hyg Exp Biol. 2003;60(1):55-62.
7. Fet V, Braunwalder ME. The scorpions (Arachnida: Scorpiones) of the Aegean area: current problems in taxonomy and biogeography. Belg J Zool. 2000; 130(1):15-20.
8. Demirsoy A, Durmus Y, Akbulut A. Türkiye scorpiones (akrep) faunasinin sistematik ve biyolojik yönden incelenmesi. Proje No: 1998 K 1001 40. Ankara: Çevre Bakanligi Çevre Koruma Genel Müdürlüğü Hayvanlar1 Koruma Dairesi Baskanligi; 2001.
9. Karatas A, Karatas A. *Mesobuthus eupeus* (C.L. Koch, 1839) (Scorpiones: Buthidae) in Turkey. Euscorpius. 2003;7(1):1-6.
10. Ozkan O, Filazi A. The determination of acute lethal dose-50 (LD50) levels of venom in mice, obtained by different methods from scorpions, *Androctonus crassicauda* (Olivier 1807). Acta Parasitol Turcica. 2004;28(1):50-3.

11. Karatas A. *Mesobuthus caucasicus* (Nordmann, 1840) (Scorpiones: Buthidae) in Turkey. *Euscorpius*. 2005;25(1):1-9.
12. Karatas A, Gharkheloo MM. A contribution to the knowledge of *Hottentotta saulcyi* (Simon, 1880) (Scorpiones: Buthidae). *Zool Middle East*. 2006;38(1): 85-92.
13. Yağmur EA, Koç H, Yalçın M. Distribution of *Hottentotta saulcyi* (Simon, 1880) (Scorpiones: Buthidae) in Turkey. *Euscorpius*. 2008;76(1):1-8.
14. Yağmur EA, Koc H, Kunt KB. Description of a new species of *Leiurus* Ehrenberg, 1828 (Scorpiones: Buthidae) from southeastern Turkey. *Euscorpius*. 2009;85(1):1-20.
15. Caliskan F, García BI, Coronas FI, Batista CV, Zamudio FZ, Possani LD. Characterization of venom components from the scorpion *Androctonus crassicauda* of Turkey: peptides and genes. *Toxicon*. 2006;48(1):12-22.
16. Ozkan O, Adiguzel S, Inceoglu B, Lango J, Ertek M, Hammock BD. Evaluation of the neutralizing capacity of *Androctonus crassicauda* (Olivier, 1807) antivenom against *Leiurus quinquestriatus* (Ehrenberg, 1928) venom (Scorpiones: Buthidae). *J Venom Anim Toxins incl Trop Dis*. 2008;14(3):481-96.
17. Ucar G, Tas C, Tumer A. Monoamine oxidase inhibitory activities of the scorpion *Mesobuthus gibbosus* (Buthidae) venom peptides. *Toxicon*. 2005; 45(1):43-52.
18. Altinkurt O, Altan M. Pharmacological effects of the scorpion (*Androctonus crassicauda*) venom from Urfa environment on laboratory animals and the antagonistic effects of streptomycin to most of these effects. *J Fac Pharmacol Ankara*. 1980;10(1):41-61.
19. Dittrich K, Ahmed R, Ahmed QA. Cardiac arrest following scorpion envenomation. *Ann Saudi Med*. 2002;22(1-2):87-90.
20. Radmanesh M. *Androctonus crassicauda* sting and its clinical study in Iran. *J Trop Med Hyg*. 1990;93(5):323-6.
21. Ismail M, Abd-Elsalam MA, Al-Ahaidib MS. *Androctonus crassicauda* (Olivier), a dangerous and unduly neglected scorpion-I. Pharmacological and clinical studies. *Toxicon*. 1994;32(12):1599-618.
22. Karnad D. Hemodynamic patterns in patients with scorpion envenomation. *Heart*. 1998;79(6):485-9.
23. Gwee MC, Nirthan S, Khoo HE, Gopalakrishnakone P, Kini RM, Cheah LS. Autonomic effects of some scorpion venoms and toxins. *Clin Exp Pharmacol Physiol*. 2002;29(9):795-801.

24. Reeves JJ. Scorpion envenomation. Clin Toxicol Rev. 1998;20(1):1-6.
25. Isbister GK, Graudins A, White J, Warrell D. Antivenom treatment in arachnidism. J Toxicol Clin Toxicol. 2003;41(3):291-300.
26. Deshpande SB, Alex AB. On the management of scorpion stings. Heart. 2000; 83(1):585.
27. El Amin EO. The clinical management of scorpion stings in children. Qatar Med J. 2003;12(1).
28. Ozkan O, Adiguzel S, Kar S, Kurt M, Yakistiran S, Cesaretli Y, et al. Effects of *Androctonus crassicauda* (Olivier, 1807) (Scorpiones: Buthidae) venom on rats: correlation among acetylcholinesterase activities and electrolytes levels. J Venom Anim Toxins incl Trop Dis. 2007;13(1):69-81.
29. Sahin A, Ozbek H, Dulger H, Ozturk G, Dagoglu G. Effects of scorpion envenomation on blood constituents in rats. Indian Vet J. 2004;81(5):519-20.
30. Ozkan N. *Mesobuthus gibbosus* türü akrep zehirinin farelerde minimal lethal dozunun(MLD50) saptanması E.Ü Sağlık Bilimleri Enst. İzmir: Parazitoloji Anabilimdalı Yüksek Lisans Tezi; 1992.
31. Ucar G, Tas C. Cholinesterase inhibitory activities of the scorpion *Mesobuthus gibbosus* (Buthidae) venom peptides. FABAD J Pharm Sci. 2003;28(1):61-70.
32. Soker M, Haspolat K. Güneydogu ve anadolu bölgesinde çocuklarda akrep sokması: 64-vakanin değerlendirilmesi. Çocuk Sağlığı ve Hastalıkları Dergisi. 2000;43(1):43-50.
33. Altinkaynak S, Ertekin V, Alp H. Scorpion envenomation in children. Turk Arch Ped. 2002;37(1):48-54.
34. Ozkan O, Kat I. *Mesobuthus eupeus* scorpionism in Sanliurfa region of Turkey. J Venom Anim Toxins incl Trop Dis. 2005;11(4):479-91.
35. Ozkan O, Adiguzel S, Yakistiran S, Cesaretli Y, Orman M, Karaer KZ. *Androctonus crassicauda* (Olivier 1807) scorpionism in the Sanliurfa provinces of Turkey. Acta Parasitol Turcica. 2006;30(3):239-45.
36. Karakurt C, Kocak G. Toxic myocarditis after scorpion envenomation: case report. J. Inonu Univ Med Fac. 2007;14(1):61-3.
37. Bosnak M, Ece A, Yolbas I, Bosnak V, Kaplan M, Gurkan F. Scorpion sting envenomation in children in southeast Turkey. Wilderness Environ Med. 2009;20(2):118-24.

38. Hammoudi-Triki D, Ferquel E, Robbe-Vincent A, Bon C, Choumet V, Laraba-Djebari F. Epidemiological data, clinical admission gradation and biological quantification by ELISA of scorpion envenomations in Algeria: effect of immunotherapy. *Trans Roy Soc Trop Med Hyg.* 2004;98(4):240-50.
39. Al B, Yılmaz DA, Soğut O, Orak M, Üstündağ M, Bokurt S. Epidemiological, clinical characteristics and outcome of scorpion envenomation in Batman, Turkey: an analysis of 120 cases. *JAEM.* 2009;8(3):9-14.
40. Pirgon O, Sert A, Atabek ME, Tokgöz H. The follow-up by cardiac troponin I of cardiac involvement in a case with scorpion envenoming. *Selçuk Tıp Derg.* 2005;21(3):88-90.
41. Dayar E, Görsel G, Dursun O, Kardelen F, Uguz A. Akrep sokması sonrası ciddi aritmi ve miyokard iskemisi: Olgu sunumu (Poster presentation). 50. Milli Pediatri Kongresi. 2006, 8–12 Kasım. World of Wonders / Kremlin Palace, Aksu, Antalya. Available from <http://www.millipediatri.org.tr/bildiriler/PP-415.htm>.
42. Ozkan O, Uzun R, Adigüzel S, Cesaretli Y, Ertek M. Evaluation of scorpion sting incidence in Turkey. *J Venom Anim Toxins incl Trop Dis.* 2008;14(1):128-40.
43. Bonnet MS. Toxicology of *Androctonus* scorpion. *Br Hom J.* 1997;86(3):142-51.
44. Ay I, Tuncer M, Onur R. Effects of *Androctonus crassicauda* scorpion venom on endothelium-dependent and independent vascular responses of rabbit aorta. *Gen Pharmacol.* 1996;27(3):519-23.
45. Vatanpour H. Effects of black scorpion *Androctonus crassicauda* venom on striated muscle preparation *in vitro*. *Iranian J Pharm Res.* 2003;2(1):17-22.
46. Ozkan O, Adiguzel S, Yakıstıran S, Kar S, Cesaretli Y, Karaer KZ. Determination of potency and paraspecific effects of *Androctonus crassicauda* (Olivier, 1807) antivenom against *Mesobuthus gibbosus* (Brullé, 1832) venom (Scorpiones: 47. Buthidae). *J Venom Anim Toxins incl Trop Dis.* 2007;13(2):500-8.
47. Suzek H, Evren H, Yapar S. Muğla Devlet Hastanesi acil servisine başvuran akrep ve yılan sokma vakalarının incelenmesi. *Uluslararası İnsan Bilimleri Dergisi.* 2004;1(1):1-4.
48. Akçay A, Gurses D, Özdemir A, Kılıç I, Ergin H. The childhood poisoning in Denizli. *J Adnan Menderes Univ Med Fac.* 2005;6(1):15-9.
49. Kekec Z, Avsarogulları L, İkizceli I, Kurtoglu S, Sozuer E. Analysis of the patients who applied to Erciyes University Medical School Department the Emergency Medicine due to animal poisoning. *Turk J Emerg Med.* 2003;3(1):45-8.

50. Mocan H, Mocan M, Kaynar K. Haemolytic-uraemic syndrome following a scorpion sting. *Nephrol Dial Transplantation.* 1998;13(10):2639-40.
51. Yıldızdas D, Yılmaz HL, Erdem S. Treatment of cardiogenic pulmonary oedema by helmet-delivered non-invasive pressure support ventilation in children with scorpion sting envenomation. *Ann Acad Med Singapore.* 2008;37(3);230-3.
52. Al B, Sucu M, Cavdar M, Yılmaz DA, Yıldırım C, Davutoglu V. Electrocardiographic abnormalities in patients bitten by scorpions. *JAEM.* 2009;8(3):51-5. (DOI:10.4170/JAEM. 2009.86158.)