

Endovascular treatment of erectile dysfunction by traumatic arteriospongious fistula: case report

Tratamento endovascular da disfunção erétil por fistula arterioesponjosa traumática: relato de caso

Fábio Augusto Cypreste Oliveira¹, Carlos Eduardo de Sousa Amorelli¹, Fábio Lemos Campedelli¹, Hugo Walter Frota Filho², Juliana Caetano Barreto³, Fernanda Lauer Sampaio Meirelles³, Mariana Caetano Barreto⁴, Philippe Moreira da Silva⁵

Abstract

Erectile dysfunction (ED) is a common multifactorial disorder. The authors report a case of perineal trauma, evolving with ED for bulbar penile artery fistula to the spongy body, promoting an arteriovenous shunt and culminating with erectile deficit, penile congestion and pain. Patient underwent an endovascular embolization and is now at the 6th month of ambulatorial follow-up. He returns to sexual activities, without complaints of penile rigidity and pain.

Keywords: erectile dysfunction (ED); fistula; therapeutic embolization.

Resumo

A disfunção erétil (DE) representa um distúrbio comum de caráter multifatorial. Os autores relatam um caso de paciente vítima de trauma perineal evoluindo com DE por fistula da artéria bulbar para o corpo esponjoso peniano, promovendo um *shunt* arteriovenoso culminando com déficit de ereção, congestão peniana e dor. O mesmo foi submetido ao tratamento endovascular por embolização com sucesso e encontra-se no sexto mês de acompanhamento ambulatorial, com retorno às suas atividades sexuais e sem queixas de rigidez peniana e dor.

Palavras-chave: disfunção erétil (DE); fistula; embolização terapêutica.

Introduction

Erectile dysfunction (ED) is defined as a persistent failure to initiate and sufficiently maintain an erection for a satisfactory sexual performance. It has multiple pathophysiology and etiology, making it a complex disorder and of difficult clinical management.

The prevalence of ED in general population varies between 22 and 52%¹⁻³, with a different distribution among age groups. ED has a proportionally greater predominance in older men⁴, becoming a common entity that can adversely affect interpersonal relationships and quality of life of men and women.

Vasculogenic erectile dysfunction presents itself as one of the main representatives of this scenario, with well-defined risk factors, such as hypertension, dyslipidemia, obesity, smoking and cardiovascular disease^{5,6}. It may be caused by the obstruction of arterial blood flow due to venous incompetence (varicocele) or obstruction of the venous system (veno-occlusive disease).

Penile arteriovenous fistulas have trauma as its main etiology and represent a rare cause of erectile dysfunction. The spongy body, which surrounds the urethra, is irrigated by the bulbar artery, which is not directly related to the process of erection but to penile tumescence. In cases of arteriospongious fistula, an arteriovenous shunt occurs

Study carried out at the Serviço de Angiologia, Cirurgia Vascular, Endovascular e Laserterapia. Hospital São Francisco de Assis – Goiânia (GO), Brazil.

¹ Especialista em Cirurgia Vascular na área de Angiorradiologia e Cirurgia Endovascular pela Sociedade Brasileira de Angiologia e Cirurgia Vascular (SBACV), Colégio Brasileiro de Radiologia (CBR) e Associação Médica Brasileira (AMB). – Goiânia (GO) Brazil.

² Médico Cirurgião Geral e Diretor do Hospital São Francisco de Assis. – Goiânia (GO) Brazil.

³ Médica Clínica Geral. Instituição (SIGLA) – Goiânia (GO) Brazil.

⁴ Médica Cirurgiã Geral do Hospital de Urgências de Goiânia (HUGO) – Goiânia (GO), Brazil.

⁵ Técnico de Enfermagem e Instrumentador da Angiodyn. – Goiânia (GO) Brazil.

Financial support: None.

Conflict of interest: Nothing to declare.

Submitted on: 18.01.2012. Accepted on: 12.07.2012.

J Vasc Bras. 2012;11(4):317-319.

directly to the spongy body, so the input arterial blood flow is equal to the output venous blood flow, with maintenance of penile tumescence, manifested by pain and erectile deficit. In cases of traumatic arteriocavernous fistula, the erectile dysfunction occurs mostly in the form of high-flow priapism, which may require embolization of the fistula for its resolution.

Case report

Case 1

Male patient, 56 years old, a rural worker, presenting erectile dysfunction and painful maintenance of penile semi-rigidity about 2 months after perineal blunt trauma. No comorbidities and previous surgeries.

He underwent urologic evaluation, with physical examination showing maintenance of penile tumescence, but without characterizing priapism. The remainder of physical, urological and vascular examination was normal. Among complementary exams, he had a negative urine culture, prostatic ultrasound within the standard of normality, penile Doppler ultrasound showing no detectable changes, and pelvic arteriography showing arteriospongious fistula. The patient was referred to specific treatment.

A pelvic and selective arteriography confirmed the diagnosis of bulbar artery fistula to the spongy body with arterial blood supply only to the right side (Figure 1). Under local anesthesia and sedation, we performed superselective catheterism using Echelon14[®] microcatheter (ev3, MA, USA) in coaxial system and embolization using controlled-release microcoils of 2 mm × 2 cm Micrus[®] (MicrusEndovascular Corporation. CA/EUA), with complete occlusion of the anomalous communication, without complications (Figure 2). Patient had an uneventful postoperative, with significant improvement in penile tumescence and pain, and was discharged after 12 hours of hospitalization, without specific medication.

He is now at the 6th month of ambulatorial follow-up, presenting remission of penile tumescence and pain. Penile Doppler ultrasound in the 1st, 3rd and 6th month postoperatively showed no changes. He returned to sexual activities after 30 days postoperatively, without complaints.

Discussion

Perineal trauma may be related to erectile dysfunction due to penile fracture sequel, prolonged priapism sequel or

presence of bulbospongious fistula. In cases of prolonged priapism, dysfunction may be ischemic or nonischemic. The ischemic form is most commonly associated with veno-occlusive disease, with a deficit of venous drainage, and its treatment includes pharmacotherapy, needle aspiration, proximal shunt or distal shunt. In nonischemic cases, arteriocavernous fistula represents its main etiology,

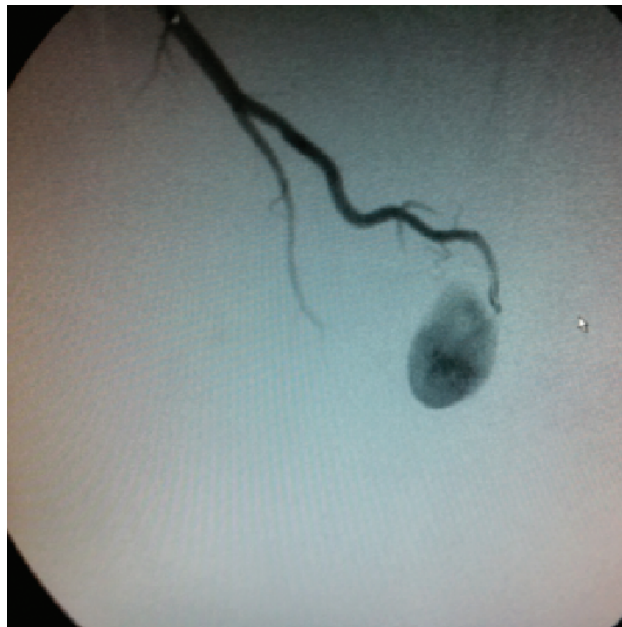


Figure 1. Selective arteriography with catheterization of the right internal pudendal artery, confirming the diagnosis of right bulbar artery fistula to the penile spongy body.

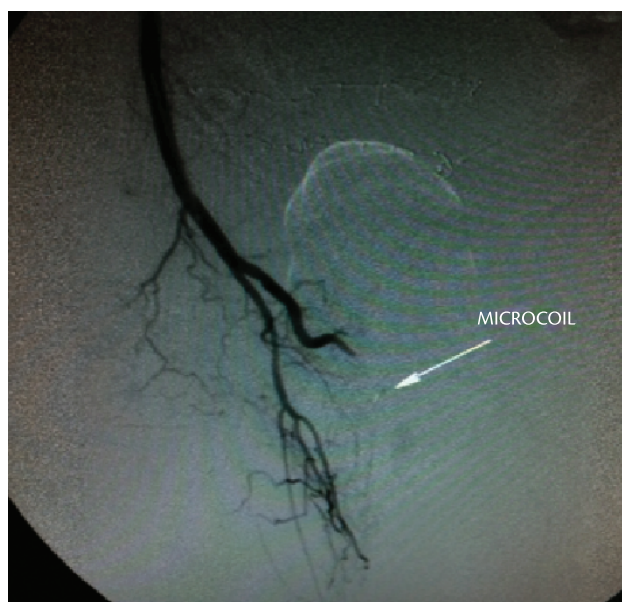


Figure 2. Successful embolization of the fistula with the implantation of controlled-release microcoils.

determining increased input arterial blood flow with normal venous return. It can be self-limited⁷, otherwise therapeutic embolization⁸ may be needed.

In this case report, we presented a rare case of post-traumatic bulbospongious fistula, which evolved to erectile dysfunction and painful maintenance of penile tumescence. The diagnosis was based on arteriography study, since Doppler ultrasound was not able to identify the decreased resistance and the increase of arterial diastolic blood flow, as is characteristic in cases of arteriospongious fistula. We chose to perform embolization using eletrodetachable microcoils by solder electrolysis made of platinum with PGA absorbable multifilament suture due to its greater accuracy and to avoid inadvertent embolization of the bulbar artery origin and promote permanent occlusion.

The only similar description found in literature was a case of traumatic arteriospongious fistula causing erectile dysfunction, described by Glodnyet al.⁹ Endovascular treatment was performed with technical success and return of normal erectile function one week after embolization.

Because it has a multifactorial character, erectile dysfunction should be addressed by a multidisciplinary team, in order to identify risk and etiologic factors of this disorder, and to define the best diagnostic and therapeutic approach for each individual case.

Conclusion

Endovascular approach with embolization of the arteriospongious fistula for treatment of erectile dysfunction showed itself feasible, with low complication rates and good initial results, but it is necessary a greater number of cases and long-term studies to define treatment of choice.

References

- Papatsoris AG, Triantafyllidis A, Gekas A. Prevalence of erectile dysfunction in the European Union. *Asian J Androl.* 2003;5:255. PMID:12937812 .
- Bai Q, Xu QQ, Jiang H, Zhang WL, Wang XH, Zhu JC. Prevalence and risk factors of erectile dysfunction in three cities of China: a community-based study. *Asian J Androl.* 2004;6:343-8. PMID:15546027.
- Wespes E, Wildschutz T, Roumequere T, Schulman CC. The place of surgery for vascular impotence in the third millennium. *J Urol.* 2003;170:1284-6. PMID:14501742.
- Bertolotto M, Quata E, Mucelli FP, Ciampalini S, Forgacs B, Gattuccio I. Color doppler imaging of posttraumatic priapism before and after selective embolization. *Radiographics.* 2003;23:495-503. PMID:12640162.
- Moreira Junior ED, Abdo CHN, Santos DB, Wroclawski E, Fittipaldi JAS. Epidemiologia da disfunção erétil no Brasil: resultados da pesquisa nacional do projeto Avaliar. *Rev Bras Med.* 2004;61:613-9.
- Kendirci M, Nowfar S, Hellstrom WJ. The impact of vascular risk factors on erectile function. *Drugs Today (Barc).* 2005;41:65-74. PMID:15753970.
- Montorsi P, Ravagnani PM, Galli S, et al. Common grounds for erectile dysfunction and coronary artery disease. *Curr Opin Urol.* 2004;14:361-5. PMID:15626880.
- Eland IA, Van Der Lei J, Stricker BH, et al. Incidence of priapism in the general population. *Urology.* 2001;57:970. PMID:11337305.
- Glodny B, Petersen J, Bendix N, et al. Microcoil embolization of an arteriovenous fistula from the arteriobulbi penis to the corpus spongiosum penis in the treatment of erectile dysfunction: normal function regained immediately after intervention. *Br. J. Radiol.* 2007;80:265-7. PMID:17989324.

Correspondence

Fábio Augusto Cypreste Oliveira
Av. Alphaville Flamboyant, 3900, casa 283
CEP 74884-527 – Goiânia (GO), Brazil
Fone: +55 (62) 81475111
E-mail: fabioacoliveira@gmail.com

Authors contributions

Conception and design: FACO
Analysis and interpretation: FACO, CESA e FLC
Data collection: FACO, HWFF, JCB, MCB, FLSM e PMS
Writing the article: FACO, JCB, MCB e FLSM
Critical revision of the article: FACO, CESA e FLC
Final approval of the article*: FACO, CESA, FLC, HWFF, JCB, MCB, FLSM e PMS
Statistical analysis: FACO, CESA e FLC
Overall responsibility: FACO, CESA e FLC

*All authors have read and approved the final version submitted to J Vasc Bras.