

Review of the cases of 15 patients at high risk of obstetric hemorrhage who underwent temporary bilateral occlusion of internal iliac arteries

Revisão de 15 casos submetidos à oclusão temporária bilateral de artéria ilíaca interna em pacientes com alto risco para hemorragia obstétrica

Mariana Krutman¹, Francisco Leonardo Galastri², Breno Boueri Affonso³, Felipe Nasser², Fabiellen Berzoini Travassos², Marcos de Lourenço Messina³, Nelson Wolosker⁴

Abstract

Objective: To analyze the results of 15 cases of patients at high risk of obstetric hemorrhage who underwent prophylactic temporary occlusion of internal iliac arteries. **Methods:** A retrospective analysis was performed of the medical records of 15 patients who underwent prophylactic balloon occlusion of the internal iliac arteries between January 2008 and December 2011. All patients included in the study were diagnosed antenatally with a placental disease associated with a high risk of obstetric hemorrhage. **Results:** The mean age of the patients studied was 36 years (32-42 years). Nine patients had placenta accreta, 4 had placenta previa, 1 had an ectopic pregnancy and 1 had uterine fibroids and coagulopathy associated with systemic lupus erythematosus. The total volume of contrast used in each procedure ranged from 20 to 160 ml (mean 84 ml). The average total number of days in hospital and the average number of days in hospital after the procedure were 12.4 and 4.9 days respectively. In 8 (53%) cases there was no need for blood transfusion during surgery or after surgery. The mean number of units of blood transfused was 2.06. The only complication associated with the procedure was arterial thrombosis of the external iliac artery, observed in 2 cases. **Conclusion:** Temporary occlusion of hypogastric arteries is a safe and effective method for control of bleeding in patients at high risk of obstetric hemorrhage, when performed by experienced staff. The results of this study are observational, retrospective and nonrandomized, therefore we cannot support the routine use of this technique, however, we can include it our arsenal to treat selected cases with potentially unstable hemodynamics.

Keywords: obstetric hemorrhage; interventional radiology.

Resumo

Objetivo: Analisar os resultados de 15 pacientes com elevado risco de sangramento obstétrico, submetidas ao implante de catéteres balão profilático para oclusão temporária das artérias hipogástricas. **Métodos:** Uma análise retrospectiva foi realizada com base em prontuários de 15 pacientes submetidas ao implante de catéteres balão profilático, de janeiro/2008 a dezembro/2011. Todas as pacientes incluídas no estudo foram diagnosticadas no período antenatal com doença placentária associada a alto risco de hemorragia obstétrica. **Resultados:** A média de idade das pacientes estudadas foi de 36 anos (32-42 anos). Nove pacientes eram portadoras de acretismo placentário, quatro possuíam placenta prévia, uma estava com gestação ectópica e uma apresentava miomatose uterina e coagulopatia associada a Lupus Eritematoso Sistêmico. O volume total de contraste utilizado para o procedimento variou entre 20 e 160 ml (média de 84 ml). A média do número total de dias de internação e o número de dias de internação após o procedimento foram, respectivamente, 12,4 e 4,9 dias. Em oito (53%) casos, não houve necessidade de transfusão sanguínea no intraoperatório ou após a cirurgia. A média do número de unidades de sangue transfundida foi 2,06. A única complicação associada ao procedimento foi a trombose arterial de artéria ilíaca externa, observada em dois casos. **Conclusão:** A oclusão temporária de artérias hipogástricas é um método seguro e efetivo para controle de hemorragia em pacientes com elevado risco de sangramento obstétrico, quando realizado por equipe experiente. Os resultados deste estudo são observacionais, retrospectivos e não randomizados; portanto, não podemos apoiar o uso rotineiro dessa técnica, mas podemos incluí-la no arsenal de recursos para casos selecionados com potencial para sangramento.

Palavras-chave: hemorragia obstétrica; radiologia intervencionista.

¹Hospital Israelita Albert Einstein, São Paulo, SP, Brazil.

²Hospital Israelita Albert Einstein, Interventional Radiology Service, São Paulo, SP, Brazil.

³Universidade de São Paulo – USP, School of Medicine, Department of Obstetrics and Gynecology, São Paulo, SP, Brazil.

⁴Hospital Israelita Albert Einstein, Department of Vascular Surgery, São Paulo, SP, Brazil.

Financial support: None.

Conflicts of interest: No conflicts of interest declared concerning the publication of this article.

Submitted on: 05.25.13. Accepted on: 06.25.13.

■ INTRODUCTION

Obstetric hemorrhage is the number one cause of maternal mortality in the world¹. It can occur as the result of a range of different maternal and fetal conditions, including placental abnormalities such as placenta accreta, uterine atony and ectopic pregnancy. In view of the high rates of morbidity and mortality linked with this obstetric complication, attempts have been made to find minimally invasive prophylactic techniques designed to reduce intraoperative bleeding^{2,3}.

The technique currently available consists of temporary bilateral occlusion of the internal iliac arteries, using angioplasty balloons⁴. The procedure is performed immediately before caesarean and may or may not be combined with transcatheter embolization⁵⁻⁷.

There are no randomized controlled studies validating routine use of the method, primarily because of the rarity of the conditions such as placenta accreta that prompt its use^{8,9}. Studies have shown that the technique offers the benefit of reduced overall maternal morbidity and may also reduce costs^{4,6,10}.

The objective of our study was to analyze the results of 15 patients who were fitted with prophylactic balloon catheters to temporarily occlude the hypogastric arteries. This paper presents an analysis of technical aspects and an evaluation of the technique's impact on length of hospital stay and blood transfusion requirements.

■ PATIENTS AND METHODS

A retrospective analysis was conducted of medical records for 15 patients who underwent insertion of prophylactic balloon catheters between January of 2008 and December of 2011. The study was approved by the Ethics Committee at the Hospital Israelita Albert Einstein.

Despite the retrospective study design, data losses were minimal because all cases were well-documented and had followed the Interventional Radiology Department's standard protocol. All of the patients enrolled on the study had been diagnosed with placental diseases by antenatal imaging exams (Doppler ultrasound or magnetic resonance imaging). The inclusion criteria were based on the potential for perinatal hemorrhaging, in the judgment of the obstetric team, and therefore included placental diseases such as placenta accreta and placenta previa and also ectopic pregnancy and maternal coagulopathy, but did not include patients who had the technique performed because of risk

of gynecological hemorrhage (i.e. not obstetric hemorrhages), who were excluded from the study.

In all cases, operations were performed in the hemodynamics room, with the aid of an anesthetic team who administered epidural anesthesia. The technique employed requires bilateral puncture of the common femoral artery, followed by insertion of 5 or 6 FR short sheaths. Heparin is administered locally via the sheath using a solution comprising 5,000 UI of Heparin in 100 mL of saline solution and then the contralateral internal iliac artery is selectively catheterized using a 0.035 hydrophilic guide wire and a Cobra II catheter.

The diameter of the internal iliac artery is measured using a quantitative analysis feature built into the hemodynamic machine. Semi-complacent angioplasty balloons (7 × 20 Passeo 35-Biotronik) are then positioned at the origins of the internal iliac arteries using angiography for guidance. Correct balloon positioning is checked on a control angiograph, taken after injection of 2 ml of contrast via the balloon, and then a final image is taken, as shown in Figure 1. The balloons are not inflated at this point and the catheters are taped to the skin to

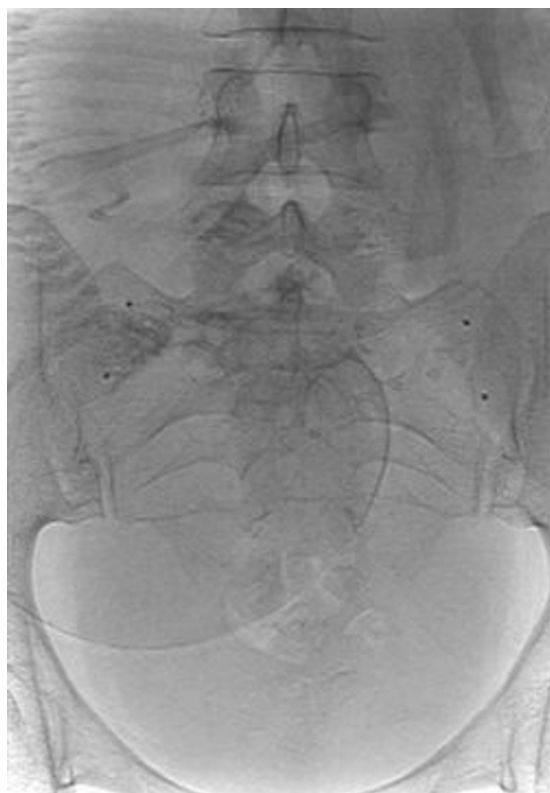

Figure 1. Final radioscopic control image demonstrating balloon position.

avoid displacement. The patient is then transported to the operating theatre. During the operation and after the fetus has been removed, the balloons will be inflated intermittently, at the surgeon's request. The sheaths are connected to a pressurized system providing continuous irrigation with saline throughout the procedure.

The results for the 15 patients selected were analyzed in terms of technical data on the procedure (volume of contrast employed, and length of time the balloons were left in the internal iliac arteries), and in terms of blood transfusions needed, length of hospital stay and complications related to the procedure.

Cesareans and 20% were emergency interventions. The sheaths remained in femoral arteries for 125 to 400 minutes (mean = 236.1 minutes). Total contrast volume used during each operation varied from 20 to 160 ml (mean = 84 ml).

Figure 2 illustrates the progress made in terms of reducing contrast volumes and time balloons were left in place, as the operating team developed and mastered the technique.

The mean total number of days in hospital was 12.4 and the mean number of days in hospital after the operation was 4.9. In eight cases (53%) there was no

■ RESULTS

Table 1 provides data on the 15 patients selected for our study. Both mean and median age were 36 (varying from 32 to 42 years). Nine of the 15 (60%) patients had been diagnosed with placenta accreta antenatally on the basis of magnetic resonance or Doppler ultrasound findings, but only six of these women underwent hysterectomies.

The remaining cases were four patients with placenta previa, one ectopic pregnancy and one uterine myomatosis in a patient with coagulopathy linked to systemic lupus erythematosus.

With relation to the technical details of the procedures, 80% of cases were elective, planned

Progression in length of balloon stay and volume of contrast

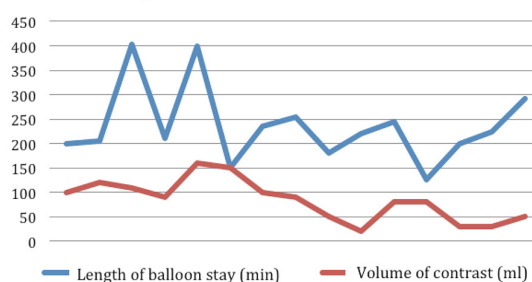


Figure 2. Change in volume of contrast used and time balloons left in place as the team mastered the technique.

Table 1. Profile of the sample and data analyzed.

Patient	Age (years)	Antenatal Diagnosis	Length of time balloon in place (minutes)	Volume of contrast employed (ml)	Units of blood transfused	Total no. days in hospital / No. days after operation	Hysterectomy	Anatomic/ pathological confirmation of diagnosis	Complication
1	40	PA	200	100	0	5 / 4	Yes	Yes-Increta	No
2	42	PA + PP	205	120	3	5 / 4	No	-	No
3	37	PA + PP + PIH	403	110	4	22 / 11	Yes	Yes-Increta	Yes*
4	36	AMN + MM + IGR + SLE	210	90	0	78 / 6	No	No	No
5	35	PA	400	160	11	19 / 9	Yes	Yes-Percreta	Yes**
6	32	PAB + PA	150	150	4	4 / 4	Yes	Yes-Increta	No
7	36	EP	235	100	6	6 / 5	Yes	Yes	No
8	35	PA	254	90	0	5 / 4	Yes	Yes	No
9	34	PP	180	50	0	5 / 4	No	-	No
10	37	PA	220	20	0	4 / 3	No	-	No
11	40	PP	244	80	0	4 / 4	Yes	Myomatosis	No
12	34	PA	125	80	1	5 / 4	No	-	No
13	35	PP	200	30	0	4 / 4	No	-	No
14	35	PP	224	30	0	23 / 3	No	-	No
15	39	PA + PP + SAF	292	50	2	5 / 4	Yes	Yes-Increta	No

Abbreviations for Table 1: PA – Placenta Accreta; PP – Placenta Previa; PIH – Pregnancy-Induced Hypertension; IGR – Intrauterine Growth Restriction; AMN – Amniorrhexis; MM – Myoma; SLE – Systemic lupus erythematosus; PAB – Placental abruption; EP – Ectopic Pregnancy. *Unilateral thrombosis of external iliac, controlled by embolectomy and passage of a Fogarty catheter. **Patient suffered severe hypotension during the Cesarean, leading to occlusion of one external iliac, which was promptly dealt with by embolectomy and passage of a Fogarty catheter.

need for intraoperative or postoperative transfusions. The mean number of units of blood transfused was 2.06 and each packed red blood cell bag has a volume of 300 to 350 ml.

The only complication associated with the procedure was arterial thrombosis of the external iliac artery, observed in two cases because of the extended length of time the sheaths were left in place (more than six and a half hours). Both cases were promptly dealt with by embolectomy and passage of a Fogarty catheter, with no sequelae to the patients involved.

DISCUSSION

Recent data indicate that the incidence of placental abnormalities is increasing, primarily as a result of the increase in the number of Cesareans performed worldwide^{11,12}. This has increased the incentive to develop effective, minimally invasive techniques to reduce the morbidity caused by these conditions.

Gynecologists and obstetricians have adopted with great enthusiasm endovascular techniques as important tools to aid in control of intraoperative hemorrhages. In the past, indications for this method were limited to severe cases of accreta and it was used to reduce maternal mortality due to obstetric hemorrhages. The technique is now more widely available and its safety, combined with increasing mastery of the method, means that it is now indicated for a wider range of situations, including those in which hysterectomy is not mandatory and the primary objective is to preserve the uterus.

The percutaneous technique that is currently available for control of hemorrhaging consists of temporary occlusion of the hypogastric arteries, combined or not with uterine embolization. Previous case series that have been published indicate that the combined procedure is preferable, because it means treatment is more likely to be effective³. Our experience has borne out prior reports⁴ suggesting that prophylactic occlusion of the internal iliac arteries can alone be effective for controlling massive blood loss, while offering the advantages of reduced radiation exposure and a lower risk of ischemia of the uterus or other pelvic organs.

Bouvier et al.¹³ reported on a series of 14 patients with placenta accreta who underwent perioperative embolization of the uterine artery, demonstrating that in eight cases (57.1%) it was possible to avoid hysterectomy. Our inclusion criteria were different but, nevertheless, our rate of uterus preservation was slightly inferior (46.7%) to the rate reported by Bouvier et al. However, we did not observe any cases

of uterine necrosis with sepsis, which was described in that paper and demanded later hysterectomy.

Other case series have demonstrated that temporary occlusion of the aorta can be effective for controlling bleeding in patients with placental abnormalities¹⁴, but that technique involves a greater potential for complications, since there is a higher risk of reperfusion syndrome and local complications because of the need to insert larger caliber sheaths. When the patient spends a prolonged period in theatre, as was the case with some of our patients, a balloon in the aorta is not only a risk for ischemia of the leg, but can also cause even more catastrophic events, such as bone marrow ischemia leading to paraplegia.

In order for this procedure to be performed successfully, the physical infrastructure needed is a hemodynamics suite and a high-quality X-ray machine, while the human resources required comprise a multidisciplinary team made up of doctors (radiologists/vascular surgeons /obstetricians/urologists) and trained nurses. If any of these prerequisites are missing, the technique's positive results may be compromised and some authors suggest that the technique should be avoided in such circumstances^{7,15}.

As illustrated in Figure 2, and in common with observations reported in other studies¹⁶, in this series of patients we observed a progressive tendency for the volume of contrast used to reduce and for the length of time the balloon was left in place during each procedure to shorten, reflecting the operating team's learning curve and their process of familiarization with the method.

Complications that have been reported as associated with this method are all caused by inadequate endovascular materials and vascular access and include the following: pseudoaneurysms, hematoma, arterial thrombosis and rupture of hypogastric arteries by balloons¹³. In our patient sample it was clear that the complications observed were caused by the extended length of time in surgery. The intrinsic hypercoagulability state that is observed at the end of pregnancy also contributes to the formation of thrombi in these cases, which may or may not be linked to systemic administration of heparin. Continuous irrigation of the sheath with saline solution throughout the entire procedure also helps to reduce thrombotic complications.

Conclusions: temporary occlusion of the hypogastric arteries is a viable alternative for control of bleeding in patients at high risk of obstetric hemorrhage, if performed by an experienced team.

The results of these studies are observational, retrospective and non-randomized and as such they cannot serve as the basis for a recommendation that this technique become routine, but we can add it to our arsenal for use in specific cases in which there is a potential for hemorrhage.

■ REFERENCES

- Berg CJ, Atrash HK, Koonin LM, et al. Pregnancy related mortality in the United States. *Obstet Gynecol.* 1996;88:161-167. [http://dx.doi.org/10.1016/0029-7844\(96\)00135-4](http://dx.doi.org/10.1016/0029-7844(96)00135-4)
- Angstmann T, Gard D, Harrington T, et al. Surgical management of placenta accreta: a cohort series and suggested approach. *Obstet Gynecol.* 2010;202(1):38-1-9.
- Bodner LJ, Noshier JL, Gribbin C, et al. Balloon-assisted occlusion of the internal iliac arteries in patients with placenta accreta/percreta. *Cardiovasc Intervent Radiol.* 2006;29(3):354-61. PMID:16502171. <http://dx.doi.org/10.1007/s00270-005-0023-2>
- Carnevale FC, Kondo MM, De Oliveira Sousa W Jr, et al. Perioperative temporary occlusion of the internal iliac arteries as prophylaxis in cesarean section at risk of hemorrhage in placenta accreta. *Cardiovasc Intervent Radiol.* 2011;34(4):758-64. PMID:21598085. <http://dx.doi.org/10.1007/s00270-011-0166-2>
- Salazar GM, Petrozza JC, Walker CG, et al. Transcatheter endovascular techniques for management of obstetrical and gynecologic emergencies. *Tech Vasc Interv Radiol.* 2009;12(2):139-47. PMID:19853231. <http://dx.doi.org/10.1053/j.tvir.2009.08.007>
- Ojala K, Perälä J, Kariniemi J, et al. Arterial embolization and prophylactic catheterization for the treatment for severe obstetric hemorrhage. *Acta Obstet Gynecol Scand.* 2005;84(11):1075-80. PMID:16232175.
- Greenberg JI, Suliman A, Iranpour P, et al. Prophylactic balloon occlusion of the internal iliac arteries to treat abnormal placentation: a cautionary case. *Am J Obstet Gynecol.* 2007;197(5):470:1-4.
- Levine AB, Kuhlman K, Bonn J, et al. Placenta accreta: comparison of cases managed with and without pelvic artery balloon catheters. *J Matern Fetal Med.* 1999; 8(4):173-6. [http://dx.doi.org/10.1002/\(SICI\)1520-6661\(199907/08\)8:4<173::AID-MFM7>3.0.CO;2-V](http://dx.doi.org/10.1002/(SICI)1520-6661(199907/08)8:4<173::AID-MFM7>3.0.CO;2-V)
- Thon S, McLintic A, Wagner Y, et al. Prophylactic endovascular placement of internal iliac occlusion balloon catheters in parturients with placenta accreta: a retrospective case series. *Int J Anesth.* 2011;20(1):64-70. PMID:21112764. <http://dx.doi.org/10.1016/j.ijoa.2010.08.006>
- Mok M, Heidmann B, Dundas K, et al. Interventional radiology in women with suspected placenta accreta undergoing caesarean section. *Int J Obstet Anesth.* 2008;17(3):255-61. PMID:18513942. <http://dx.doi.org/10.1016/j.ijoa.2007.11.010>
- Gilliam M, Rosenberg D, Davis F, et al. The likelihood of placenta praevia with greater number of caesarean deliveries and higher parity. *Obstet Gynecol.* 2002;99:976-80. [http://dx.doi.org/10.1016/S0029-7844\(02\)02002-1](http://dx.doi.org/10.1016/S0029-7844(02)02002-1)
- Wu S, Kocherginsky M, Hibbard JU. Abnormal placentation: twenty-year analysis. *Am J Obstet Gynecol.* 2005;192:1458-61. PMID:15902137. <http://dx.doi.org/10.1016/j.ajog.2004.12.074>
- Bouvier A, Senthilhes L, Thouveny F, et al. Planned Caesarean in the interventional radiology cath lab to enable immediate uterine artery embolization for the conservative treatment of placenta accreta. *Clin Radiol.* 2012;67:1089-1094. PMID:22622352. <http://dx.doi.org/10.1016/j.crad.2012.04.001>
- Panici PB, Aneschi M, Borgia ML. Intraoperative aorta balloon occlusion: fertility preservation in patients with placenta previa accreta/increta. *J Matern Fetal Neonatal Med.* 2012;25(12):2512-6. PMID:22992070. <http://dx.doi.org/10.3109/14767058.2012.712566>
- Bishop S, Butler K, Monaghan S. Multiple complications following the use of prophylactic internal iliac artery balloon catheterisation in a patient with placenta percreta. *Int J Obstet Anesth.* 2011;20(1):70-3. PMID:21168325. <http://dx.doi.org/10.1016/j.ijoa.2010.09.012>
- Puech-Leão P, Wolosker N, Zerati AE, Nascimento LD. Impact of endovascular technique in vascular surgery training at a large university hospital in Brazil. *J Surg Educ.* 2011 Jan-Feb;68(1):19-23. PMID:21292210. <http://dx.doi.org/10.1016/j.jsurg.2010.08.002>

Correspondence

Mariana Krutman
Av. Albert Einstein, 627, Bloco A1, sala 423 - Morumbi
CEP 05652-900 - São Paulo (SP), Brasil
E-mail: mari.krutman@ig.com.br

Author information

MK is vascular and endovascular surgeon, Hospital Israelita Albert Einstein.
FLG and BBA are associate physicians, Interventional Radiology Service, Hospital Israelita Albert Einstein.
FN is chief, Interventional Radiology Service, Hospital Israelita Albert Einstein.
FBT is trainee, Interventional Radiology Service, Hospital Israelita Albert Einstein.
MLM is assistant physician, Department of Obstetrics and Gynecology, School of Medicine, Universidade de São Paulo (USP).
NW is vascular and endovascular surgeon, Hospital Israelita Albert Einstein.

Author's contributions

Conception and design: MK, NW, FN, BBA
Analysis and interpretation: MK, FLG, FN, MLM
Data collection: MK, FLG, FN, MLM
Writing the article: MK, FBT
Critical revision of the article: NW, FN, BBA
Final approval of the article*: NW, FN, BBA, MK, MLM, FLG, FBT
Statistical analysis: MK
Overall responsibility: MK, NW, FN
Obtained funding: None.

*All authors should have read and approved of the final version of the article submitted to *J Vasc Bras.*